

Multi-Disciplinary Scientific Approach to Detection of Mass Repeated Fatal Errors in Standard Medical Orthopedic Processes



Antonín Cuc*

Expert in Cybernetics, Occupational Health and Safety including Medical Devices, Czech Republic

Submission: April 12, 2018; **Published:** May 01, 2018

***Corresponding author:** Antonín Cuc, Expert in Cybernetics, Occupational Health and Safety including Medical Devices, Prague, Czech Republic,

Email: betrucea@gmail.com

Annotation

The frequency of fatal medical errors in Diagnosis and choosing the right individual treatment is tragic fatal by 10% of all workflow – today's exwaiting fatal medical mistakes in OECD by The World Research Message WHO 2010. This means an immense amount of unnecessarily severely injured patients annually, with a substantial reduction in the rest of their lives for many years in all OECD countries. I very much appreciate the findings of medicine in the US, where it has been proven in 2016 that medical errors are actually the third most common cause of in forced Patient death in the US, although it is very difficult to demonstrate from standard structural patient medical records. I have therefore decided, on the basis of the standard criminalistic multidisciplinary methods used in the United States to analyze catastrophic falls of each transport aircraft, it was my origin inspiration: - to demonstrate how similar criminal analyzes of statistical Patient samples can be performed a key to description random clusters of patients with comparable orthopedic diagnosis with comparable standard choice treatment with a comparable choice of orthopedic implants with detection many false similar repeated fatal medical mistakes.

The basis of the demonstrative approach is the problem of a model description of the history of at least One Statistical Unit - the elementary first case of at least one patient in the selected first learning sample. We are begin with FIRST more explanatory case description of the Orthopedic case in next Clusters - with this new patented approach, Utility model S_T_A_R_S – Statistical Retrieval and Search of sufficient information to Mass reuse for similar repeated strategic decision making, it opens a crucial World discussion among all the members of the evaluating multidisciplinary scientific next working team - ie, criminologists, orthopedists, radiologists, forensic doctors, patients, lawyers, statistics, biostatistics, experts in databases for the Clusters from clever selected records from used EHRs.

Experienced and well structured motivated qualified decision team by patented principles Utility model S_T_A_R_S,

21532 CZ, 2010. The problem of proper collective decision making in a team that uses multidisciplinary scientific approaches should be based on the reasonable professional and well motivated staffing of the entire team, but they must go through a common initial run-in to make clear what decisive phenomena they must be able to recognize to evaluate and how to learn from the individual evaluations of the individual team members to come to the joint partial conclusions and to the final interpreting statistic representative conclusions, estimates of statistic parameters with statistic accuracy and statistic defined reliabilities - on the individual monitored phenomena, on the critical illegal situations of the patient Health care, the individual statistical units evaluated i.e. when checking the correct processing in diagnosis, checking the correct processing in choice the right individual treatment by the modern medical knowledge's interdisciplinary of Encyclopaedic Literature , assessing the illegal consequences of medical errors in diagnosis and in the choice of false individual treatment, evaluating the consequences of fatal unlawful medical errors by the decisions making on the Providers Health care and medical staff by the Health care for patient, the probable development of his / her status of Health, the growth of fatal patient risks in next time and a biostatic probable enumerable effects on the likely median estimate of shortening the rest of the patient's life for a significant number of years to legal financial satisfactions including the Life assurance for worse mental and Physical Health status, Loss of Patient Lives. We should to understand to the casual history of a few individual Patient tragic growing the fatum to begin with next clever usage the Statistic method to detect similar medical mistakes EX POST, later so as for prevency to repeat medical mistakes EX ANTE.

In Orthopaedy CZ, you never could take Members in Decision Research Team CZ , because all Orthopaedic Patients CZ there are living OR there are heavy injuring OR there are dying only unconditionally LEGE ARTIS CZ, by the constant false meaning of all Providers Health care CZ and medical staff CZ, by the constant

false meaning all Knowing Medical Institutes CZ, by the constant false meaning of Criminal Departments of Police CZ, by the constant false meaning of the all Justice CZ, by the meaning of the Heads of all Penalty Offices CZ – The Patient could be a silent Victim CZ only, without the Human Rights for Life and justified truth verified Criminal evidences by the justified Court trials.

We are living live in the legal State of Czech Republic, where all unnecessarily mutilated or dying orthopedic patients of CZ have no real civil human rights to use forensic technical evidences by Court trials CZ - that they have been silent needless Victims CZ of The Mass repeated illegal fatal medical procedures in orthopaedic Diagnostics or Treatments – for example contrary Technician Requirements of implanting Laws EU/CZ for guaranty the legal usage Medical Implants with CE marking by the Technician Requirements of the Directive 93/42/EEC Medical Devices in common Market EU/CZ since April 1, 2004.

Since there are never seen any fatal official medical errors in Czech Orthopedics CZ, it is not real possible or desirable to detect or efficiency to prevent such massive medical orthopaedic errors in medical orthopaedic workflow, namely we don't solve tragic Fatusms of Patient CZ in the Czech Republic, we don't count the yearly needless Patient Victims CZ. We are taking the false definition LEGE ARTIS CZ regardless It has covered namely in Mass frequent repeated trivial technical medical fatal errors in Mass Medical processing CZ. The needless Loss of Orthopedic Patient Life CZ has NONE of financial evaluating. Provider's Health care CZ and medical staff are absolute Scot – free for ever – in the secret continual civic war the Physicians CZ contrary Patients CZ with Mass yearly repeated similar Mass Medical errors in the standard medical orthopaedic processing. In this my explanatory Article, I am deciding solitaire scientist - ONE MAN CZ ONLY - because the scientic Truth is interesting for US Medicine only, never for CZ Medicine.

Namely I am explaining the next Explanatory Orthopaedic Case about false Diagnostics and with false choice the Treatments Necroses of femoral Head both my legs - as an pensioner The State investigator of mortal occupational cases of Ministry for Labour and Social Affairs Czech Republic, so as a needless crippled too and just dying orthopaedic Patient LEGE ARTIS CZ too - after to late diagnostics Necroses of Femoral Head with the false choice 3 needless following Treatments of illegal Orthopaedic surgeries THA when there were recommended advanced more carefully and safety recommended NON-surgical treatments in time - by the World Encyclopaedic Orthopaedic Literature.

I have unofficial studied the contextual sufficient details of Human Orthopaedic in Necrosis of Femoral Head, Traumatology functional collapsing of human joints, principles of non-surgical treatments of Necroses femoral Head, The recommended classic arthroplastic light Surgeries to repair Human joints, comparing preferences Method Magnetic resonance and limits in RTG imaging in Diagnostics of necrosis in Hip joints, Clinic mandatory Planning of standard individual Implanting Total Hip

Arthroplasty, usual patient risks of Full Anaesthesia, Neurologic transplantation and right timing of neurosurgical reconstruction the Nerves Ischiadici by full plegia in Traumatology cases, the typical complications Surgeries by Patient over Age 65+ by THA, Infects dangerous in Surgery Halls, Infect risks in post operational orthopaedic implanting, Typical dangerous Hemorrhagic preliminary Infects of Orthopaedic Patients, typical preoperational and post operational risks and Health complication by set THA with no cemented principles the Hip Artificial joints, rational post operational transfusions of Blood, prescriptions of Medicaments with risk of chemical mutual interactions, Posttraumatic Shocks on surgeon Halls, typical fatal mistakes of interpretation in Geometry 3 D in Orthopaedic Radiology by THA, Biomechanics and Designing functional sets THA by Producer Tests, Biostatistics analyses THA patient by returning locomotion abilities with modelling optimal possibilities by computer support of modelling, harmonised Laws EU/CZ in fields the Occupational Health and Safety, harmonised European Standards for the parallel usage of rules the Directive Machinery, Directive 93/42/EEC Medical Devices – Research, Development, finished Testing new product sets THA, Regulation the Usage and State surveillance of usage Orthopaedic Implants THA in common Market EU by Providers Health care, functional collapsing Implants, repairing. Rehabilitation support, Physiatic supporting praxes for post operational locomotion abilities of Patient after THA, Statistic Growing Risks of repeated proximal fatal breaking of Femoral bones after repeated THA surgeries happened fallen.

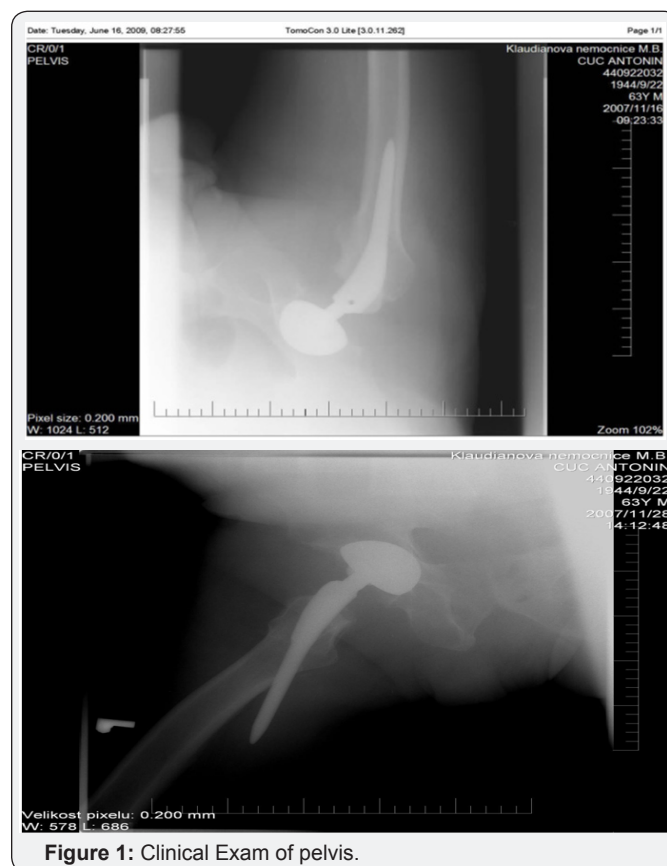


Figure 1: Clinical Exam of pelvis.

The Duration of safety product lives in sets THA in long being safety patient usage for probable more as 20 years, Carcinoma risks by metallic and micro invasive PVC materials surfaces in frontiers the components of the Artificial joints with surface of cavities of femoral bones, pelvis hip sockets (Figure 1) destructions of the functional Technician Quality of mechanical Anchoring of centric placements of components THA in hip bones, Catastrophic preoperational situations Ad hoc on the Surgeon Halls by implanting THA. Yes, I am just simulating personally in this Article - the perfect educated, structured and working decision making Team of experts for usage orthopaedic sampling in Criminal analyses in the primary Dimense: The Statistic Unique entity - with explanation the decision making by my Method S_T_A_R_S, by The Utility model 21532 CZ 2010.

As I Unnecessarily Lost my Left Hip in Dg. the Femoral Head Necrosis

At the beginning of 2004, I was 59 years old, I was poorly trained with a new Surface Sleigh sweep in the snow - I dropped from the height of my buttock where there was a big blood swelling about 7 centimetres in diameter. The pains did not lose even after a few months, it had only solid edges. After a few months, my left hip began to collapse, sometimes I was completely eliminated for a few minutes from locomotion, then it managed to overcome the light massage and another attack of pain inside my hip was repeated until the next day. As an inquisitive patient, I lectured at the Prague Municipal Library to study the Orthopedic Medical Encyclopaedia, where I personally suspected that it might be Necrosis of the left femoral head, according to the typical symptoms of the patient's troubles. So I went to the ambulance of my practical Mrs. M Dr Physician and I asked her to provide me with a request for X-ray examination of the hip at the Orthopedic Clinic of the Faculty Hospital Královské Vinohrady in Prague 10. The X-ray analyst carefully listened to me and looked at the X-ray image from the beginning of September 2004, there are no obvious destructive changes on the X-ray of the hip, but that does not mean that my patient's situation is very serious. She did not ask me to bring a new order for the Distant Magnetic Resonance to detect the initial phase of Femoral Necrosis, but she sent me for further examination at the Neurology Clinic of the same hospital.

The Prime Dr. of Neurology, me igned carefully scratched the hip and skeletal functions, but he did not send me again to the desired differential diagnosis of femoral head necrosis using MRI-because he was mistakenly assumed-that it was the cause of spinal nerve ending - with casual both - hip and back pains. Procedure Neurology was not expertly wrong but ignored my initial suspicion about of Necrosis of left femoral head. The neurologist has decided Treatment - that the painful state should bridle local anaesthesia with a syringe inserted directly at the end of the spine - in the hope that painful inflammation in the spine, as well as the left hips will calm down and the hip joint will

functionally revitalize again. The origin premise of neurologist was wrong for always worse Patient Health status in duration of 4 weeks.

There was a clear mistake that Neurolog kept on his primary hypothesis about Diagnosis, but my patient hypothesis did not at least do the additional differential diagnosis with MRI, my patient council did not take seriously. It is for these reasons that during the tragic 4 weeks the surface sliding surface of the hip joint was completely destroyed. On the next X-ray image at the beginning of November 2004, the revitalization of the joint function was completely impossible without at least a shorter surgical orthopedic procedure. According to the Orthopedic Encyclopaedia, the first stages of the development of necrosis of the femoral head are easily naturally revitalized - only the basic limitations of locomotion with bedtime and the use of revitalizing dietary and medical supplements, with hip autosomes and controlling effects by MRI after 5 weeks.

In my private case of orthopedic and already significant damage of the hip joint, the application of Total endoprosthesis is possible only in the highest stage of the 5th stage, but the Orthopedic Clinic of the Faculty Hospital Královské Vinohrady, Prague 10 CZ, offered me the term of Surgeon THA till in May 2005, when I could not walk from the place. That made me looks for a next Orthopedic Promotion at the Regional Hospital Mladá Boleslav where I was implanted with an artificial joint Bicontact S, no cemented, already on January 4, 2005. The operation of the hip TEP was performed properly and functionally, but unnecessarily about 5 years earlier before it was for me Patient-friendly - because none of the Orthopaedists, Radiologists and Healers - could not use the recommended advanced diagnostic and therapeutic procedures for the diagnosis of femoral head necrosis by Orthopedic Encyclopaedia - nor on the scale and knowledge's of a typical orthopedic educated patient with a right defined probable Dg. According to a sample of about random choice about 50 cases Patient Cluster with the femoral Head with Necrosis in a like hood Orthopaedic Clinic... it can be seen with statistic evidence today's trends: - that Orthopaedic Clinics, Orthopaedists and Radiologists always prefer large surgical orthopaedic procedures - on which the Orthopedic Clinic and Hospitals can sneeze, including doctors, while the interests and preference of the orthopedic patients are else - after the perfect lifestyle till ages 90+, with locomotive and personal mental high private safety conditions - always with consistently preventy and eliminating the needless Patient risks, eliminate needless use of local and general anaesthesia by preliminary THA including, in no case there are a independent supervisions of the Health Assurances, or the Providers of health services in orthopaedics in hospital nets Oecd - Best Reliable Deciding And Sharing Best Medical Experiences In Principles Based Evidenced Medicine NOT WARRANT! The Profits of Providers Health care are priorities.

How I lost my right hip joint, how could I get crippled and why I'm dying

After about 8 months in August 2005, I began to experience similar problems with necrosis of the femoral head even on the right hip. My Orthoped MU Dr. František Vurm, who has already operated the left hip – He recommended only hip pain pills to limit, which did not solve the essence of the orthopedic principal problem. His fundamental view was - to passively wait until the advanced necrosis of the femur destroys the right hip joint too - and then, finally to use the THA again. He did not think of any more moderate rescue carefully procedures for my hip - I suppose, probably because he did not use any nonsurgical healing processes or mild curative surgical arthroplastic processes. Of course he did not manage them practically with skills - and perhaps He never read anything about them from the last Czech Orthopaedic Encyclopaedia since 2005. The orthopedic encyclopaedia literally describes full List of orthopedic diagnoses and full variants of treatment methods - which the unique orthopedic routine does not manage with skills and therefore cannot recommend to its patients for else orthopedic concurrency in medical Branches.

If you want to make a good next profit by next hip Total Hip Arthroplasty. No professional critic from the position of his experienced colleagues - the Orthopaedists, does not expect it. Especially in the elderly, it is often with much more advantageous to replicate about number about 200 TEP hip annually from the point of view of the older Orthopaedist to older Patient in the region - rather than trying to risk the easier and cheaper light surgeon repairing of the hip joint for the individual Patient – maybe which he saw similar extraordinary problems twice times about 20 years ago - when he was studying Orthopaedics' firstly. All Orthopaedist are keeping mostly trendy – to more frequent the large surgeon standard HIP with Total Arthroplasty, despite there are for Patients frequently growing risks from full Anaesthesia, worse rehabilitation, more risks on the Surgeon hall, etc. The fatal legal, technical, medical mistakes of my Orthopaedic MUDr. František Vurm – it was ignorance my preliminary declination the femoral neck on the right femoral bone, which was diagnosed by the Radiolog from the Central Medical Radiology Clinic of the Faculty Hospital Královské Vinohrady Praha 10 – about 3 weeks before Surgery THA – it means before date November 13, 2007 in the Regional Hospital Mladá Boleslav with explicit results by written too!

By the Directive 93/42/EEC Medical Devices, there are technical requirements including mandatory duties to create Individual Clinic Processing Plan of Surgery THA, because the individual qualities of the Forms, Positional placement and the individual structure of hip bones – there are limiting Input mandatory information about Patient Health Status including, we should probe the useable fitted placement of the choice components set THA on the preliminary RTG Hip images with mandatory comparison with the firm radiologic etalons of

components in Geometry 3 D on the Orthopaedic screen, with the same scaling...there are mandatory specific planning processing by the Dysplastic Declination of femoral neck... because the separation of dysfunctional forms the natural Head of joint....must be with individual surgeon cat, there must be regards to rasping the specific socket on the proximal femoral cavity...for planning the placement of the stem...Only idiot or Murder...could be able to begin the illegal Surgeon Work THA on the Surgeon Hall bendy! Only Group of Murders with graduating as Orthopaedist MU Drs, could say...it is working Lege artis CZ, including when the MU Dr. František Vurm wasn't able to detect the false rasped the proximal femoral socket with false hole - with Illegal destruction integrity of my femoral bone ...despite he should be mandatory controlling by the Product in void with specific Orthopaedic instrument full integrity by details in Certification of Users THA Bocntact S No cemented, but he didn't diagnosed tragic hole in the femoral socket. When MU Dr. František Vurm illegal finished the assembling the set THA – Bicontact S, No cemented, Dimension 13 mm, Typ N from the B. Braun Germany...out of mandatory accuracy in coaxialities the femoral bone and ther Stem....out of tolerance +/- 1 grads...when he placed the stem illegally crumm ...with declination in the sagittal Direction (the same Plaine and declination of the axes of the Stem on 13,68 grads - Direction as the Imaging RTG since the November 16, 2007).

Only Idiots or Murders could say It is no to detect - illegal declination on the RTG since the date November 16, 2007. We should observe the post operational Image not illegally in the hand and with intuitive views! We should take always the Firm installing radiological masks and on the Orthopaedic screen, we should comparing the placement on the Image with this radiologic firm etalons....and when the spice of the used stem in the coordinates Xi, Yi, Zi we were controlling...by the Preliminary Planning...but there are in the FALSE DEPTH! The spice it is about 5,8 millimetres in femoral axes virtually shorten axes of the Stem – Only idiots or my Murders, could say again by Court dealing....it was LEGE ARTIS CZ! No, there are by the goniometric Algorithm to evidence the same declination 13.68 Grads definitely, as we could see the same declination on the next post operational RTG Image since the date November 28, 2007 before Reoperation THA! It was Crash FAUSSE ROUTE STEM of the false illegal assembling product CE, there were no functional mandatory abilities by official testing of implanted product CE on the surgery hall since date November 13, 2007!

Only idiots or my Murders could say again....You are probable crippled by the post operational patient happened fallen, all medical orthopaedic workflow were realised LEGE ARTIS CZ, by the meaning medical staff and so as by The Knowing Medical Institute – it is FALSUM and the Complot against the Patient, it was accepted by the Judge!

There are absolutely excluded to substitute the real Phenomenon's and Biomechanics, Geometry, Radiologic

evidences from Tragic Crash FAUSSE ROUTE in the surgeon Hall since date November 13, 2007 – see the next 2 post operational RTG Images and the False Medical Hypothese from the Court Medical Message from the date March 27, 2012 from the Knowing Medical Institute – The Central Army Hospital Prague CZ Post operational patient Fallen with perfect Lege Artis CZ the Provider Health Care – the Regional Hospital Mladá Boleslav with medical staff – Orthopaedist MU Dr. František Vurm, prime MU Dr. Pavel Šedivý. The False Medical Court Message was signed by the Head of The Central Army Hospital Prague CZ – Prof. MU Dr. Miroslav Zavoral Dr Sc., so as the Head of the Army Forensic Clinic prime MUDr. Miloš Sokol Ph. D., No. 36 C 181/2009-123 since March 27, 2012

The mortal orthopaedic injuring from the Regional Hospital Mladá Boleslav was completed by in forced extreme repeated RTG ionisation in January 2012, when the summary radiation caused me the Leukaemia B-CLL, perfect detect on the Blood parameters since October 2012 and as the mortal diagnose it was diagnosed perfect with details in Haematology of Institute of Clinic and Experimental Medicine Prague 4, CZ from the February 2013.

In just time my orthopaedic diseases are continuing with drastic limiting my locomotion abilities, with full plegic destruction of the nervous Ischiadic in my right underknie since the November 13, 2007 for ever, with in forced next reoperation THA in November 30, 2007, with many repeated annually risky patient fallen with 8 x more probable mortal repeated the breaking proximal femoral bone as it is usual in Cluster Patient with standard THA. With leukemic destructions with redundant in forced extreme ionisation – out of Court Judicial Question IT WAS MEDICAL IMPLANTING PROCESSING LEGE ARTIS CZ? All my Murders are smiling me in Complot among the Culprits and Knowing Court Experts MU Drs with the worldwide famous evaluation Health care against Patients CZ, it is calling LEGE ARTIS CZ! There are after false illegal usage Medical Devices about 40 thousands Patients CZ needless heavy injured and mostly preliminary casual dying Antaly.

None of State Penalty Offices CZ could renew the Penalty Court Trial against my Murders with perfect respects medical official Tittles MU Dr CZ, I have asked it since the July 2013 vainly! The Judge JUDr. Vojtěch Cepl from the Regional Court Prague was perfect informed before Court dealing by my Criminal evidences by written in my recommended Letter since the July 17, 2012, despite the accepting of False Medical Court Message was realised officially in September 17, 2012, the false criminal

argumented Judgement was derived from the false Court Medical Message as No. 36 C 181/2009-221 since September 24, 2012 –Patient post operational Unhappy, no Fausse route stem. I was asking about Civic Legal Support for my Human Rights CZ to justified Court processing with the justified and verified Criminal evidences only by Penalty Court Trial, including asking the Ombudsman CZ about support, but It is without a like hood official Answering till today's. I have no money and no Healthy to defend my Human Rights in the European Court for Human Rights EU/CZ in the Strasbourg, but I hope in your empathy and rational reuse to decide the Method S_T_A_R_S – Statistical Retrieval and search of sufficient information to Mass usage for repeated similar strategic decision making with risk and computer support, 21532 CZ 2010.

The Used and contextual Orthopaedic Literature

- i. /1/ Set of Health Orthopaedic Patient Documentation Antonín Cuc for civic Court Trial No 36 C 181/2009 by the Regional Court Prague CZ, my Advocate JU Dr. Ing. Rudolf Kutnar, Prague, against the Regional Hospital Mladá Boleslav - with Judge JU Dr. Vojtěch Cepl.
- ii. /2/ Set of Producer in voids, Certification conditions for all Users set THA - Bicontact S, Noncemented, with the metallic Stem Dimensions 13 millimetres, type N, Ceramic Head, B. Braun Germany, firm documentation (It is to share from www.B.Braun, Germany).
- iii. /3/ Court Medical Message from the Knowing Medical institute – The Central Army hospital Prague, CZ, no 36 C 181/2009-123 since March 27,2012.
- iv. /4/ The recommended Letter from the Plaintiff Antonín Cuc since July 17, 2012 for the Judge JU Dr. Vojtěch Cepl, The Regional Court Prague (It is published so as in the Private Profile Antonín Cuc in openscientific net LinkedIn – as a criminalistic Standpoint of the State Investigator and a Plaintiff to the Court Medical Message No. 36 C 181/2009-123 since March 27, 2012.
- v. /5/ The Suggest Antonín Cuc to open Civic moving. The Chart 2017 by open letter to Ombudsman CZ JU Dr. Anna Šabatová since the September 27, 2017 to support the respects for Human rights of Patients EU/CZ namely to care the Human Rights for safety legal usage Medical Devices CE with regards to Technical Requirements of Laws EU/CZ in the legal Providers Health Care CZ only, with responsible well educated and skilled Medical staff in legal medical workflow only.



This work is licensed under Creative Commons Attribution 4.0 License
DOI: [10.19080/OROAJ.2018.11.555818](https://doi.org/10.19080/OROAJ.2018.11.555818)

Your next submission with Juniper Publishers will reach you the below assets

- Quality Editorial service
- Swift Peer Review
- Reprints availability
- E-prints Service
- Manuscript Podcast for convenient understanding
- Global attainment for your research
- Manuscript accessibility in different formats
(Pdf, E-pub, Full Text, Audio)
- Unceasing customer service

Track the below URL for one-step submission

<https://juniperpublishers.com/online-submission.php>