Juniper publishers
key to the Researchers

Orthopedics and Rheumatology
Open Access Journal

Research Article
Volume 2 Issue 2 - April 2016

Ortho & Rheum Open Access J
Copyright © All rights are reserved by Asal Fouad

Treatment of Proximal Interphalangeal (PIP) Joint Fracture by Dynamic Kirschner Wire Fixator

Asal Fouad[1], Galal Hegazy[2]*, Mahmoud Seddik[2], Hesham Safwat[2], Mohamed Negm[2] and Ibrahem El-sebaey[2]

[1]*Kuwait Ministry of Health, Kuwait*

[2]*Faculty of Medicine, AL-Azhar University, Egypt*

Submission: April 11, 2016; **Published:** April 20, 2016

***Corresponding author:** Galal Hegazy MD, Lecturer of orthopedic surgery, Orthopedic Department, Faculty of Medicine, AL-Azhar University, Cairo, Egypt, Tel: +2-0106696290; Fax: +2-27878601; Email: glalhegazy@live.com

Abstract

Aim: To describe the clinical outcome of treatment of proximal interphalangeal (PIP) joint fractures by dynamic Kirschner wire fixator.

Methods: The Kirschner wire traction fixator was used in treatment of 22 patients with pilon fracture and fracture-dislocation of proximal inter phalangeal joint. Little finger affected in eight patients, ring in three patients and middle and index fingers were affected in five and six patients respectively. The patients age at time of surgery range from 18 - 58 years (average 35.4 years). The base of proximal phalanx was involved in an average 45% (range from 35% to 70%). We used the Michigan hand score to evaluate the clinical outcome after average follow up 8 months (range from 6-9 months).

Results: Average Michigan hand questionnaire was 88% (range from 63%-100%). The average active flexion-extension ROM of proximal interphalangeal joint was 93 degrees (from 50-120 degrees). No instability or angular deformity at the end of follow up. Pin tract infection reported in four patients and two patients had moderate pain with proximal interphalangeal joint flexion more than 50 degrees.

Conclusion: The Kirschner wire traction fixator was easy to apply, can reduce and maintain reduction of unstable proximal interphalangeal joint fractures and allow immediate post operative (PIP) joint motion.

Keywords: Fracture dislocation of PIP joint; Kirschner wire traction fixator; Dynamic traction fixation; Bent wire fixator; Pilon fracture of middle phalanx

Abbreviations: PIP: Proximal Interphalangeal Joint; DIP: Distal Interphalangeal Joint; ROM: Range Of Motion; NSAID: Non Steroidal Anti-Inflammatory Drugs; VAS: Visual Analogue Scale; PRTS: Pins and Rubber Traction System

Introduction

Proximal interphalangeal (PIP) joint injuries remain challenging to hand surgeons [1]. Painless, stable and mobile PIP joint are the main goals for any treatment option of PIP joint [2,3]. Closed reduction and extension block pins [1,2] Open reduction of PIP joint fractures [3,4] and osteochondral hemi-hamate autograft arthroplasty [5,6] described for treatment of such difficult injuries. Maintenance of satisfactory alignment of the fracture and acceptable congruent joint surface, while allowing early joint motion would seem to be an ideal treatment option. Dynamic external fixation of PIP joint fractures provide indirect fracture reduction, maintain fracture alignment and allowing early movement which results in satisfactory functional outcome [7-13]. The present study describe the clinical outcome of treatment of (PIP) joint fracture by dynamic Kirschner wire fixator modified by Asal Fouad in 2009 [14].

Patients and Method

The modified Kirschner wire traction fixator applied to 22 patients with PIP joint fracture and fracture-dislocations. We exclude fractures more than 3 weeks duration and open fractures with cut tendons or neurovascular injuries. Gender, age at the time of surgery, mechanism of injury, affected side and finger, hand dominance, occupation, fracture type and degree of involvement of base of middle phalanx described in. there were four patients with open fracture, two of them had infected wounds. The average time from injury to surgery was 5 days (range from 2-21 days) (Table 1). The modified Kirschner wire traction fixator had the same principles of Suzuki et al. [15] fixator.

Table 1: Pre-operative patients' clinical parameters and fracture description.

PatientNo.	Gender	Age (Range 18-58) Average 35.4 y	Occupation	MOI	Side(13 R + 9 L)	DOM	Finger	Time from Injury to Surg. Days	Fracture Type
1	F	31	House wife	Falling	L		Little	2	Dorsal F-D
2	M	42	Typist	Falling	R	+	Ring	3	Dorsal F-D
3	M	18	Student	Ball Strike	R	+	index	2	Volar F-D
4	M	29	Manual W.	Entrapment in machine	R	+	index	21	Open pilon fracture
5	F	27	Manual W.	Falling	L		Little	4	Dorsal F-D
6	M	38	Manual W	Quarrel	R	+	Index	2	Volar F-D
7	F	37	Manual W	Falling	L	+	Little	3	Dorsal F-D
8	M	34	Teacher	Ball Strike	R		Ring	5	Pilon
9	F	58	House wife	Falling	L		Middle	4	Dorsal F-D
10	M	44	Manual W.	Falling	L		Little	2	Volar F-D
11	M	34	Manual W.	Falling	R	+	Index	6	Dorsal F-D
12	F	29	Teacher	Ball Strike	R	+	Middle	4	Dorsal F-D
13	M	38	Manual W.	Entrapment in machine	R	+	Little	18	Open pilon fracture
14	M	30	Manual W	Quarrel	R	+	Index	4	Open Volar F-D
15	M	20	Student	Ball Strike	R		Index	10	Dorsal F-D
16	M	26	Manual W.	Ball strike	L		Little	2	Dorsal F-D
17	M	36	Manual W.	Falling	L		Middle	2	Dorsal F-D
18	F	39	Typist	Ball Strike	R	+	Middle	4	Dorsal F-D
19	F	31	House wife	Falling	L	+	Little	4	Dorsal F-D
20	M	43	Manual W	Entrapment in machine	R	+	Ring	2	Open Dorsal F-D
21	F	41	House wife	Falling	L		Little	2	Pilon
22	M	50	Lawyer	Falling	R	+	Middle	4	Volar F-D

Abbreviations: No: Number; M: Male; F: Female; Manual W.: Manual Worker; R: Right; L: Left; DOM: Dominance; Dorsal F-D: Dorsal Fracture-Dislocation; Volar F-D: Volar Fracture-Dislocation

Surgical Steps

Without tourniquet under digital nerve bock anesthesia used 10 ml combination of (5 ml lidocaine 2%, 4 ml bupivacaine 0.25% and 1 ml sodium bicarbonate 0.25 m Eq/ml) and image intensifier the fixator applied in steps. All open fractures treated firstly by wound debridement and saline irrigation. Prophylactic antibiotics administrated for all patients.

Step 1: *Axial traction Pin (K1)*. A smooth 0.9 mm Kirschner wire was placed centrally in the proximal phalanx head perpendicularly on its long axis. The wire was bended in 90-degree angle at both sides of the finger in the direction of finger tip. Each end of the wire must be long enough to reach about 2 cm distal to the finger tip and fashioned in semicircle. (Figure 1 & 2)

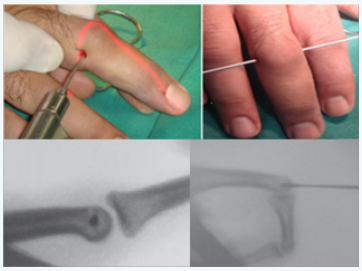

Figure 1: Insertion of axial traction Kirschner wire pin 0.9 mm (K1) in the center of rotation of the proximal phalanx.

How to cite this article: Asal F, Galal H, Mahmoud S, Hesham S, Mohamed N, et al. Treatment of Proximal Interphalangeal (PIP) Joint Fracture by Dynamic Kirschner Wire Fixator. Ortho & Rheum Open Access J. 2016; 2(2): 555582. DOI: 10.19080/OROAJ.2016.02.555582

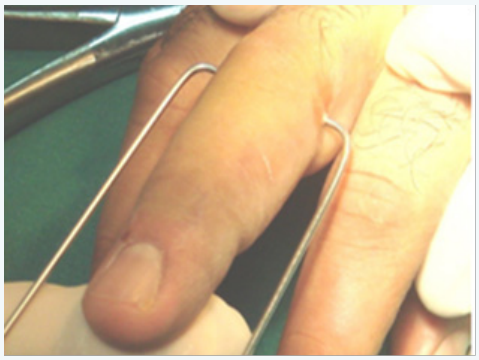

Figure 2: Bending of axial traction pin (K1).

Step 2: *Sliding traction pin (K2):* A smooth 0.9 K-wire was placed centrally in the head of middle phalanx. The K2 pin was bended around K1 forming a semicircles (Figure 3).

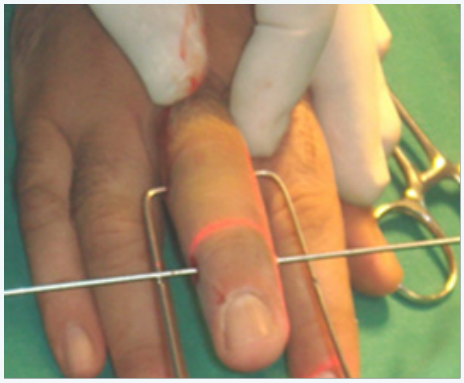

Figure 3: Insertion of sliding traction Kirschner wire pin (K2) in the middle phalanx distal to the fracture.

Step 3: *The traction generated by 18 gauge cerclage wire* in a figure-of eight fashion which applied from the semicircles of the K2 pin to the semicircles of the K1 pin at each side. Traction force, traction balance on both sides and fracture reduction were assessed by image intensifier. Using the cerclage wire in traction was the difference between this fixator and Suzuki et al. fixator which used the rubber bands for traction (Figure 4).

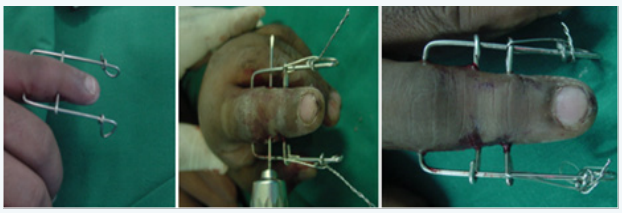

Figure 4: Bending of distal end of axial traction pin (K1) 2 cm distal to finger tip and bending of sliding traction pin (K2) around (K1) in a manner allowing sliding of the K2 over K1 when traction applied to K2 and insertion of reduction pin (K3).

Step 4: *Placement of the reduction pin (K3):* the reduction pin was indicated in 12 patients because of residual displacement after traction. The K3 pin was drilled 5mm distal to the fracture line using K1 pin as a fulcrum to reduce the fracture or dislocation then it bended around K1 at both sides in a semicircle fashion. Lastly, the reduction, active finger motion and fixator stability were checked under image intensifier (Figure 4).

Early range of motion was encouraged for all fingers (Figure 5). The patients followed clinically and radiographically twice weekly till removal of fixator at the six week postoperative, then every three weeks for the next three months and once per month till the end of follow up period which usually range between 6 to 9 months (average 8). The subjective satisfaction was determined by the use of visual analogue scale (VAS) for pain. The Michigan hand questionnaire [16] was used to evaluate the results of using the Kirschner wire dynamic fixator.

Figure 5: Finger movement a) intra-operative b) during follow up period c) immediate post removal of the fixator.

ResultsThe average Michigan hand scores were 88% (range from 63% - 100%), the average active Flexion-Extension ROM of PIP joint at the final follow up evaluation was 93 degrees (range from 50 – 120 degrees) and the average active Flexion-Extension ROM of DIP was 71.5 degrees (range from 60 – 80 degrees) (Figure 6). Twenty patients returned to previous work and recreational activities without disability and the other two patients changed their work because of pain with PIP flexion more than 50 degrees. Five patients developed pin tract infection without wire loosening resolved with oral antibiotics. One patient developed osteomyelitis treated with fixator removal, surgical debridement and antibiotics. Aseptic loosening of the wires and osteolysis in the head of proximal phalanx occurred in one patient that treated with fixator removal. According to VAS there were four patients complained of mild pain with extreme flexion which did not need treatment or affect daily activities and two patients had moderate pain treated with NSAID (Table2).

How to cite this article: Asal F, Galal H, Mahmoud S, Hesham S, Mohamed N, et al. Treatment of Proximal Interphalangeal (PIP) Joint Fracture by Dynamic Kirschner Wire Fixator. Ortho & Rheum Open Access J. 2016; 2(2): 555582. DOI: 10.19080/OROAJ.2016.02.555582

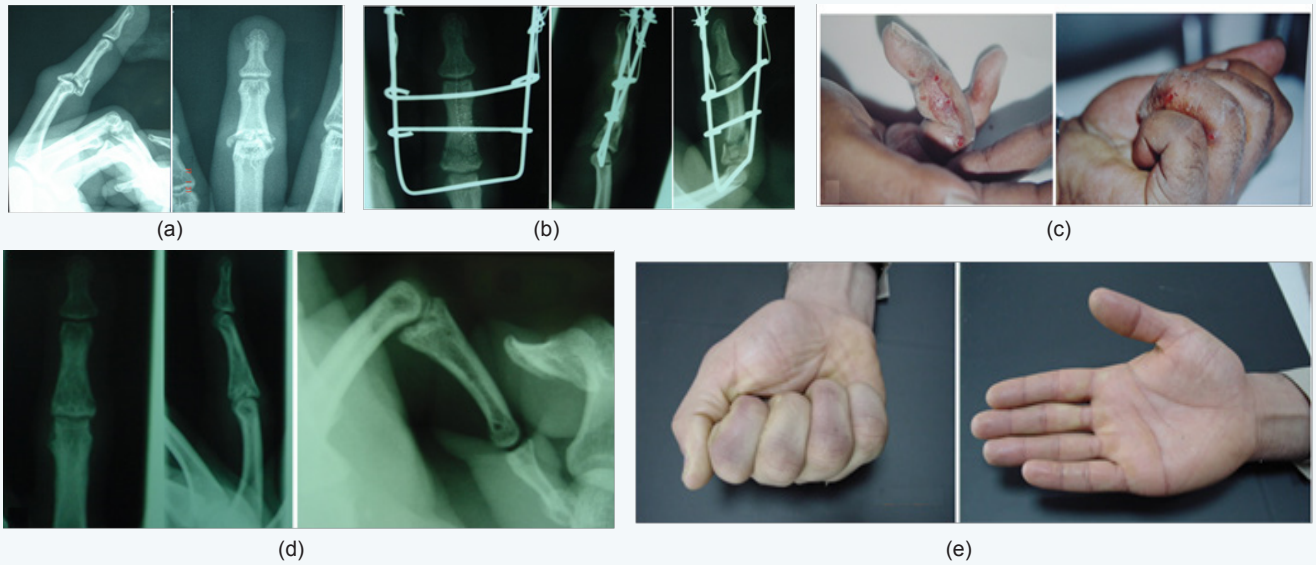

Figure 6: Male patient 34 years old at the time of injury had pilon fracture of RT ring finger. a) PA and LAT views show pilon fracture base of middle phalanx ring finger. b) PA, LAT and Oblique views of two weeks post-operative show accuret reduction of the articular surface using the dynamic fixator. c) Photo pictures show finger motion immediately after fixator removal. d) Nine months post operative PA and LAT (in extension and flexion) views show congurent joint surface. e) Nine months post operative photo pictures show full range of motion (flexion and extension) of the RT ring finger.

Table 2: Results summary.

Patient No.	Follow upMonths	PIPROM	DIPROM	VASScale in mm	Normalized Michigan Hand scores	Complications	Return toWork
1	6	100	75	4	92&	Pin tract infection	Returned
2	7	110	80	0	95%	No	Returned
3	6	110	80	0	97%	No	Returned
4	8	50	60	60 Severe pain	65%	Osteomyelitis Loosening	Changed his work
5	9	80	70	20 Mild pain	78%%	No	Returned
6	8	115	80	0	100%	No	Returned
7	8	100		0	85%	Pin tract infection	Returned
8	8	120	80	0	100%	No	Returned
9	9	80	70	15 Mild pain	75%	No	Returned
10	8	110	75	0	96%	No	Returned
11	8	75	70	25 mild pain	74%	Pin tract infection	Returned
12	9	80	70		80%		Returned
13	9	50	60	55 Moderate pain	63%	Osteolysis of head of proximal phalanx + loosening	Changed his work
14	8	85	75	3	90%	No	Returned
15	9	75	70	25 Mild pain	83%	No	Returned
16	8	120	80	0	100&	No	Returned
17	7	100	80	3	92%	Pin tract infection	Returned
18	9	85	80	4	90%	No	Returned
19	7	90	75	0	95%	No	Returned
20	8	100	75	0	90%	Pin tract infection	Returned
21	9	115	80	0	100%	No	Returned
22	8	90	80	4	94%	No	Returned

How to cite this article: Asal F, Galal H, Mahmoud S, Hesham S, Mohamed N, et al. Treatment of Proximal Interphalangeal (PIP) Joint Fracture by Dynamic Kirschner Wire Fixator. Ortho & Rheum Open Access J. 2016; 2(2): 555582. DOI: 10.19080/OROAJ.2016.02.555582

Discussion

The management of intra-articular fractures and fracture dislocations of PIP joint is a therapeutic challenge for most hand surgeons [17,18]. In trial to stabilize and maintain fracture reduction of PIP joint a trans-articular K-wire has been used for these proposes but joint movements prevented for at least three weeks after surgery till removal of the K-wire [19,20]. Salter et al. [21] in 1981 established the importance of continuous active and passive movements in healing of hyaline articular cartilage. They concluded that, immobilization of any joint interfere with the normal distribution of synovial fluid and nutrition of articular cartilage. In a comparative study between the use of splinting, dynamic traction fixator and ORIF of pilon fracture of PIP joint Stern et al. [11] in 1991 concluded that ORIF can achieve anatomical reduction in some cases but should be approached cautiously. Extensive soft tissue dissection may deprive the smaller fragments from its blood supply and contribute to stiffness. The ligamentotaxis provided by dynamic fixator achieved and maintained the reduction of pilon fracture of PIP joint and give results which are radiologically and clinically comparable or even better than those obtained by ORIF. The results of our study support Stern et al. [11] conclusion in that the use of dynamic external fixation reduce the articular surface indirectly by means of ligamentotaxis which preserve wide joint space and allowing early active ROM of the PIP joint. The Kirschner wire dynamic traction fixator is simple in the design and application, also it allow both active and passive joint ROM. Inanami et al. [24] in 1993 treated seven PIP joint fracture-dislocations with dynamic finger fixator, the average PIP joint ROM was 88 degrees after average follow up 21 months. Allison [25] in 1996 reported average PIP joint ROM 77 degrees after treatment of 14 patients with comminuted fracture base of middle phalanx by dynamic external fixator. In this series we reported average PIP joint ROM 93 degrees in 22 patients treated with dynamic external fixator. We believed that our results was more better than Inanami et al. [24] and Allison [25] because of the use of spiral springs and the size of rings in their fixators can complicate this methods [23]. The modified Kirschner wire traction fixator is simple and had the same idea of dynamic traction fixation as PRTS of Suzuki et al. [15] but we believed that it had technically different points in the design and application 1- the bending of sliding traction pin (K2) around the axial traction pin (K1) give the advantage of stability and parallelism of (K1) to the long axis of middle phalanx. This makes the traction in line with the long axis of middle phalanx bone which results in more easily, maintained and acceptable fracture reduction. 2- Using of tension band wire instead of rubber bands was more amenable during healing time, maintain fracture reduction and give us the chance to modify the traction force by increasing or decreasing the tightness of tension band wire in outpatient clinic according to follow up radiographs. 3- In the modified Kirschner wire traction fixator we can use the (K1) pin as a fulcrum by reduction pin (K3) to get reduction because it was fixed by bending of (K2) pin around it but this option not possible with Suzuki et al fixator. Another point of view the bending of (K3) pin over (K1) pin after fracture reduction gave more stability to the reduction even if the traction lost during follow up. De Soras et al. [23]. In 1997 noted inflammation around the pin sites in up to 45% of cases and reported one case of sever osteolysis which involved almost the whole of the head of the proximal phalanx. In our series, although four patients developed a superficial pin-site infection which was successfully treated by oral antibiotics, one case developed osteomyelitis treated by surgical debridement, early removal of fixator and intravenous antibiotics. Another one case developed marked osteolysis in the head of proximal phalanx which needed earlier removal of the traction system. The final results of these two patients were completely unsatisfied; they had limited painful PIP joint ROM required regular NSAID administration. We believed that the unsatisfactory results of these two patients due to potentially infected open injuries and late presentation. Our overall results, and the mean range of active flexion, compare favourably with those of other types of dynamic traction splint (Table 3).

Table 3: Range of active flexion at the PIP joint with different dynamic traction systems.

Study	Mean Range of Active Flexion of the PIP Joint
Agee [12]	83.0
Suzuki et al. [15]	80.0
Schenck [17]	87.0
Inanami et al. [22]	88.0
Allison [23]	77.0
De Soras et al. [24]	84.0
Fahmy [26]	83.0
Present series	92.8

Conclusion

We believed that the capsule-ligamentotaxis of the Kirschner wire dynamic traction fixator achieved reasonable articular congruity. The modified Kirschner wire dynamic traction fixator has given very acceptable results with a low rate of complication. It is light, cheap, effective and easy to apply. Immediate and continuous post operative (PIP) joint motion improved the range of motion regardless the accuracy of fracture reduction which reflected positively on the final outcome of the patients.

References

1. Ng CY, Oliver CW (2009) Fractures of the proximal interphalangeal joints of the fingers. J Bone Joint Surg Br 91(6): 705-712.
2. Calfee RP, Sommerkamp TG (2009) Fracture-dislocation about the finger joints. J Hand Surg Am 34(6): 1140-1147.
3. Aladin A, Davis TR (2005) Dorsal fracture dislocation of the proximal

How to cite this article: Asal F, Galal H, Mahmoud S, Hesham S, Mohamed N, et al. Treatment of Proximal Interphalangeal (PIP) Joint Fracture by Dynamic Kirschner Wire Fixator. Ortho & Rheum Open Access J. 2016; 2(2): 555582. DOI: 10.19080/OROAJ.2016.02.555582

interphalangeal joint: a comparative study of percutaneous Kirschner wire fixation wire fixation versus open reduction and internal fixation. J Hand Surg Br 30(2): 120-128.

4. Wolfe SW, Katz LD (1995) Intra-articular impaction fractures of the phalanges. J Hand Surg Am 20(2): 327-333.

5. Williams RM, Kiefhaber TR, Sommerkamp TG, Stern PJ (2003) Treatment of unstable dorsal proximal interphalangeal fracture/dislocations using a hemi-hamate autograft. J Hand Surg Am 28(5): 856-865.

6. Williams RM, Hastings H, Kiefhaber TR (2002) PIP Fracture/Dislocation Treatment Technique: Use of a Hemi-Hamate Resurfacing Arthroplasty. Tech Hand Up Exterm Surg 6(4): 185-192.

7. Eaton RG, Malerich MM (1980) Volar plate arthroplasty of the proximal interphalangeal joint: a review of ten years' experience. J Hand Surg Am 5(3): 260-268.

8. Agee JM (1978) Unstable fracture dislocations of the proximal interphalangeal joint of the fingers: a preliminary report of a new treatment technique. J Hand Surg Am 3(4): 386-389.

9. Ruland RT, Hogan CJ, Cannon DL, Slade JF (2008) Use of dynamic distraction external fixation for unstable fracture-dislocations of the proximal interphalangeal joint. J Hand Surg Am 33(1): 19-25.

10. Hastings H, Ernst JM (1993) Dynamic external fixation for fractures of the proximal interphalangeal joint. Hand Clin 9(4): 659-674.

11. Stern PJ, Roman RJ, Kiefhaber TR, McDonough JJ (1991) Pilon fractures of the proximal interphalangeal joint. J Hand Surg Am 16(5): 844-850.

12. Agee JM (1987) Unstable fracture dislocations of the proximal interphalangeal joint. Treatment with the force couple splint. Clin Orthop Relat Res (214): 101-112.

13. Salter RB, Simmonds DF, Malcolm BW, Rumble EJ, MacMichael D, et al. (1980) The biological effect of continuous passive motion on the healing of full thickness defects in articular cartilage. J Bone Joint Surg Am 62(8): 1232-1251.

14. El-Sharkawy AA, El-Mofty AO, Moharram AN, Abou Elatta MM, Asal F (2009) Management of Rolando fracture by modified dynamic external fixation: a new technique. Tech Hand Up Extrem Surg 13(1): 11-15.

15. Suzuki Y, Matsunaga T, Sato S, Yokoi T (1994) The pins and rubbers traction system for treatment of comminuted intraarticular fractures and fracture-dislocations in the hand. J Hand Surg Br 19(1): 98-107.

16. Chung KC, Pillsbury MS, Walters MR, Hayward RA (1998) Reliability and validity testing of the Michigan Hand Outcomes Questionnaire. J Hand Surg Am 23(4): 575-587.

17. Schenck RR (1994) The dynamic traction method. Combining movement and traction for intra-articular fractures of the phalanges. Hand Clin 10(2): 187-198.

18. Dionysian E, Eaton RG (2000) The long-term outcome of volar plate arthroplasty of the proximal interphalangeal joint. J Hand Surg Am 25(3): 429-437.

19. Wilson JN, Rowland SA (1966) Fracture-dislocation of the proximal interphalangeal joint of the finger. J Bone Joint Surg Am 48(3): 493-502.

20. Twyman RS, David HG (1993) The doorstop procedure. A technique for treating unstable fracture dislocations of the proximal interphalangeal joint. J Hand Surg Br 18(6): 714-715.

21. Salter RB, Bell RS, Keeley FW (1981) The protective effect of continuous passive motion on living articular cartilage in acute septic arthritis: an experimental investigation in the rabbit. Clin Orthop Relat Res (159): 223-47.

22. Inanami H, Ninomiya S, Okutsu I, Tarui T (1993) Dynamic external finger fixator for fracture-dislocation of the proximal interphalangeal joint. J Hand Surg Am 18(1): 160-164.

23. Allison DM (1996) Fractures of the base of the middle phalanx treated by a dynamic external fixation device. J Hand Surg Br 21(3): 305-10.

24. De Soras X, De Mourgues P, Guinard D, Moutet F (1997) Pins and Rubbers Traction System. J Hand Surg Br 22(6): 730-735.

25. Schenck RR (1986) Dynamic traction and early passive movement for fractures of the proximal interphalangeal joint. J Hand Surg Am 11(6): 850-858.

26. Fahmy NR (1990) The Stockport Serpentine Spring System for the treatment of displaced comminuted intra-articular phalangeal fractures. J Hand Surg Br 15(3): 303-311.

How to cite this article: Asal F, Galal H, Mahmoud S, Hesham S, Mohamed N, et al. Treatment of Proximal Interphalangeal (PIP) Joint Fracture by Dynamic Kirschner Wire Fixator. Ortho & Rheum Open Access J. 2016; 2(2): 555582. DOI: 10.19080/OROAJ.2016.02.555582