

Live *Taenia* Worms in the Appendix: A Case Report



Irfan Nazir Mir^{1*}, Naseer A Awan¹, Mir Mujtaba Ahmad², Arif Bashir¹, RaziaBano¹, Alfar Ah Nafee¹ and Amir Hussain Chirag¹

¹Department of General Surgery, GMC, India

²Department of General Surgery, HIMSR, India

Submission: September 01, 2017; Published: September 18, 2017

*Corresponding author: Irfan Nazir Mir, Department of General Surgery, GMC, Srinagar, India, Tel: 9906460646, Email: irfanazir@gmail.com

Abstract

Taenia saginata is a zoonotic cestode causing *taeniasis*. *Taeniasis* refers to the intestinal infection with the adult stage of this tapeworm. An association between *taeniasis* and acute appendicitis is uncommon. We present the case of a 60 year old female who presented with abdominal pain for one day. She was diagnosed with having appendicitis and an appendectomy was performed. Live worms were retrieved intraoperatively from the distended, inflamed appendix. pathology of the appendix showed *Taenia saginata* eggs in the lumen. Histological analysis showed acute inflammation consistent with acute appendicitis caused by *T. saginata*.

Keywords: *Taenia saginata*; Appendicitis; *Taeniasis*

Introduction

Taenia saginata, more commonly known as beef tapeworm, is a zoonotic cestode that causes *taeniasis*. *Taenia saginata* requires a cow as an intermediate host but humans are the only definitive hosts for the adult stage of the parasite. Adult tapeworms infest the human small intestine where they attach to the mucosa to absorb food from the host. Adult worms can reach a length of 4 to 6 meters and survive for as long as 25 years in the definitive host [1-6]. *Taeniasis* occurs worldwide and is relatively more common in developing countries where raw or undercooked meat with *cysticercus bovis* (larval stage) is consumed as part of traditional food cultures [6-10]. Once the *cysticercus bovis*, the larval stage, is ingested, the larval worm excysts in the small intestine and develops into an adult within two months, then the scolex attaches itself to the intestinal mucosa to initiate infection.

Most people with a light infection are asymptomatic or have minor complications lasting years. With fairly heavy infections, people may have allergic reactions, constipation, diarrhea, dizziness, and nausea, and weight loss, irritation of the intestine and stomach ache [11,12]. The most common symptom is the presence of proglottids being passed in the feces [11,12]. Rarely, the worm can cause intestinal obstruction [11,12], colonic anastomotic leakage [13] and individual proglottids may migrate into the appendix causes acute appendicitis by blocking the appendiceal lumen [10-14]. Few cases of *T. saginata* infestation

of the appendix have been reported [15]. We report here a case of acute appendicitis caused by *T. saginata*.

Case Report

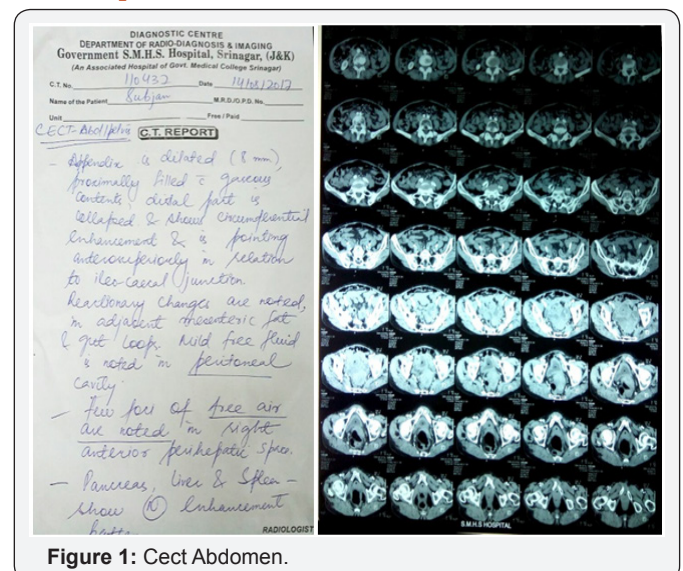


Figure 1: Cect Abdomen.

A 60 year old female presented to our emergency department with a one day history of abdominal pain lower abdomen. On examination she had diffuse tenderness in lower abdomen without any other symptoms or fever. Pain was constant in nature associated with decreased appetite since a few days. With

an Alvarado score of 3/10, patient did not fit into a particular diagnosis, we did a CT scan of abdomen, which revealed features suggestive of perforated appendicitis (Figure 1). The patient was diagnosed with having appendicitis and she underwent an explorative appendectomy. Intraoperatively the appendix was found to be moderately inflamed, distended near tip, no perforation, with no free fluid in peritoneal cavity. After ligating the appendix we opened the tip of the appendix, two live, small (approx 2-3 cm) tape worms came out (Figure 2).

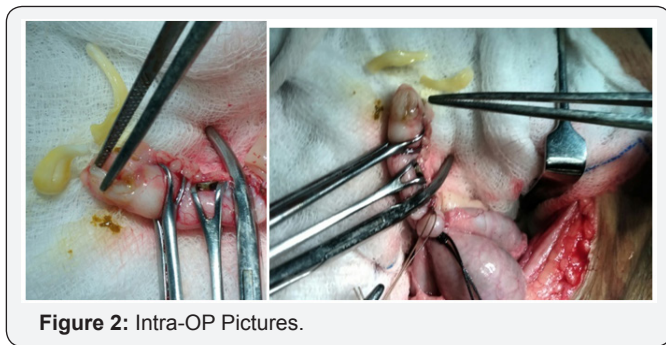


Figure 2: Intra-OP Pictures.

We looked for other viscera in abdomen and pelvis which was found to be grossly normal. In postoperative period patient was dewormed and discharged on 2nd postoperative day. Pathology of the appendix showed inflammation. Histopathology of the appendix showed a free *T. saginata* eggs and fecal matter in the appendix. There was diffuse inflammation covering the appendix and eosinophils (consistent with parasite infection) and neutrophils in the appendiceal wall. These findings are consistent with acute suppurative appendicitis and parasite infestation.

Discussion

Acute appendicitis is a common abdominal emergency worm induced appendicitis is a known entity, however its rare [1]; a small percentage of cases may be due to intestinal worms [2]. The pathogenesis of parasite induced appendicitis is poorly understood [2,3]. One study found 1.5% of acute appendicitis cases were caused by parasites [4]. Some parasites, especially worms, can accidentally enter the appendix. It is unclear why *Enterobius vermicularis* and *Schistosoma haematobium* enter the appendix [5]. *Enterobius vermicularis* is the most common nematode located predominantly in the cecum, appendix and colon and is the most common parasite associated with acute appendicitis [6-9].

Taeniasis is an uncommon cause of appendicitis and few cases have been described in the literature [9-12]. *T. saginata* is one of the most common helminthes located predominantly in the human intestinal tract causing important medical and social problems, especially in developing countries [11]. Adult

worms live in the proximal part of the small intestine without causing any serious symptoms [13,12]. However, in heavy worm infections, proglottids of the parasite may migrate to the pancreas, liver and less commonly into the appendix [13,12].

The most common symptoms with *taeniasis* are abdominal discomfort, epigastric pain, vomiting and diarrhea [13,12]. *T. saginata* associated acute appendicitis may occur as a result of the worm proglottids (ova) entering the appendix [14,15]. However, some cases are reported in the literature where the parasite may be present in the lumen of the appendix [16]. Further studies are necessary to determine the role of parasites in the pathogenesis of acute appendicitis.

References

1. Aydin O (2007) Incidental parasitic infestations in surgically removed appendices: a retrospective analysis. *Diag Pathol* 2: 16.
2. Beaver PC, Jung R (1985) *Animal agents and vectors of human disease*. 5th edn. Lea & Febiger, Philadelphia, USA, 1985: 110-126.
3. Bordon LM (1992) Intestinal obstruction due to *Taenia saginata* infection: a case report. *J Trop Med Hyg* 95: 352-353.
4. Carr NJ, Path MRC (2000) The pathology of acute appendicitis. *Ann Diag Pathol* 4: 46-56.
5. Dorfman S, Cardozo J, Dorfman D, Villar DA (2003) The role of parasites in acute appendicitis of pediatric patients. *Invest Clin* 44: 337-340.
6. Dorfman S, Talbot IC, Torres R, Cardozo J, Sanchez M (1995) Parasitic infestation in acute appendicitis. *Ann Trop Med Parasitol* 89: 99-101.
7. Karatepe O, Adas G, Tukenmez M, Battal M, Altioek M, et al. (2009) Parasitic infestation as cause of acute appendicitis. *G Chir* 30: 426-428.
8. Karanikas ID, Sakellaridis TE, Alexiou CP (2013) Southeast Asian *J Trop Med Public Health* 962(44).
9. Siaperas PA, Fotopoulos AC, Antsaklis GI (2007) *Taenia saginata*: a rare cause of bowel obstruction. *Trans R Soc Trop Med Hyg* 101: 527-528.
10. Kazemzadeh H, Afshar-Moghadam N, Meamar AR, Rahimi HR, Kia EB (2008) *Enterobius vermicularis* and the appendix: report of five cases. *Iranian J Parasitol* 3: 54-55.
11. Lejbkowicz F, Abel AB, Tsilman B, Cohen HI (2002) *Taenia* infestation in the appendix: a report of two cases. *J Med Microbiol* 51: 90-91.
12. Okolie BI, Okonko IO, Ogun AA (2008) Incidence and detection of parasite ova in appendix from patients with appendicitis in south-eastern, Nigeria. *World J Agric Sci* 4: 795-802.
13. Ozcel MA (2007) *Medical parasitic diseases*. Izmir, Turkey: Meta Press, 692-708 (in Turkish).
14. Sartorelli AC, Silva MG, Rodrigues MAM, Silva RJ (2005) Appendiceal taeniasis presenting like acute appendicitis. *Parasitol Res* 97: 171-172.
15. Sozutek A, Colak T, Dag A, Turkmenoglu O (2011) Colonic anastomosis leakage related to *Taenia saginata* infestation. *Clinics* 66: 363-364.
16. Silva DF, Silva RJ, Silva MG, Sartorelli AC, Rodrigues MAM (2007) Parasitic infection of the appendix as a cause of acute appendicitis. *Parasitol Res* 102: 99-102.



This work is licensed under Creative Commons Attribution 4.0 License
DOI: [10.19080/OAJS.2017.06.555676](https://doi.org/10.19080/OAJS.2017.06.555676)

Your next submission with Juniper Publishers will reach you the below assets

- Quality Editorial service
- Swift Peer Review
- Reprints availability
- E-prints Service
- Manuscript Podcast for convenient understanding
- Global attainment for your research
- Manuscript accessibility in different formats
(Pdf, E-pub, Full Text, Audio)
- Unceasing customer service

Track the below URL for one-step submission
<https://juniperpublishers.com/online-submission.php>