

Rare Photograph of Endoscopic View of Gastric Kaposi Sarcoma with Concurrent Candidiasis in an HIV Aids Patient

Dipankar Saha*

Consultant Laparoscopic Surgeon, Desun Hospital, India

Submission: March 21, 2017; Published: March 22, 2017

*Corresponding author: Dipankar Saha, Consultant Laparoscopic Surgeon, Desun Hospital, Kolkata, India, Tel: +919821743606; Email: dipankarsaha8888@gmail.com

Patient profile

Middle aged male of African race suffering of HIV AIDS.

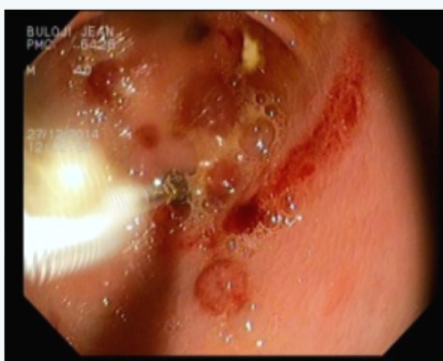

Figure 1: Kaposi lesions in prepyloric region of stomach.

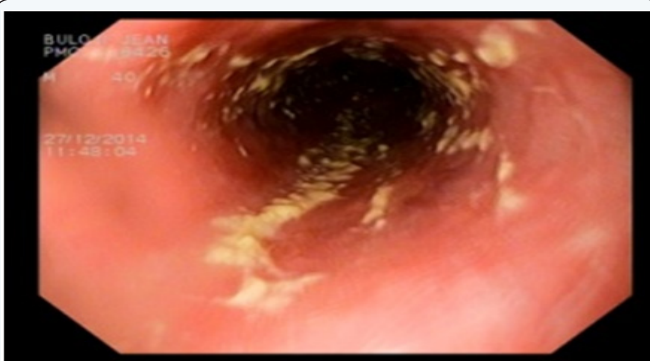


Figure 2: Esophageal candidiasis in same patient.

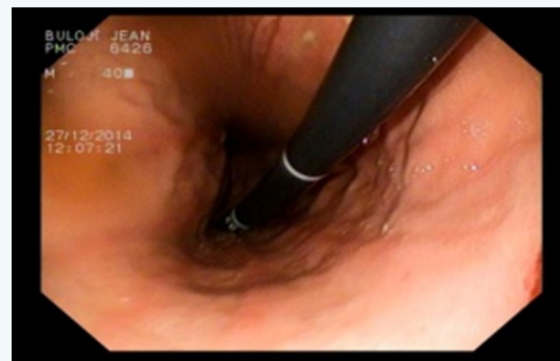

Figure 3: Normal fundus view of stomach.

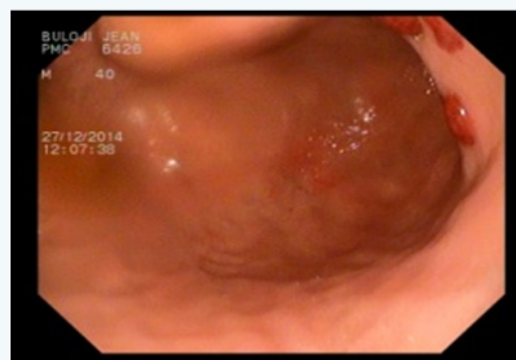

Figure 4: Kaposi lesions in lesser curvature of stomach.



This work is licensed under Creative Commons Attribution 4.0 License
DOI: [10.19080/OAJS.2017.02.555605](https://doi.org/10.19080/OAJS.2017.02.555605)

**Your next submission with Juniper Publishers
will reach you the below assets**

- Quality Editorial service
- Swift Peer Review
- Reprints availability
- E-prints Service
- Manuscript Podcast for convenient understanding
- Global attainment for your research
- Manuscript accessibility in different formats
(Pdf, E-pub, Full Text, Audio)
- Unceasing customer service

Track the below URL for one-step submission
<https://juniperpublishers.com/online-submission.php>