Open Access Journal of
Surgery

Juniper Publishers
key to the Researchers

Case report
Volume 1 Issue 5 – December 2016

Open Access J Surg

Skeletal Muscle Metastasis from Non Small Cell Lung Cancer (NSCLC)... Case Report with Review of Literature

Syed Muhammad Ali[1], Khalifa Al-Wahaibi[2], Kamran Ahmad Malik[2], Zia Aftab[1], Mansoor Al-Mandhari[3]

[1]*Department of Surgery, Hamad Medical Corporation, Qatar*

[2]*Department of Surgery, Sultan Qaboos University Hospital, Oman*

[3]*Depratment of Oncology ,Sultan Qaboos University Hospital, Oman*

Submission: November 20, 2016; **Published:** December 08, 2016

***Corresponding author**: Syed Muhammad Ali, Department of Surgery, Hamad Medical Corporation, PO box 3050, Doha, Qatar, Tel: +97466010468; Email: ali_2051@hotmail.com; alismc2051@gmail.com

Keywords: Skeletal muscle; Non small cell lung cancer

Introduction

Skeletal muscle metastasis (SMM), is a rare condition resulting from non small cell lung cancer(NSCLC). We present a case of 50 yrs old male who presented with a mass in left thigh that was attached to sartorius muscle. It was completely removed and the patient is doing well after four years of surgery.

Case Report

A 50 –year-old male, diagnosed case of adenocarcinoma of the lung (NSCLC) who completed the course of chemotherapy and radiations, presented with a swelling in left thigh .It was painless and increasing in size over the last one month. He didn't show any abnormality on systematic review. Left thigh showed localized swelling over upper medial aspect that was oval in shape, non tender, non- fluctuant, hard without any change in overlying skin.

Radiologic evaluation on MRI showed lobulated mass measuring 4.7*4.5 cms closely related to superficial femoral neurovascular bundle and involving sartorius muscle .The mass showed homogenous T-2 hyper intensity and moderately intense contrast enhancement with internal septae. Mass was inseparable from the superficial femoral artery and nerve (Figure 1&2).

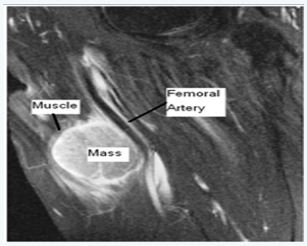

Figure 1: MRI T1 sagital view showing mass close to femoral vessels.

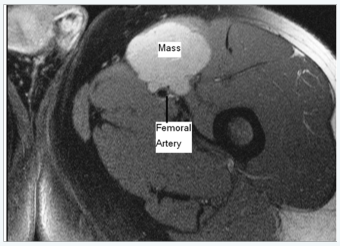

Figure 2: MRI coronal view showing mass encasing vessel.

U/S guided biopsy of the mass showed fragmented tissue consisting of sheets of atypical cells with vesicular nuclei, prominent nucleoli and pale eosinophilic to clear cytoplasm. Occasional mitotic figures were seen. Immunohistochemistry showed positive staining for BerEP4,CK7 ,CK19 and EMA. The appearances were consistent with moderate to poorly differentiated metastatic adenocarcinoma.

Patient underwent surgical excision of the mass in April 2008.Tumor was extending into the quadriceps muscle and invading the fibers of femoral nerve that were removed. It was, however dissected freely out of the femoral vessels. Frozen section confirmed carcinoma and posterior margin free of tumor. Patient made uneventful recovery without any neuro-vascular deficit.

Patient developed swelling again in the same region one month after the surgery, the investigations of which showed soft mass .He underwent surgical excision of the recurrent mass that showed sac like structure filled with soft pasty material .Histopathology of this revealed an organized hematoma, without any evidence of malignancy. His whole body PET-CT done in Oct 2009 showed no recurrence of the disease in left thigh, although he develops recurrent seroma at this site, which responded to multiple aspiration in the clinic. His latest follow up with us in Sep'2011 showed no recurrence at the site of surgery and patient was doing well.

Discussion

Skeletal muscle metastasis (SMM) in a cancer patient is a rare phenomenon [1], and its reported incidence is 0.8-1 % [2-6]. Due to muscular contractility, high tissue pressure [7] local pH environment and accumulation of lactic acid and other metabolites skeletal muscle metastasis (SMM) is rarely found.

In order of frequency lung carcinoma is the leading cause of SMM followed by tumors of kidney, pancreas, thyroid gland, breast, ovary, prostate and bladder cancers [1,8,9]. Analyzing cadaver muscles of patients died of cancers Pearson [4] found skeletal muscle metastasis in 16 % of the cases.

SMM of primary lung tumor are rare and literature includes few reports [1,3,10]. Histologically SMM may present as nodules or infiltrates. Presence of neoplastic vascular emboli may suggest a hematogenous spread [4].

The most frequent presentation is muscular pain with or without swelling [9,10]. Our patient is exception as he presented with a painless swelling of left upper thigh. One case of Intra muscular metastasis from lung cancer presenting as intra muscular abscess has been reported [11].

Diagnosis of this condition can be difficult even with radiological investigations as these can be confused with an abscess or soft tissue tumor [12]. In CT hypodense lesion, sometimes calcified, is seen and normally fat and vascular architecture is blunted [13]. Whole body PET-CT detects unexpected extra thoracic metastasis in 10-20 % of patients with NSCLC and changes therapeutic management in approximately 20 % of the patients [14-16].

Treatment is palliative only as surgical excision, radiotherapy and chemotherapy all are employed [1,10,12]. Regardless of surgical or medical therapy presence of skeletal muscle metastasis is associated with poor survival of less than one year [1,5,10,12]. Our patient is still surviving without any complications after four years of surgical resection.

The onset of muscle pain resistant to medical therapy, in patients of lung cancer should raise the suspicion of skeletal muscle metastasis and thorough diagnostic workup is necessary including MRI, PET-CT, U/S, FNA and surgical exeresis.

Optimal strategy is unknown and presence of SMM does not modify the regimes of chemotherapy and radiations.

Conclusion

Skeletal muscle metastasis is a rare occurrence in non small cell lung cancer. Treatment is palliative only and options are surgical excision, radiotherapy and chemotherapy of metastatic deposit. Prognosis is poor despite all modalities of treatment.

References

1. McKeon PP, Conant P, Aurbach LE (1996) Squamous cell carcinoma of lung: An unusual metastasis to the pectoralis muscle. Ann Thoracic Surg 61(5): 1526-1528.
2. Ramnathan T (1973) Bronchial carcinoma metastases presenting as gluteal abscess. Br J Dis Chest 67(2): 167-168.
3. Menard O, Parache RM (1991) Les metastases musculaires des cancers. Ann Med Intern (Paris) 142: 423-428.
4. Pearson CM (1959) Incidence and type of pathologic alterations observed in muscle in a routine autopsy survey. Neurology 9: 757-766.
5. Di Giorgio A, Sammartino P, Cardini CL, Al Mansour M, Accarpio F, et al. (2004) Lung cancer and skeletal muscle metastases. Ann Thorac Surg 78(2): 709-711.
6. Sudo A, Ogihara Y, Shiokawa Y, Fujinami S, Sekiguchi S (1993) Intermuscular metastasis of carcinoma. Clin Orthop Relat Res 296: 213-217.
7. Nicolson GL (1986) Organ preference of metastasis. Prog Clin Biol Res 212: 25-40.
8. Heyer CM, Rduch GJ, Zgoura P, Stachetzki U, Voigt E, et al. (2005) Metastasis to skeletal muscle from esophageal adenocarcinoma. Scand J Gastroenterol 40(8): 1000-1004.
9. Cheong TH, Wang YT, Poh SC, Thung JL (1989) Carcinoma of the lung with metastasis to skeletal muscles. Singapore Med J 30(6): 605-606.
10. Sridhar KS, Rao RK, Kunhardt B (1987) Skeletal muscle metastases from lung cancer. Cancer 59(8): 1530-1534.
11. Martinez GE, Coursey CA, Dodd L, Martinez S (2008) Simultaneous thigh muscle metastasis from lung cancer and Escherichia Coli gas producing myonecrosis. Skeletal Radiol 37(8): 763-766.
12. Abdul Razak AR, Chhabra R, Heughes A, England S, Dildey P, et al. (2007) Muscular metastasis, a rare presentation of Non Small-cell Lung Cancer. Med Gen Med 9(3): 20.
13. Kunter E, Karagoz B, Bilgi O, Mahirogullari M, Cermik H, Gorur R, Turken O, Kandemir G. Non small cell lung cancer presented as skeletal muscle metastasis. E-Poster in free access. Internet.
14. Vansteenkiste JF (2003) PET scan in the staging of non small cell lung cancer. Lung Cancer 42(1): S27-S37.
15. Weder W, Schmid RA, Bruchhaus H, Hillinger S, von Schulthess GK, et al. (1998) Detection of extra thoracic metastases by positron emission tomography in lung cancer. Ann Thorac Surg 66(3): 886-893.
16. Marom EM, McAdams HP, Erasmus JJ, Goodman PC, Culhane DK, et al. (1999) Staging non small cell lung cancer with whole body PET. Radiology 212(3): 803-809.

How to cite this article: Syed M A, Khalifa Al-W, Kamran A M, Zia A, Mansoor Al-M. Skeletal Muscle Metastasis from Non Small Cell Lung Cancer (NSCLC)... Case Report with Review of Literature. Open Access J Surg. 2016; 1(5): 555573.