Open access Journal of
Neurology & Neurosurgery
ISSN: 2476-0501

Juniper Publishers
key to the Researchers

Research Article
Volume 14 Issue 2 - October 2020
DOI: 10.19080/OAJNN.2020.14.555883

Open Access J Neurol Neurosurg

A Safe and Effective Minimal Invasive Surgery for Ruptured Anterior Circulation Aneurysm

Ying-Ching Li[1], Ting-Wei Chang[1], Chun-Ting Chen[1], Ko Ting Chen[1,4], Po Chuan Hsieh[1], Ching Chang Chen[1], Cheng Chi Lee[1,2], Ya Jui Lin[1,5]

[1]*Department of Neurosurgery, Chang Gung Memorial Hospital, Taiwan*

[2]*School of medicine, National Taiwan University, Taiwan*

[3]*School of medicine, Chang Gung University, Taiwan*

[4]*Program in Biomedical Engineering, Chang Gung University, Taiwan*

[5]*The Graduate Institute of Biomedical Sciences, Chang Gung University, Taiwan*

Submission: September 16, 2020; **Published:** October 02, 2020

***Corresponding author:** Ya Jui Lin, Department of Neurosurgery, The Graduate Institute of Biomedical Sciences, Chang Gung Memorial Hospital, Taiwan

Abstract

Background: Minimal invasive surgery for brain lesion has become a popular concept in selected cases. With advanced diagnostic tools, such as Computed Tomography (CT), Magnetic Resonance Imaging (MRI), high-power microscopy, and endoscopy, it is much easier and safer to approach intracranial aneurysm through transciliary supraorbital keyhole craniotomy. For unruptured intracranial anterior circulation aneurysm, the safety and efficacy were well established. However, the application of the approach in ruptured intracranial aneurysm remains controversial. Thus, we demonstrated the safety, efficacy, and indications of keyhole surgery for clipping ruptured anterior circulation aneurysms.

Methods: Patients of ruptured anterior circulation aneurysm who received surgical clipping in Chang-Gung Memorial Hospital Linkou branch between December 2017 and June 2019 were enrolled. The clinical course and the postoperative outcomes were evaluated. Post-operative CT angiography or digital subtraction angiography (DSA) were performed postoperatively for identification of complete clipping.

Results: Thirty-three patients were suffered from diffuse subarachnoid hemorrhage with ruptured aneurysm as proved by brain CT angiography. 23 patients received traditional pterional approach for aneurysm clipping, and 10 patients received transciliary supraorbital keyhole approach. No statically significant of complete clipping rate, complication rate, and post-operative outcomes between two groups. The cosmetic effect is excellent and satisfactory.

Conclusion: Transciliary supraorbital keyhole approach for ruptured anterior circulation aneurysm is safe and effective in selected cases.

Keywords: Keyhole, Ruptured aneurysm, Mini-invasive, SAH, Anterior-circulation aneurysm

Abbreviations: CT: computed tomography; MRI: Magnetic Resonance Imaging; mRS: Modified Rankin Scale; DSA: Digital Subtraction Angiography; A-com: Anterior Communicating Artery; MCA, Middle Cerebral Artery; P-com, posterior Communicating Artery

Introduction

The less invasive nature of endovascular coiling for aneurysms has led to a sharp decline prevalence of microsurgical clipping. Regardless of some unfavorable outcomes in the case of aneurysms with a wide-neck or complex configuration, very small or large aneurysms, or a branch vessel incorporated into the aneurysm neck, the less invasive nature of endovascular treatment holds a strong appeal for patients [1]. However, higher recurrent rate in endovascular intervention with comparison to surgical clipping still unavoidable. Until now, which treatment is better for aneurysms is controversial. Recently, due to advanced diagnostic tools and intraoperative instruments, minimal invasive surgery for brain lesions has become safer and more effective. Presently, based on appropriate indications and experienced surgeons, the safety and efficacy of transciliary supraorbital keyhole craniotomy for unruptured anterior circulation aneurysms has been well established in literatures [2-8]. However, the application of the approach in ruptured intracranial aneurysm remains controversial due to concern of proximal control and poor surgical view from brain swelling. In this study, transciliary supraorbital keyhole

approach for ruptured anterior circulation aneurysms which located at anterior communicating artery (A-com), M1 segment including the Middle Cerebral Artery (MCA) bifurcation, and the posterior communicating artery (P-com) were applied in our institution, and the feasibility, safety and the surgical outcomes were evaluated.

Materials and Methods

During a 2-year period from December 2017 to June 2019, 33 patients who received surgical clipping for intracranial aneurysms in Chang-Gung Memorial Hospital Linkou Branch. There are 23 patients who received traditional pterional approach, while 10 patients who received transciliary supraorbital keyhole approach. The inclusion criteria for this study were as follows:

a. age > 18 years,

b. diagnosis of ruptured intracranial aneurysms,

c. Hunt-Hess grade ≤4,

d. patients' reluctance to accept the endovascular procedure, and

e. follow-up visit at least more than 3 months after the cranial operations. This study was reviewed and approved by the Ethical Committee of Chang-Gung Memorial Hospital Linkou Branch. Informed consent was signed by each patient, and approval for this study was obtained from the Institutional Review Board of Chang-Gung Memorial Hospital.

Surgical techniques of transciliary supraorbital keyhole approach

The details of the transciliary supraorbital keyhole approach were previously reported by the current authors [1,6,9,10] The skin incision is located just above the eyebrow, starting from supraorbital notch and extending laterally, measuring 3.5 cm in length. In the lateral part of the incision, the temporalis muscle is detached. Extensive skin incision and temporalis permit a supraorbital craniotomy to a diameter of 2-3 cm. Six fish-hooks retracted the incisional wound and allowed drilling of the inner edge of the craniotomy above the orbital rim and frontal floor prominences (Figure1a). Intradural procedures were then performed using a curved dural incision (Figure 1b). After completion of the intracranial procedures, the dural incision is sutured watertight and epidural bleeding is meticulously controlled. An anchor screw technique was used for placing the dural tenting sutures [11]. The bone flap is fixed back by low-profile plates and screws. Thereafter, the bone defects, including the burr hole and bony gaps, are filled with a Polymethylmethacrylate (PMMA) Bone Cement. The pericranium, temporalis and frontalis muscles, and skin layer are then closed by absorbable sutures without drainage tubes [12] Case illustration (Figure 2).

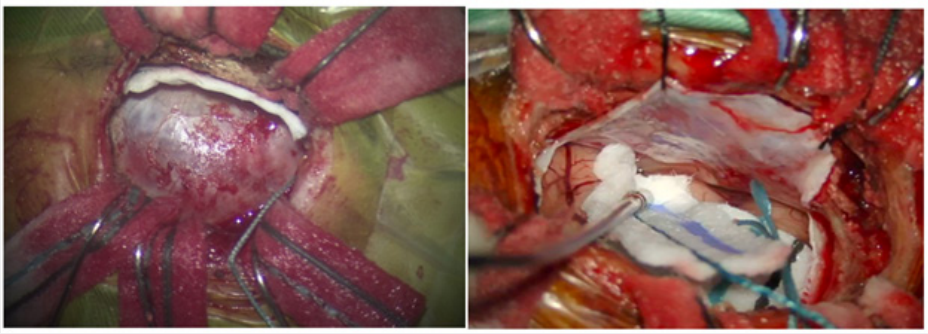

Figure 1: Intra-operative pictures showed the ways of skin retraction and dura incision

A. Skin was incision over eyebrow and retracted by 6 fishhooks. Square craniotomy was done

B. Curved durotomy was done to expose frontal base.

Three patients suffered from sudden onset headache with brain CT at ER showed diffuse subarachnoid hemorrhage, they are brain CTA showed left A1(Figure 2-1), A-com (Figure 2-2), and right MCA bifurcation (Figure 2-3) aneurysm, respectively. Each patient received transciliary supraorbital keyhole craniotomy to clip ruptured aneurysm. Aneurysm dome and neck could be clearly identified by minimal invasive approach. Complete clipping was done and confirmed by post-operative CTA or DSA. All these three patients recovered well and were discharged without neurologic deficit. Post-operative pictures of wound condition showed good cosmetic effect (Figure 3).

Outcomes evaluation

Detailed physical and neurological examinations were performed on all patients during admission and at 3 months postoperatively. Any symptomatic patients were followed up for more than a year. Post-operative Digital Subtraction Angiography (DSA) was performed once within one week after surgery except two patients, one of them was subject to MRI scan who is allergic to contrast and the other had no image due to critical clinical condition. The adequacy of the aneurysm clip placement was verified using 3-dimensional angiography, and the obliteration

How to cite this article: Ying-Ching L, Ting-Wei C, Chun-Ting C, Ko Ting C, Po Chuan H. A Safe and Effective Minimal Invasive Surgery for Ruptured Anterior Circulation Aneurysm. Open Access J Neurol Neurosurg 2020; 14(2): 555883.DOI: 10.19080/OAJNN.2020.14.555883

rate of the aneurysm was also measured during the admission of all patients. The aesthetic aspect of the operative wound was evaluated more than 3 months after the surgery, along with the presence of frontalis palsy.

Figure 2(1):

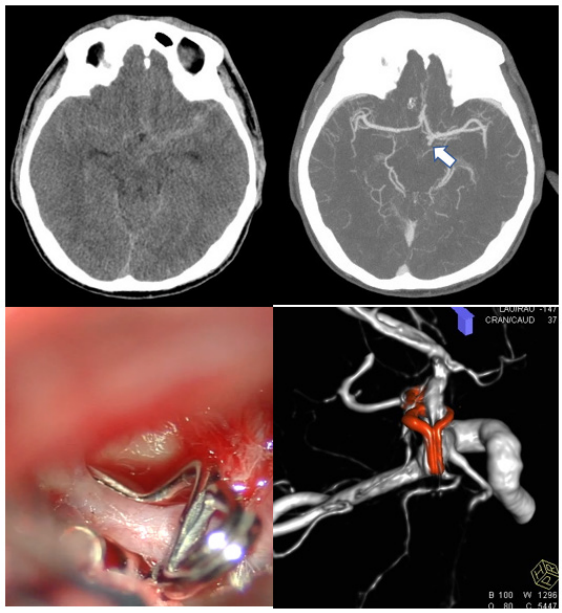

Figure 2(2):

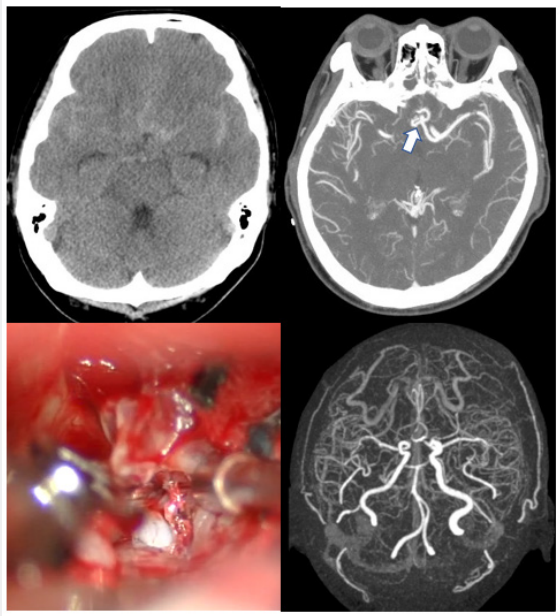

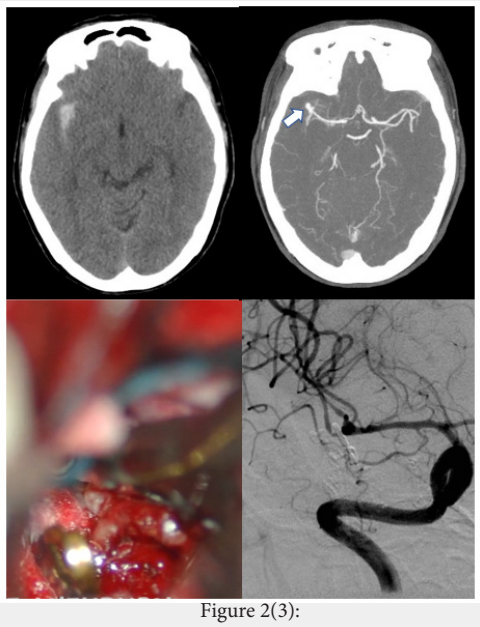

Figure 2(3):

Figure 2: pre-operative, intra-operative, and post-operative images of transciliary supraorbital keyhole craniotomy

(1) Left A1 aneurysm

Pre-op CTA showed diffuse SAH (a) and left A1 bilobular aneurysm (b, white arrow). Fenestrated clip was applied to secure aneurysm and remain A1 patency (c). Post-op angiography showed complete clipping of aneurysm (d).

(2) A-com aneurysm

Pre-op CTA showed diffuse SAH (a) and A-com aneurysm (b, white arrow). One straight clip was applied to secure aneurysm. Aneurysm dome was collapse (C). Post-op CTA showed complete clipping (d).

(3) Right MCA aneurysm

Preop CTA showed right sylvian SAH (a) and right MCA aneurysm (b, white arrow). Complete clipping was done under proximal control on M1 (c). Postop angiography showed no residual sac (d).

How to cite this article: Ying-Ching L, Ting-Wei C, Chun-Ting C, Ko Ting C, Po Chuan H. A Safe and Effective Minimal Invasive Surgery for Ruptured Anterior Circulation Aneurysm. Open Access J Neurol Neurosurg 2020; 14(2): 555883.DOI: 10.19080/OAJNN.2020.14.555883

Figure 3: good cosmetic effect after operation.

Statistical Analysis

Comparisons between groups included the length of stay, blood loss, anesthetic and surgical complications, mRS after 3 months, and the obliteration rate. Data analysis was performed using SPSS version 25 software. Comparisons between groups were performed using contingency table analysis with Pearson's chi-square test, Fisher exact test, and t tests to determine statistically significant differences. A p value of < 0.05 was used to determine statistical significance.

Results

Patient characteristic

The demographic and clinical characteristics of the patients who underwent the transciliary supraorbital keyhole approach and pterional approach are summarized in Table 1. In the transciliary supraorbital keyhole group (n = 10), the age ranged from 35 to 74 years (mean: 53.5 years). The locations of aneurysm were A-com (n=8), MCA one (n=1), and P-com (n=1). The Hunt-Hess grade of the patients were grade 2 in 5 patients, grade 3 in 3 patients, grade 4 in 2 patients. The degree of the subarachnoid hemorrhage was measured by modified Fisher grade (mFisher), and there was only one patient with mFisher grade 1, and respectively three patients for grade 2, grade 3, and grade 4. The ages of patients in the pterional approach group (n = 23) ranged from 35 to 77 years (mean: 54.4 years). The locations of aneurysms were A com (n=11), MCA (n=5), and p-com (n=7). The Hunt-Hess grade of the patients were grade 1 in 2 patients, grade 2 in 15 patients, grade 3 in 2 patients. There were four patients with mFisher grade 1, 10 patients with grade 2, 4 patients with grade 3, and 5 patients with grade 4. The above clinical characteristics of two groups showed no significant differences.

Table 1: The Demographic and Clinical Characteristics of Patients Who Underwent Transciliary Supraorbital Keyhole and Pterional Approach for Ruptured Anterior Circulation Aneurysms Data reported as mean, or number (percentage).

	All N=33	Pterional craniotomy n=23	Transciliary supraorbital keyhole n=10	P-value
Sex				
Female	25(75.8)	18(78.3)	7(70.0)	0.611
Male	8(24.2)	5(21.7)	3(30.0)	
Age (y)	54.12	54.39	53.5	0.845
Lesion side				
Left	20(60.6)	15(65.2)	5(50)	0.41
Right	13(39.4)	8(34.8)	5(50)	
Lesion site				
A-com	19(57.6)	11(47.8)	8(80)	0.225
MCA	6(18.2)	5(21.7)	1(10)	
P-com	8(24.2)	7(30.5)	1(10)	
Hunt-Hess grade				

How to cite this article: Ying-Ching L, Ting-Wei C, Chun-Ting C, Ko Ting C, Po Chuan H. A Safe and Effective Minimal Invasive Surgery for Ruptured Anterior Circulation Aneurysm. Open Access J Neurol Neurosurg 2020; 14(2): 555883.DOI: 10.19080/OAJNN.2020.14.555883

1	2(6)	2(8.7)	0	0.123
2	20(60.6)	15(65.2)	5(50)	
3	9(27.3)	6(26.1)	3(30)	
4	2(6.1)	0	2(20)	
m Fisher grade				
1	5(15.2)	4(17.4)	1(10)	0.731
2	13(39.4)	10(43.4)	3(30)	
3	7(21.2)	4(17.4)	3(30)	
4	8(24.2)	5(21.8)	3(30)	

Angiographic characteristics

The angiographic characteristics of the aneurysms are summarized in Table 2. There was no significant difference between transciliary supraorbital keyhole approach and pterional approach in size of neck (2.54mm versus 2.99mm, p=0.137) and dome (4.59mm versus 5.73, p=0.198). The post-operative CTA or DSA is to identify any residual aneurysm and patency of parent artery. In transciliary supraorbital keyhole group, there were no residual neck of aneurysm in all patients (complete clipping). In pterional group, there were 2 patients with residual neck of aneurysm and 19 patients without residual neck of aneurysm. (Table 3). The post-operative outcome showed no significant differences (P=0.313).

Table 2: Angiographic Characteristics of Aneurysms Operated via Transciliary Supraorbital keyhole and Pterional Approach Data reported as mean, or number (percentage).

	All N=33	Pterional craniotomy n=23	Transciliary supraorbital keyhole n=10	P-value
Dome (mm)	5.38	5.73	4.59	0.198
Neck (mm)	2.85	2.99	2.54	0.137

Table 3: The Long-Term Outcomes and Complications of the Transciliary Supraorbital keyhole and Pterional Approach.

*mRS ≤ 3:	All N=33	Pterional craniotomy n=23	Transciliary supraorbital keyhole n=10	P-value
CSF drainage				0.001
EVD	26(78.8)	21(91.3)	5(50)	
Lumbar drain	5(15.1)	0	5(50)	
No	2(6.1)	2(8.7)	0	
Shunt dependent				
No shunt	19(57.6)	13(56.5)	6(60)	0.853
Shunt	14(42.4)	10(43.5)	4(40)	
Blood loss (ml)	495.75	639.13	166	0.005
Hospital stay (day)	27.27	28.91	23.5	0.612
mRS (3M) *				
Favorable outcome	24(72.7)	17(73.9)	7(70)	0.817
unfavorable outcome	9(27.3)	6(26.1)	3(30)	
Obliteration rate#				
No residual	29(87.9)	19(82.6)	10(100)	0.313
Residual neck	2(6)	2(8.6)	0	
Complications**				
Yes	18(54.5)	14(60.9)	4(40)	0.269
No	15(45.5)	9(39.1)	6(60)	

How to cite this article: Ying-Ching L, Ting-Wei C, Chun-Ting C, Ko Ting C, Po Chuan H. A Safe and Effective Minimal Invasive Surgery for Ruptured Anterior Circulation Aneurysm. Open Access J Neurol Neurosurg 2020; 14(2): 555883.DOI: 10.19080/OAJNN.2020.14.555883

Length of stay, intraoperative blood loss, and complications

The mean length of stay from admission to discharge was 23.5 days (range, 6-60 days) for the transciliary supraorbital keyhole group, which included one patient who insisted for rehabilitation program in the hospital due to personal convenience (Table 3). For the pterional craniotomy group, the mean length of stay was 28.91 days, ranging from 13 to 164 days. The two groups showed no significant difference.

However, the significant higher amounts of intraoperative blood loss in pterional approach with comparison to transciliary supraorbital keyhole group (166ml vs. 639ml, p = 0.005). No complications of cerebrospinal fluid leakage or wound infection were observed in both groups.

CSF drainage and shunt dependent

The indication of External Ventricle Drainage (EVD) for surgical clipping is pre-op hydrocephalus. We performed EVD insertion on every patient with hydrocephalus in both groups. However, lumbar drainage will be performed on patients without hydrocephalus in keyhole group (n=5), because the brain relaxation is more important in minimal invasive cranial surgery. However, there were no significant differences between two groups. With regarding to shunt dependent rate, there were no significant difference between keyhole and peterional group (40% vs 43.5%, p=0.853).

Postoperative outcomes and complications

For the transciliary supraorbital keyhole group, there was no direct mortality from the surgery, and only 3 patients suffered from significant morbidity due to severe vasospasm confirmed by DSA. The other 7 patients were classified as good recovery with favorable outcome (mRS ≤ 3) (Table 3). For the pterional craniotomy group, there were 6 patients who suffered from unfavorable outcome. one of these patients died 14 days after right MCA aneurysm clipping due to right MCA large infarction. In summary, there were no significant differences in postoperative outcomes and complications between these two groups (table 3).

Discussion

Intraoperative risk

The risk of intraoperative rupture was a nightmare for all neurosurgeons while surgical clipping. Proximal control is a very important point for surgical dissection of ruptured aneurysm. Through transciliary supraorbital keyhole craniotomy, we could approach to internal carotid artery easily through frontal base approach. Concurrently, A1 and M1 also could be identified. Consequently, proximal control could be easily achieved by transciliary supraorbital keyhole craniotomy. During the surgical dissection of a 2.78 mm A-com aneurysm, an inadvertent premature rupture occurred, increasing the amount of bleeding during the operation and decreased accessibility to the aneurysm. Post operation image showed compromised right A1. Fortunately, there was still enough collateral perfusion, so it didn't cause any major neurologic deficits.

Most neurosurgeons are still concerned about the clear surgical view of aneurysm neck and dome. The key point is brain relaxation by CSF drainage. Therefore, we chose those cases of lower Fisher grade and Hunt and Hess grade. If hydrocephalus is found by preoperative CT, external ventricular drainage will be done in the meanwhile. If no hydrocephalus is found, lumbar drainage will be performed. Under slow and gentle dissection, aneurysm neck and dome could be clearly identified through transciliary supraorbital keyhole approach.

The less invasiveness of a transciliary supraorbital keyhole approach was definitely ascertained in the present study with comparison to pterional approach. Consequently, less blood loss, and no intra-operative blood transfusion were thought as the significant advantages of the transciliary supraorbital keyhole approach. In the previous literatures, Le Roux et al. [13] reported a 13.2% and 27.2% incidence of blood transfusion during surgery for unruptured and ruptured aneurysms, respectively, when using a conventional approach. In our study, there were no cases who received blood transfusion during operation in transciliary supraorbital keyhole approach group.

Surgical outcomes

For the patients who survived from ruptured aneurysm and who were cured by surgical clipping, most of them were still under risk of disease-related complications such as pulmonary edema, stunned cardiac myopathy, vasospasm, and hydrocephalus. Such complications might cause mortality and morbidity. In our study, there was no statistical significance between these two groups. For vasospasm, the incidence and severity may be related with the amount of SAH (Fisher grade). Because these two groups were limited to lower Fisher grade, the complication of vasospasm is similar. For hydrocephalus, due to similar SAH amount in the two groups, the same incidence is expected. According to previous study, open lamina terminalis during operation or not is correlated with the possibility of hydrocephalus. Consequently, hydrocephalus or not depends on fenestration of lamina terminalis, and not on approach types.

When it comes to the comparison of the length of stay between the two groups, it was surprising that there is no significant difference. (28.91 days for pterional craniotomy group; 23.5 days for transciliary supraorbital keyhole group, P=0.612). It might be explained that most SAH patients' outcome was dependent on the initial Glasgow Coma Scale (GCS) when it happened. Additionally, for the patients who survived from ruptured aneurysm and were cured by the clipping operation, most of them were still treated for prevention of other disease-related complications such as pulmonary edema, stunned cardiac myopathy, and vasospasm.

How to cite this article: Ying-Ching L, Ting-Wei C, Chun-Ting C, Ko Ting C, Po Chuan H. A Safe and Effective Minimal Invasive Surgery for Ruptured Anterior Circulation Aneurysm. Open Access J Neurol Neurosurg 2020; 14(2): 555883.DOI: 10.19080/OAJNN.2020.14.555883

However, the risk of these complications was dependent on the Hunt-Hess grade. In our study, the H-H grade between the two groups was not significantly different.

Long-term outcome

In a meta-analysis by Raaymakers et al. [14] including 61 studies published from 1966 to 1996 involving 2,460 patients with unruptured aneurysms, the mortality and permanent major morbidity related to the surgical clipping of non-giant anterior circulation aneurysms was 0.8% and 1.9%, respectively. In addition, the historical control group in the present study showed a 1.1% mortality and 2.2% permanent major morbidity. Our study demonstrates excellent surgical outcomes when using a transciliary supraorbital keyhole approach for ruptured anterior circulation aneurysm. Complete surgical clipping without residual neck was achieved by this approach. Besides, most patients did not experience trivial deficits, such as olfactory dysfunction, and transient palsy of the frontalis muscle, except 3 patients experienced vasospasm induced disability which was disease related. In the two groups, no significant difference of mortality and morbidity was found during follow-up (30% vs. 26.1%). The mRS during follow up between these two groups showed no significant difference(P=0.817). Therefore, transciliary supraorbital keyhole craniotomy is an alternative option for surgical clipping.

Palsy of the frontalis muscle is related to an injury of the frontal branch of the facial nerve. In a report by Perneczky and colleagues,[15] permanent palsy of the frontalis was observed in 5.5% of operated cases when using a transciliary supraorbital keyhole approach, whereas the cases (5.9%) of significant palsy of the frontalis in the present series showed considerable resolution of the palsy within 2 years after the operation. Such an injury seems to develop because of traction of the frontal branch of the facial nerve, which courses just above the skin incision. This is the reason why the authors always placed the limited skin incision in the upper eyebrow instead of in the frontal wrinkle. In our study, none of patient had the palsy of the frontalis muscle. Although there is no significant effect on the mRS between these two groups, this still can't move our eye away from the fascinating merits of the transciliary supraorbital keyhole craniotomy. These patients had tremendous benefits acquired from less skin incision, less craniotomy, less blood loss, and less chance for intraoperative blood transfusion. Furthermore, patients with better cosmetic will get higher spirits. We also believe less risks of wound infection to the keyhole surgery patients, despite the limited numbers of patients for significant outcome.

Surgical consideration

Through our experiences of keyhole approach for ruptured aneurysm, the better indications for keyhole surgery is aneurysms located at the A-com, especial for the anterior-inferior projection A-com aneurysm, which provided more space for mobilization, manipulation and a good angle for the clip. In contrary, superior projection A-com aneurysm might bear some challenges due to the difficulty in visualizing the contralateral A2 if approaching from the dominated A1 side. Second, MCA aneurysms from M1 to MCA bifurcation could equally surgical clipping by two minimal invasive surgery (transciliary supraorbital keyhole approach and mini-pterional approach) depends on surgeons' preference. However, P-com aneurysms is also suitable for keyhole approach in selected cases, because the anterior clinoid process might obscure the dissection of aneurysm dome and neck. In addition, keyhole approach was not suggested for aneurysm size ≥ 10mm, because it probably needs multiple different corridors or clipping angles to secure whole aneurysm. Finally, the severity of the SAH (ex. the fisher grade) is not a risk factor for keyhole approach. Once brain relaxation by CSF drainage, surgical view will be enough for surgical clipping.

Conclusion

The safety and efficacy for transciliary supraorbital keyhole craniotomy for surgical clipping of ruptured anterior circulation aneurysm including of A-com, MCA bifurcation and the P-com aneurysm were clearly identified. It provides not only excellent cosmetic appearance, but also the complete clipping rate. Consequently, transciliary supraorbital keyhole approach can be an alternative option for the ruptured anterior circulation aneurysm if we selected the patients with a stick criteria and strategy.

Conflict of Interest

This study was supported by this project (CMRPG3H1141). The authors declare that the article content was composed in the absence of any commercial or financial relationships that could be construed as a potential conflict of interest.

References

1. Park J, Woo H, Kang DH, Sung JK, Kim Y (2011) Superciliary keyhole approach for small unruptured aneurysms in anterior cerebral circulation. Neurosurgery 68(SUPPL 2): 300-309.
2. Lan Q, Gong Z, Kang D, Zhang H, Qian Z, et al. (2006) Microsurgical experience with keyhole operations on intracranial aneurysms. Surg Neurol 66(SUPPL. 1): S2-9.
3. Mitchell P, Vindlacheruvu RR, Mahmood K, Ashpole RD, Grivas A, et al. (2005) Supraorbital eyebrow minicraniotomy for anterior circulation aneurysms. Surg Neurol 63(1): 47-51.
4. Paladino J, Mrak G, Mikliç P, Jednacak H, Mihaljevic D (2005) The keyhole concept in aneurysm surgery - A comparative study: Keyhole versus standard craniotomy. Minim Invasive Neurosurg 48(5): 251-258.
5. Ramos-Zúñiga R, Velázquez H, Barajas MA, López R, Sánchez E, et al. (2002) Trans-supraorbital approach to supratentorial aneurysms. Neurosurgery 51(1): 125-131.
6. Shin D, Park J (2012) Unruptured supraclinoid internal carotid artery aneurysm surgery: Superciliary keyhole approach versus pterional approach. J Korean Neurosurg Soc 52(4): 306-311.
7. Van Lindert E, Perneczky A, Fries G, Pierangeli E (1998) The supraorbital keyhole approach to supratentorial aneurysms: Concept and technique. Surg Neurol 49(5): 481-490.

How to cite this article: Ying-Ching L, Ting-Wei C, Chun-Ting C, Ko Ting C, Po Chuan H. A Safe and Effective Minimal Invasive Surgery for Ruptured Anterior Circulation Aneurysm. Open Access J Neurol Neurosurg 2020; 14(2): 555883.DOI: 10.19080/OAJNN.2020.14.555883

8. Park J (2014) Superciliary keyhole approach for unruptured anterior circulation aneurysms : Surgical technique, indications, and contraindications. J Korean Neurosurg Soc 56(5): 371-374.

9. Choi YJ, Son W, Park KS, Park J (2016) Intradural procedural time to assess technical difficulty of superciliary keyhole and pterional approaches for unruptured middle cerebral artery aneurysms. J Korean Neurosurg Soc 59(6): 564-569.

10. Park J, Kang DH, Chun BY (2011) Superciliary keyhole surgery for unruptured posterior communicating artery aneurysms with oculomotor nerve palsy: Maximizing symptomatic resolution and minimizing surgical invasiveness. J Neurosurg. 2011;115(4): 700-706.

11. Park J (2009) Self-drilling anchor screws for dural tenting sutures. Technical note. Surg Neurol 72(2): 175-176.

12. Kudur MH, Pai SB, Sripathi H, Prabhu S (2009) Sutures and suturing techniques in skin closure. Indian J Dermatol Venereol Leprol 75(4): 425-434.

13. Le Roux PD, Elliott JP, Winn HR (2001) Blood transfusion during aneurysm surgery. Neurosurgery 49(5): 1068-1074.

14. Raaymakers TWM, Rinkel GJE, Limburg M, Algra A (1998) Mortality and morbidity of surgery for unruptured intracranial aneurysms: A meta-analysis. Stroke 29(8): 1531-1538.

15. Reisch R, Perneczky A (2005) Ten-year experience with the supraorbital subfrontal approach through an eyebrow skin incision. Neurosurgery 57(4 Suppl): 242-255.

DOI: 10.19080/OAJNN.2020.14.555883

How to cite this article: Ying-Ching L, Ting-Wei C, Chun-Ting C, Ko Ting C, Po Chuan H. A Safe and Effective Minimal Invasive Surgery for Ruptured Anterior Circulation Aneurysm. Open Access J Neurol Neurosurg 2020; 14(2): 555883.DOI: 10.19080/OAJNN.2020.14.555883