

Managing Multiple Arteries During Renal Transplantation: A Challenging Case Report and Review of Literature



Ashish Chaurasia*, Shailesh Raina and Sheetal Mistry

Department of urology, Jaslok Hospital and Research Centre, India

Submission: June 26, 2018; **Published:** July 10, 2018

***Corresponding author:** Ashish Chaurasia, Department of urology, Jaslok Hospital and Research Centre, India, Tel: +919653668153; +918547314759; Email: dr.ashishchaurasia@gmail.com

Abstract

Introduction: Renal transplantation is a continuously evolving field in terms of surgical technique and protocols in organ sharing and distribution. Anastomosing kidneys with multiple renal arteries are always considered a surgical challenge. The kidney allografts that were previously considered to be unsuitable because of complex vascular anatomy are now getting accepted for donation.

Case Report: A 30 years old lady presented with chronic kidney disease detected 4 months back. As a pre-operative work-up of the donor, computed tomography (CT) angiogram revealed 3 arteries and a single vein on the left side. As the differential function of the right kidney was significantly better than the left (56.5% vs 43.5%), it was decided to take the left kidney for donor nephrectomy. One of the two arteries at the hilum was anastomosed in end- to- end fashion to the right internal iliac artery. Second hilar artery and the lower polar artery were anastomosed end- to-side to the right external iliac artery. Perfusion of the kidney and patency of all the anastomoses were confirmed by color doppler studies at regular intervals in post-operative period. Serum creatinine gradually became in the normal range. Post operative period was uneventful.

Discussion: In developing countries like India, there is a severe shortage of compatible kidneys in comparison to the number of chronic kidney disease patients awaiting transplantation. With this report we need to emphasize that presence of multiple vessels should not be considered a contraindication for transplantation.

Keywords: Multiple renal arteries; Renal transplantation

Abbreviations: CT: Computed Tomography; MRA: Multiple Renal Arteries; GFR: Glomerular Filtration Rate; MDCT: Multi-Detector Row Computed Tomography; DSA: Digital Subtraction Angiography; TRAT: Transplant Renal Artery Thrombosis

Introduction

Renal transplantation is the treatment of choice for patients with chronic renal insufficiency because it provides better quality of life and extended life expectancy compared to dialysis[1]. Since the first human renal transplantation performed in 1954 by Joseph Murray [2], survival rates for renal transplants' patients have improved over the years owing to significant development in surgical expertise and immunosuppressive treatments.

A single renal artery is present in only about 70% of patients, two renal arteries in 25% and three renal arteries in 2.6% [3-5]. The accessory renal artery is defined as the artery that has a separate aortic ostium from the main renal artery and supply to the upper or lower pole. The aberrant renal artery is defined as the artery that has a separate aortic origin but goes into the renal hilum.

Because of the relatively limited donor availability in comparison to the large number of patients with end stage renal disease, kidney allografts that were previously considered to be unsuitable for transplantation are now accepted for donation. One of these challenges is the engraftment of kidneys with multiple renal arteries(MRA).However, many studies have shown similar results and grafts survival with multiple vessels versus single vessel [6-8].

Case Report

A 30 years old lady presented to us with chronic kidney disease detected 4 months back. The underlying disease was hypertensive nephrosclerosis diagnosed on renal biopsy. Live related donor renal transplantation was planned. The donor was her mother. As a pre-operative work-up, computed tomographic

(CT) angiogram and urogram was done for the donor. CT angiogram revealed a single renal artery and vein on right side. However, there were 3 arteries and a single vein on the left side (Figure 1). Radioisotope renogram study showed GFR (glomerular filtration rate) of 34.74ml/ min (Relative function= 43.5%) on left side and 45.14ml/min (Relative function= 56.5%) on right side. Rest of the study was unremarkable.

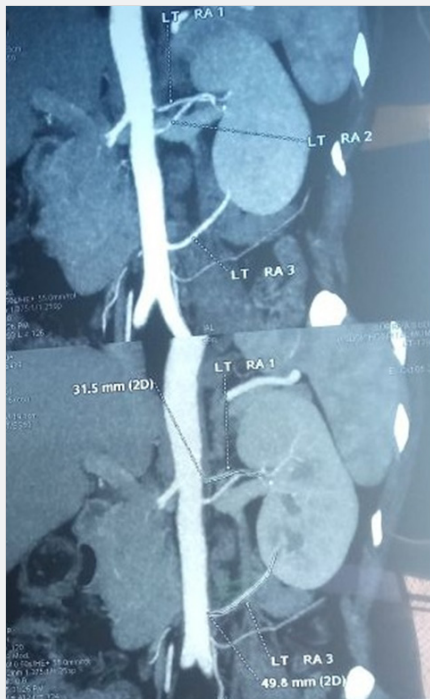


Figure 1: Computed tomography Angiogram- Reconstructed images showing 3 left renal arteries. Two arteries are supplying at the hilum of the left kidney. Third artery is supplying at lower pole of kidney.

As the differential function of the right kidney was significantly better than the left, it was decided to take the left kidney for donor nephrectomy. Taking a kidney with three arteries for anastomosis was a surgical challenge owing to relatively smaller caliber of all the three arteries and especially when all three of them were equally important for the survival of the graft. As can be seen in the CT reconstruction images that two arteries are supplying at the hilum of the left kidney. Third artery is at lower pole which despite being of lower caliber and supplying relatively insignificant portion at lower pole of the kidney cannot be sacrificed as it also supplies the adjacent ureter.

We proceeded with the planned renal transplantation. Left donor nephrectomy was done and kidney was placed in the right iliac fossa of the recipient after cooling. One of the two arteries at the hilum was anastomosed in end- to- end fashion to the right internal iliac artery. Second hilar artery and the lower polar artery were anastomosed end- to-side to the right external iliac artery (Figures 2). Renal vein was anastomosed end- to- side to external iliac vein. All the anastomoses were done with prolene

7-0. Warm ischemia time was 6 min and cold ischemia time was 2 hours and 20 minutes.

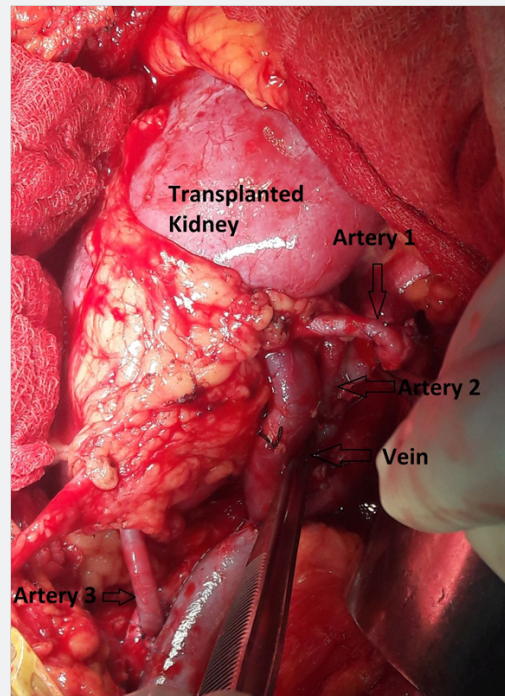


Figure 2: One of the two arteries (Artery 1) at the hilum was anastomosed in end- to- end fashion to the right internal iliac artery. Second hilar artery (Artery 2) and the lower polar artery (Artery 3) were anastomosed end- to-side to the right external iliac artery. Renal vein was anastomosed end- to- side to external iliac vein.

All parts of the transplanted kidney were well vascularized and turgid after releasing of clamps. Ureteroneocystostomy was performed by Lich- Gregoir technique. Perfusion of the kidney and patency of all the anastomoses were confirmed by color doppler studies at regular intervals in post-operative period. Serum creatinine gradually became in the normal range. Post operative period was uneventful. The patient is under regular follow up.

Review of Literature

The advent of multi-detector row computed tomography (MDCT) enables comprehensive evaluation of the renal vasculature and has replaced conventional digital subtraction angiography (DSA). The variations of renal vasculature can be well assessed by MDCT prior to surgery, which can provide accurate information to guide renal transplantation surgery [9-11]. The accuracy of MDCT for detection of renal vasculature anomalies ranged from 96% to 100% [3,11-15].

In cases of multiple renal arteries, different techniques of in situ intracorporeal or more recently ex-vivo microvascular anastomotic techniques have been devised over the years, to anastomose multiple renal arteries. In situ techniques include the use of the recipient hypogastric artery, a combination of hypogastric and external iliac arteries, multiple individual

end-to-side anastomoses to the external iliac artery and the inferior epigastric artery [16,17]. On the other hand, the main objective of ex-vivo microvascular techniques, as popularized by Novick, is to create a single arterial ostium to facilitate vascular anastomosis in situ with maximal accuracy and minimal warm ischemic damage to the kidney [18]. Ioannis M et al. [19] had used inferior epigastric artery for revascularization in multiple renal arteries and found it to be safe and effective [19].

Major vascular complications during renal transplantations include renal graft artery thrombosis or stenosis, graft vein thrombosis, and less frequent events are aneurysms, hematomas, and arterio-venous fistulae. Transplant renal artery stenosis is known to be the most common vascular complication (75%) in renal transplantation with a prevalence ranging from 1% to 23% [20-23]. Transplant renal artery thrombosis (TRAT) has been reported in 0.5% to 3.5% of recipients [24], and it is a major cause of graft loss in the early post-transplantation period. Dimitroulis et al. [25] had reported major vascular complications in 4.2% (57 out of 1367) of renal transplant recipients [25]. Out of them, transplant artery thrombosis was found in 47.4% patients, transplant vein thrombosis in 7%, aneurysm in 7% and uncontrolled post-operative bleeding in 5.3%. Transplant artery stenosis was reported as a late complication among 33.3% of major vascular complications [25].

Discussion

Renal transplantation carried a low (but clinically significant) risk for vascular complications that can lead to allograft loss. It is essential to interpret CT Angiography accurately prior to transplant surgery and identify renal artery anomalies during surgical dissection. The surgical safety should be analyzed on every individual case within the transplant unit.

In India, we face an organ shortage like many other countries. The number of transplantations may increase if we consider MRA grafts to be as good as single-artery grafts. With this report, we concluded that the presence of multiple vessels was not a contraindication for renal transplantation.

Ethical Approval

All procedures performed in the study were in accordance with the ethical standards of the institutional and national research committee and with the 1964 Helsinki declaration and its later amendments or comparable ethical standards.

References

1. Shirali AC, Bia MJ (2008) Management of cardiovascular disease in renal transplant recipients. *Clin J Am Soc Nephrol* 3: 491-504.
2. Merrill JP, Murray JE, Harrison JH, Guild WR (1956) Successful homotransplantation of the human kidney between identical twins. *JAMA* 160(4): 277-282.
3. Chai JW, Lee W, Yin YH, Jae HJ, Chung JW, et al. (2008) CT angiography for living kidney donors: accuracy, cause of misinterpretation and prevalence of variation. *Korean J Radiol* 9(4): 333-339.

4. Patil UD, Ragavan A, Nadaraj, Murthy K, Shankar R, et al. (2001) Helical CT angiography in evaluation of live kidney donors. *Nephrol Dial Transplant* 16(9): 1900-1904.
5. Pozniak MA, Balison DJ, Lee FT, Tambeaux RH, Uehling DT, et al. (1998) CT angiography of potential renal transplant donors. *Radiographics* 18(3): 565-587.
6. Cagatay A, Ibrahim B, Gulum A, Yigit B, Titiz I (1995) The outcome of kidney transplants with multiple renal arteries. *Ann Surg* 4: 4.
7. Basaran O, Moray G, Emiroglu R, Alevli F, Haberal M (2004) Graft and patient outcomes among recipients of renal grafts with multiple arteries. *Transplant Proc* 36(1): 102-104.
8. Gawish AE, Donia F, Samhan M, Halim MA, Al-Mousawi M (2007) Outcome of renal allografts with multiple arteries. *Transplant Proc* 39(4): 1116-1117.
9. Namasivayam S, Kalra MK, Waldrop SM, Mittal PK, Small WC (2006) Multidetector row CT angiography of living related renal donors: is there a need for venous phase imaging? *Eur J Radiol* 59(3): 442-452.
10. Rydberg J, Kopecky KK, Tann M, Persohn SA, Leapman SB, et al. (2001) Evaluation of prospective living renal donors for laparoscopic nephrectomy with multisection CT: the marriage of minimally invasive imaging with minimally invasive surgery. *Radiographics* 21 (Suppl 1): S223-236.
11. Kawamoto S, Montgomery RA, Lawler LP, Horton KM, Fishman EK (2004) Multi-detector row CT evaluation of living renal donors prior to laparoscopic nephrectomy. *Radiographics* 24(2): 453-466.
12. Kim JK, Park SY, Kim HJ, Kim CS, Ahn HJ, et al. (2003) Living donor kidneys: usefulness of multi-detector row CT for comprehensive evaluation. *Radiology* 229(3): 869-876.
13. Urban BA, Ratner LE, Fishman EK (2001) Three-dimensional volume-rendered CT angiography of the renal arteries and veins: normal anatomy, variants, and clinical applications. *Radiographics* 21(2): 373-86; questionnaire 549-555.
14. Turkvatan A, Ozdemir M, Cumhuri T, Olcer T (2009) Multidetector CT angiography of renal vasculature: normal anatomy and variants. *Eur Radiol* 19(1): 236-244.
15. Schlunt LB, Harper JD, Broome DR, Baron PW, Watkins GE, et al. (2007) Improved detection of renal vascular anatomy using multidetector CT angiography: is 100% detection possible? *J Endourol* 21(1): 12-17.
16. Benedetti E, Troppmann C, Gillingham K, Sutherland DE, Payne WD, et al. (1995) Short- and long-term outcomes of kidney transplants with multiple renal arteries. *Ann Surgery* 221(4): 406-414.
17. Han D, Choi S, Kim S (1998) Microsurgical reconstruction of multiple arteries in renal transplantation. *Transplant Proc* 30(7): 3004-3005.
18. Novick AC (1984) Microvascular reconstruction of complex branch renal artery disease. *Urol Clin North Am* 11(3): 465-475.
19. Antonopoulos IM, Yamacake KGR, Oliveira LM, Piovesan AC, Kanashiro H, et al. (2014) Revascularization of living-donor kidney transplant with multiple arteries: long-term outcomes using the inferior epigastric artery. *Urology* 84(4): 955-959.
20. Fernandez ALG, Zudaire JJ, Isa WA, de la Muela SPL, Rosell D, de Castro F, et al. (1992) Vascular complications in 237 recipients of renal transplant from cadaver. *Actas Urol Esp* 16(4): 292-295.
21. Fervenza FC, Lafayette RA, Alfrey EJ, Petersen J (1998) Renal artery stenosis in kidney transplant. *Am J Kidney Dis* 31(1): 142-148.
22. Filho ZM, Furtado PS, Barroso U, Pugas CM, D'Avila C, Souza GF (2005) Kidney transplantation in children: a 50-case experience. *Int Braz J Urol* 31(6): 558-561.

23. Mazzucchi E, Souza AA, Nahas WC, Antonopoulos IM, Piovesan AC, et al. (2005) Surgical complications after renal transplantation in grafts with multiple arteries. *Int Braz J Urol* 31(2): 125-130.
24. Rouviere O, Berger P, Beziat C, Garnier JL, Lefrançois N, et al. (2002) Acute thrombosis of renal artery: graft salvage by means of intra-arterial fibrinolysis. *Transplantation* 73(3): 403-409.
25. Dimitroulis D, Bokos J, Zavos G, Nikiteas N, Karidis NP, et al. (2009) Vascular Complications in Renal Transplantation: A Single-Center Experience in 1367 Renal Transplantations and Review of the Literature. *Trans Proc* 41(5): 1609-1614.



This work is licensed under Creative Commons Attribution 4.0 License
DOI: [10.19080/JOJUN.2018.05.555673](https://doi.org/10.19080/JOJUN.2018.05.555673)

**Your next submission with Juniper Publishers
will reach you the below assets**

- Quality Editorial service
- Swift Peer Review
- Reprints availability
- E-prints Service
- Manuscript Podcast for convenient understanding
- Global attainment for your research
- Manuscript accessibility in different formats
(Pdf, E-pub, Full Text, Audio)
- Unceasing customer service

Track the below URL for one-step submission

<https://juniperpublishers.com/online-submission.php>