JOJ Ophthalmology
ISSN: 2473-5477

Juniper Publishers
key to the Researchers

Case Report
Volume 12 Issue 3 - April 2025
DOI: 10.19080/JOJO.2025.12.555840

JOJ Ophthalmol
Copyright © All rights are reserved by Okechukwu Clinton Ifeanyi

A Case of Anterior Staphyloma Secondary to Corneal Chemical Injury

Okechukwu Clinton Ifeanyi* and Daniel Ayodele Femi

University of Benin, Edo, Nigeria

Submission: February 28, 2025; **Published:** April 04, 2025

***Corresponding author**: Okechukwu Clinton Ifeanyi, University of Benin, Edo, Nigeria

Abstract

Anterior staphyloma is a severe ocular complication resulting from corneal thinning and perforation due to trauma, infection, or chemical injury. Alkali burns, in particular, cause rapid and extensive corneal damage, leading to complications such as stromal necrosis and ectasia. This case report details a 37-year-old male who developed anterior staphyloma secondary to an alkali-induced corneal injury. Despite initial medical management, the patient experienced worsening symptoms due to delayed intervention and the use of traditional remedies, ultimately resulting in corneal perforation and uveal prolapse. Advanced surgical interventions, such as tectonic grafting or evisceration, may be necessary in severe cases. This case highlights the critical importance of early intervention, patient education, and adherence to medical treatment to mitigate vision-threatening outcomes in chemical eye injuries.

Keywords: Anterior Staphyloma; Corneal Chemical Injury; Alkali Burn; Ocular Trauma; Vision Loss

Introduction

Anterior staphyloma is a severe ocular complication characterized by the protrusion of uveal tissue through a structurally compromised cornea. It often results from progressive corneal thinning and perforation due to infections, trauma, or chemical injuries [1]. Among these causes, chemical burns, particularly alkali injuries, pose a significant risk due to their rapid penetration and sustained damage to ocular tissues. Alkali agents, such as ammonia and lime, can cause extensive corneal opacification, stromal necrosis, and eventual ectasia, leading to complications like anterior staphyloma [2].

Managing anterior staphyloma requires a multidisciplinary approach, including medical therapy to control inflammation and surgical intervention to restore ocular integrity [3]. Tectonic grafting may be necessary to prevent further complications, including phthisis bulbi, in cases of severe corneal damage. This report presents a case of anterior staphyloma secondary to an alkali burn, emphasizing the need for early intervention and preventive measures to mitigate vision-threatening outcomes.

Case Report

Initial Visit (19/06/2024)

A 37-year-old African man was referred to the clinic for an eye examination after an occupational hazardous incident. The right eye was exposed to alkali chemicals, he reported that the incident occurred five days ago and he was currently experiencing slight pains, with no photophobia. His last eye examination was four days ago (15/06/2024) where he was placed on Nepafenac (a nonsteroidal anti-inflammatory drug used to treat pain and inflammation) and Ciprofloxacin (belonging to the group of medicines called fluoroquinolone antibiotics) and currently using three times a day.

His ocular history revealed no previous ocular traumas and use of spectacle glasses. The family ocular history was negative. The patient's medical history was also negative. No current medications excluding the recently purchased eye drops were reported. Social history was negative for tobacco, alcohol, or recreational drug use. He had no known systemic medication allergies. He was oriented to person, place, and time, and her mood was appropriate.

His entry visual acuity was counting fingers at one meter on the right eye and 6/18-1 on his left eye. Slit lamp biomicroscopy revealed normal adnexa, lashes, and puncta on both eyes but a hyperemic conjunctiva on the right eye. The right cornea on examination revealed epithelial loss and stromal haze with hypopyon at the base of the cornea. The Internal examination had a poor view of the details due to the stromal haze.

The differential diagnoses considered at this time of the examination included:

- Corneal Chemical Injury
- Sterile Endopthalmitis

A. **Corneal Chemical Injury**

This is the primary suspected diagnosis due to the patient's reported direct exposure to an acidic substance at work, leading to significant ocular damage. Despite the incident occurring five days ago, he is now experiencing worsening symptoms, indicating a delayed presentation. Slit lamp examination revealed notable ocular surface findings, including epithelial loss, stromal haze, and conjunctival hyperemia, all characteristic of corneal chemical burns. Additionally, the presence of inflammatory cells in the anterior chamber (hypopyon) suggests severe corneal damage and an active inflammatory response. The internal examination was limited due to a poor fundus view, likely caused by corneal opacity from the stromal haze, a common consequence of chemical burns.

B. **Sterile Endophthalmitis**

This is a secondary consideration because the presence of hypopyon suggests intraocular inflammation, likely caused by toxins released from damaged corneal tissues. Notably, the patient does not report severe pain or photophobia, which are hallmark symptoms of infectious endophthalmitis. Instead, the presentation aligns more with sterile endophthalmitis, a non-infectious inflammatory response that can occur after chemical burns. Additionally, the patient's recent use of Ciprofloxacin and Nepafenac may have contributed to controlling infection and inflammation, further reducing the likelihood of an infectious cause (Figure 1).

Figure 1: The patient was counseled on the guarded prognosis and the following eye drops were prescribed after thorough irrigation The patient was asked to come back in a week.

The patient was counseled on the guarded prognosis and the following eye drops were prescribed after thorough irrigation The patient was asked to come back in a week

- Gutt Ivymoicell i RE hrly (An artificial tears)
- Gutt Nepafenac i RE Qds
- Gutt Moxifloxacin i RE 2hrly
- Occ Betamethasone RE nocte
- Occ Hypomer gel RE Tds
- Tab Vitamin C 1g daily * 1/52
- Tab Doxycycline 100mg Bd * 2/52
- Tab Diazepam 10mg daily * 1/52
- **Follow-Up Visit (25/06/2024)**

The patient returned to the clinic a week after for follow-up and evaluation, he reported no new symptoms and no pain, and the redness had reduced also. His visual acuity had improved to counting fingers at 2 meters. On examination with the slit lamp, the patient's cornea was stained using one drop of Amethocaine 0.5% eye drop on a Florescein strip to determine the extent of corneal damage and there was still a presence of large epithelial erosion, a hazy cornea, and faint iris details (Figure 2). He was still on his medications and was advised to continue and return in two weeks.

- **Follow-Up Visit (20/7/2024)**

The patient returned to the clinic after three weeks for evaluation, He had no new complaints. His visual acuity was counting fingers at 2 meters, there was a better view of the cornea and mild hyperemia. He was counseled to stop the use of diazepam and doxycycline tablets and betamethasone ointment. The patient was asked to use a bandage contact lens to aid the healing process and was asked to come during the week for fixing (Figure 3).

- **Follow Up Visit (9/11/2024)**

The patient returned to the clinic after four months with complaints of the vision worse and with redness. He denied having

How to cite this article: Okechukwu Clinton I, Daniel Ayodele F. A Case of Anterior Staphyloma Secondary to Corneal Chemical Injury. JOJ Ophthalmol. 2025; 12(3): 555840. DOI:10.19080/JOJO.2025.12.555840

kept any other thing in the eye but on further persuasion admitted to using some traditional remedies with unknown names. His acuity was light perception. On examination with the slit lamp, it showed a perforation of the cornea with the iris plugging the entire surface. There was the presence of neovascularized vessels on the cornea and no view of the lens and the posterior. The final diagnosis was Anterior Staphyloma of the right eye. The patient was counseled on the prognosis and recommended for evisceration. Gutt Moxifloxacin tds on the Right eye was prescribed in the meantime (Figure 4).

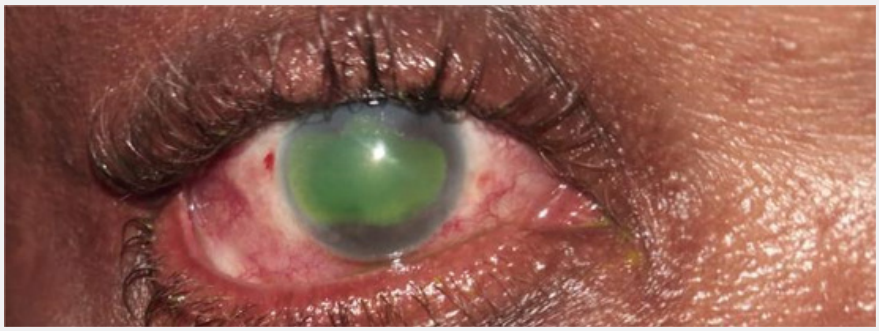

Figure 2: He was still on his medications and was advised to continue and return in two weeks.

Figure 3

Figure 4

How to cite this article: Okechukwu Clinton I, Daniel Ayodele F. A Case of Anterior Staphyloma Secondary to Corneal Chemical Injury. JOJ Ophthalmol. 2025; 12(3): 555840. DOI:10.19080/JOJO.2025.12.555840

Discussion

Chemical injuries to the eye, particularly those resulting from alkali burns, present a complex and rapidly evolving clinical challenge [4]. Alkali agents, due to their high pH, penetrate ocular tissues swiftly, causing saponification of cell membranes and liquefactive necrosis of the corneal stroma [5]. This initial insult not only disrupts the epithelial barrier but also triggers an intense inflammatory cascade that can rapidly lead to stromal degradation, thinning, and eventual perforation [6]. The case presented here illustrates this progression, as the patient experienced significant corneal damage despite early medical intervention, emphasizing the critical importance of early intervention in such cases.

In the acute phase of a chemical injury, immediate and thorough ocular irrigation is crucial to reduce the chemical load and mitigate tissue damage [7]. However, even with early decontamination and appropriate pharmacotherapy, including topical antibiotics, nonsteroidal anti-inflammatory drugs, and corticosteroids, the inflammatory process can persist [5]. The presence of hypopyon and extensive epithelial loss observed in our patient tells the severity of the injury and the challenges in halting the degenerative process once it is underway. Moreover, the use of traditional remedies later in the clinical course likely exacerbated the inflammatory response, contributing to further tissue breakdown.

As the corneal integrity deteriorates, the risk of developing anterior staphyloma increases, anterior staphyloma is characterized by the ectatic protrusion of uveal tissue through a thinned, compromised cornea [8]. This condition represents the culmination of progressive corneal thinning, where the structural framework of the cornea is so weakened that it can no longer contain the intraocular contents. The development of neovascularization in the affected cornea, as seen in this case, is a common sequela of chronic inflammation and scarring. Neovascularization reflects the eye's attempt to heal and contributes to further structural instability and can complicate any potential surgical intervention [9].

The evolution from a chemical injury to anterior staphyloma is multifactorial. Initial cellular damage and stromal necrosis set the stage for secondary inflammatory and immune-mediated responses. This cascade can be further amplified by delayed or inappropriate treatments. In our patient, the early use of Nepafenac, Ciprofloxacin, and Betamethasone was aimed at controlling inflammation and preventing infection. Nevertheless, the subsequent application of traditional remedies, whose unknown composition and effects likely introduce additional inflammatory mediators or toxins, hastening the progression toward corneal perforation and staphyloma formation [10].

From a pathophysiological standpoint, the formation of anterior staphyloma after an alkali burn involves several interrelated processes. The initial chemical injury leads to widespread cellular apoptosis and necrosis within the corneal layers. As the natural reparative mechanisms of the cornea attempt to restore the damaged tissue, there is an imbalance between collagen degradation and synthesis. The result is a disorganized stromal matrix that lacks the tensile strength required to maintain normal corneal curvature and integrity [11]. Additionally, chronic inflammation promotes fibrovascular proliferation, which, while intended to provide nutritional support to the injured area, inadvertently facilitates further weakening of the corneal structure [9].

Management of anterior staphyloma remains particularly challenging. Once the corneal architecture has been significantly compromised, conservative medical management is usually insufficient. Surgical interventions, ranging from tectonic grafting to, in severe cases, evisceration, become necessary to address the structural defects and to prevent secondary complications such as infection or sympathetic ophthalmia [5,12]. In our patient, the advanced stage of corneal damage, evidenced by a final visual acuity of light perception and extensive neovascularization mandated consideration of evisceration to manage the ocular condition effectively.

Literature on chemical eye burns emphasizes the importance of early and aggressive treatment. They have also highlighted the potential for devastating outcomes following acid and alkali burns, a view that has been reinforced by more contemporary studies [2]. Recent reviews, such as those by Bizrah and case reports like that of Lohakare, provide evidence that timely intervention can significantly alter the prognosis of chemical injuries [1,3]. These studies advocate for prompt irrigation, judicious use of anti-inflammatory agents, and close monitoring to detect early signs of complications underlining the urgency and importance of early and aggressive treatment in such cases.

Furthermore, patient education plays a crucial role in the management of chemical eye injuries. The success of initial therapy is highly dependent on adherence to prescribed treatments and the avoidance of potentially harmful alternative remedies. In this case, the deviation from evidence-based management through the use of traditional remedies likely contributed to the poor outcome. This emphasized the necessity for clear communication between the healthcare provider and the patient regarding the risks of non-compliance and the potential adverse effects of unverified treatments.

This case of anterior staphyloma secondary to an alkali burn serves as a stark reminder of the consequences of chemical ocular injuries. It illustrates the rapid progression from an acute inflammatory insult to irreversible structural damage and highlights the critical importance of early, aggressive intervention. Moreover, it emphasizes the need for comprehensive patient

How to cite this article: Okechukwu Clinton I, Daniel Ayodele F. A Case of Anterior Staphyloma Secondary to Corneal Chemical Injury. JOJ Ophthalmol. 2025; 12(3): 555840. DOI:10.19080/JOJO.2025.12.555840

education to prevent the use of alternative therapies that may exacerbate the condition. Future strategies should focus on refining early treatment protocols and developing advanced surgical techniques to better manage these challenging cases, ultimately aiming to preserve ocular integrity and function.

Conclusion

When an anterior staphyloma is diagnosed following a corneal chemical injury, it is essential that a comprehensive ocular evaluation be performed, including detailed slit lamp biomicroscopy and adjunctive imaging, to assess for complications such as neovascularization, uveal prolapse, and corneal perforation. Understanding the statistical risk of these sequelae is crucial for educating patients on the importance of rigorous follow-up. Moreover, discussing the risks and benefits of surgical interventions versus conservative management is fundamental, given the profound impact such injuries have on ocular integrity, visual function, and overall quality of life.

References

1. Lohakare T, Meshram K (2022) Anterior staphyloma of right eye: a rare clinical image. Pan African Medical Journal 42(1): 189.
2. Friedenwald JS, Hughes WF, Herrmann H (1946) Acid burns of the eye. Archives of Ophthalmology 35(2): 98-108.
3. Bizrah M, Yusuf A, Ahmad S (2019) An update on chemical eye burns. Eye 33(9): 1362-1377.
4. Tuft SJ, Shortt AJ (2009) Surgical rehabilitation following severe ocular burns. Eye 23(10): 1966-1971.
5. Singh P, Tyagi M, Kumar Y, Gupta KK, Sharma PD (2013) Ocular chemical injuries and their management. Oman journal of ophthalmology 6(2): 83-86.
6. Wagoner MD (1997) Chemical injuries of the eye: current concepts in pathophysiology and therapy. Survey of ophthalmology 41(4): 275-313.
7. Bunker DJ, George RJ, Kleinschmidt A, Kumar RJ, Maitz P (2014) Alkali-related ocular burns: a case series and review. Journal of Burn Care & Research 35(3): 261-268.
8. Grahn BH, Breaux C, Cullen CL (2005) Diagnostic ophthalmology. Anterior staphyloma. The Canadian Veterinary Journal 46(7): 662.
9. Chang JH, Gabison EE, Kato T, Azar DT (2001) Corneal neovascularization. Current opinion in ophthalmology 12(4): 242-249.
10. Shahriary A, Sabzevari M, Jadidi K, Yazdani F, Aghamollaei H (2022) The role of inflammatory cytokines in neovascularization of chemical ocular injury. Ocular Immunology and Inflammation 30(5):1149-1161.
11. Fini ME, Parks WC, Rinehart WB, Girard MT, Matsubara M, et al. (1996) Role of matrix metalloproteinases in failure to re-epithelialize after corneal injury. The American journal of pathology 149(4): 1287-1302.
12. Shivanna Y, Gorimanipalli B, Sanjay S (2023) Every eye needs a best chance to see: Just give it. Indian Journal of Ophthalmology 71(2): 673.

This work is licensed under Creative Commons Attribution 4.0 License
DOI: 10.19080/JOJO.2025.12.555840

Your next submission with Juniper Publishers will reach you the below assets

- Quality Editorial service
- Swift Peer Review
- Reprints availability
- E-prints Service
- Manuscript Podcast for convenient understanding
- Global attainment for your research
- Manuscript accessibility in different formats
  (Pdf, E-pub, Full Text, Audio)
- Unceasing customer service

Track the below URL for one-step submission
https://juniperpublishers.com/online-submission.php

How to cite this article: Okechukwu Clinton I, Daniel Ayodele F. A Case of Anterior Staphyloma Secondary to Corneal Chemical Injury. JOJ Ophthalmol. 2025; 12(3): 555840. DOI:10.19080/JOJO.2025.12.555840