

# Retinal Vein Occlusion Treated with QIAPI 1™: Report of a Case



**Arturo Solís Herrera\***, María del Carmen Arias, Paola Eugenia Solís Arias

Human Photosynthesis™ Research Centre, Aguascalientes 2000, México

**Submission:** November 22, 2022; **Published:** December 12, 2022

**\*Corresponding author:** Arturo Solís Herrera, Human Photosynthesis™ Research Centre, Aguascalientes 2000, México

## Abstract

Acute retinal vascular occlusions are frequent causes of visual impairment. Although both retinal artery occlusions and retinal vein occlusions are associated with increased age and cardiovascular risk factors, their pathophysiology, systemic implications, and management differ substantially. Retinal vascular events are perceived to be related to various cardiovascular complications. There is a positive association of retinal vascular events to mortality, stroke, and myocardial infarction. Retinal artery occlusion (RAO) and retinal vein occlusion (RVO) is associated with a higher risk of stroke. Given that RAO and RVO patients would generally present to ophthalmologists, their high cardiovascular risk should include a referral for cardiovascular assessment as part of their management protocol. This article reports the remarkable effects on tissues affected by retinal vascular events, when by pharmacological means, we restore the surprising ability to take energy directly from light, through the dissociation of water, as it happens in plants.

**Keywords:** Retina; Blood; Vessels; Coagulation; Glaucoma; Energy

**Abbreviations:** Rao: Retinal Artery Occlusion; RVO: Retinal Vein Occlusion; NS: Nephrotic syndrome; CAO: Cilioretinal Artery Occlusion

## Background:

Acute management of retinal artery occlusions involves a multidisciplinary approach including neurologists with stroke expertise, whereas treatment of retinal vein occlusions is provided by ophthalmologists. Optimization of systemic risk factors by patients' primary care providers is an important component of the management of these two disorders [1]. Patients with RAO had an increased risk of stroke, myocardial infarction, or death. No protective effect of antithrombotic treatment was shown [2]. The association with mortality risk was highest at ~34.7% in retinal vein occlusion (RVO) subgroup [3]. Older dementia-free patients who present with RAVO appear to be at higher risk for vascular dementia [4]. Patients with retinal artery occlusion (RAO) were significantly younger than patients with retinal vein occlusion (25.0 vs. 40.1 years,  $P = 0.023$ ). Of 14 patients, retinal vascular occlusion was the presenting sign of Moyamoya disease in 8 (57.1%) patients. Legal blindness occurred in 8 (57.1%) patients at final visits [5]. Vascular occlusion secondary to retrobulbar injection for ocular anesthesia is rare but can be vision threatening [6].

Also, combined central retinal vein and branch retinal artery occlusion in hyper-homocysteinaemia [7] Nephrotic syndrome (NS) is a common disease of childhood, but its frequent ophthalmic manifestations are seldom reported. The report of a

rare occurrence of bilateral combined central retinal artery and vein occlusion in a 3-year-old with NS, the child presented with bilateral painless loss of vision, central pallid retinae with cherry red spots, vascular tortuosity, and retinal hemorrhages. There was delayed filling of the arteriolar circulation and a delay in arteriovenous transit time on angiography and increased central retinal thickening on optical coherence tomography. She was treated with oral steroids, subcutaneous low molecular weight heparin, and oral acetylsalicylic acid [8]. Furthermore, a patient with central retinal artery occlusion (RAO) following an episode of mechanical strangulation with dismal visual prognosis has been reported [9].

A 15-year-old boy presented with unilateral blurry vision due to a central retinal vein occlusion along with other systemic symptoms. Within a 1-week period, he developed an ophthalmic artery occlusion in the same eye, with resulting bare light perception vision. Extensive evaluation by the pediatrics and rheumatology services led to a diagnosis of primary antiphospholipid syndrome as the etiology for the occlusions [10].

## Introduction

Management of retinal vascular occlusions differ notably. For instance, Retinal artery occlusion is an extremely rare diagnosis in

the pediatric population and the etiology with risk factors of retinal artery occlusion are poorly understood in younger individuals [11]. Apart from the retinal whitening, hemorrhages, exudates and box-carrying of the retinal arteries, there were characteristic triangular patches of retinal whitening in the midperipheral temporal fundus indicating a previous lateral posterior choroidal artery occlusion (Amalric sign) [12].

Usual patient's complaints are about of sudden, painless, decrease in vision, and sectoral visual field defect. And worst, in some patients the occlusions appear in the other eye few days later [13] 27 years old. female patient with antiphospholipid syndrome and bilateral retinal artery and vein occlusion, with dyspnea, dry cough, of 8 days of evolution, treated with bronchodilators, with no improvement. But in the last 24 hours, she noticed that visual field defects appear in both eyes. The patient was treated with heparin and corticoids with no visual and dyspnea improvement [14]. Also, Iatrogenic retinal artery occlusion caused by cosmetic facial filler injections has been published with poor visual outcome. All patients with ophthalmic artery occlusion had ocular pain and no improvement in best-corrected visual acuity [15].

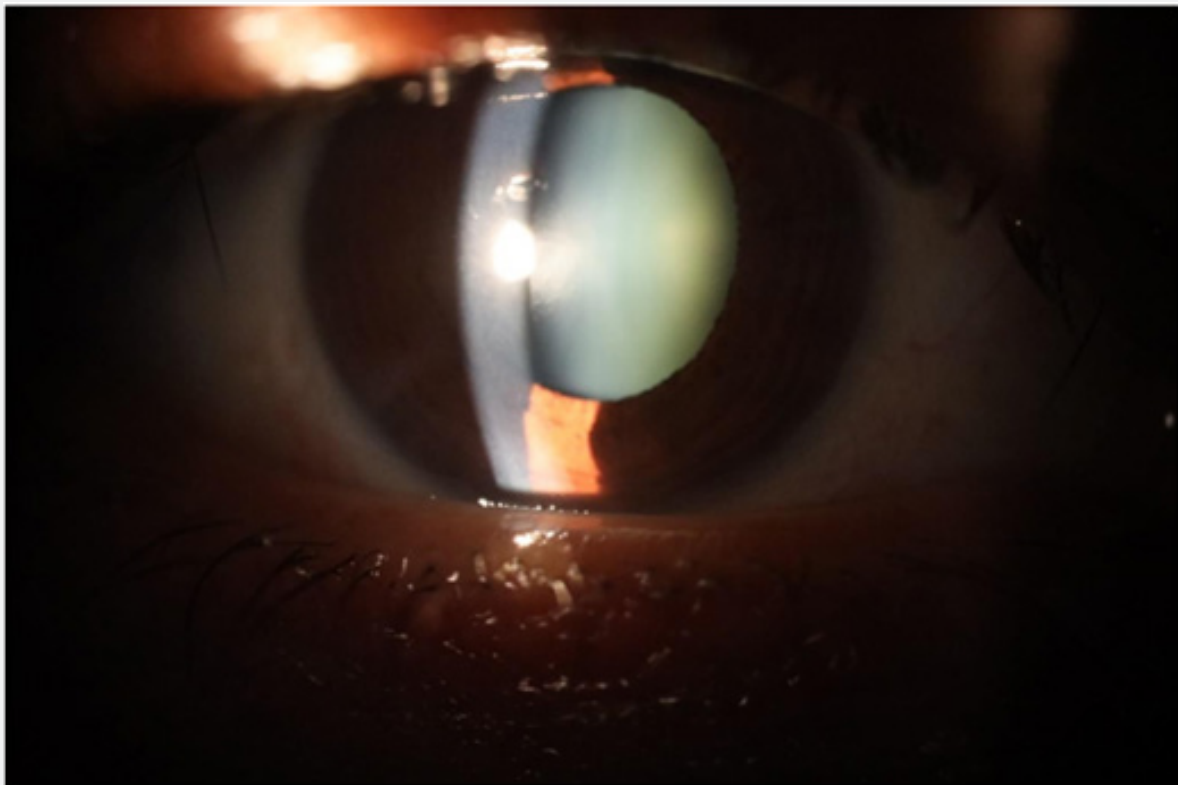
In spite diverse treatments, after occurrence of RAVO, there is a high risk of a subsequent vascular event, particularly ipsilateral stroke, within one month [16]. However, results are conflictive with other studies that shown that the rate of stroke

in patients with confirmed RAO was 2.3%; excluding concurrent ischemic events, the risk was <1%. The incidence of carotid artery stenosis >50% was 14.2%. The authors conclude that the risk of stroke after confirmed RAO is lower than previously reported and comparable to prior population-based studies of all at-risk adults [17]. The visual prognosis of cilioretinal artery occlusion (CAO) is significantly better than for other types of retinal artery occlusions, except for cases associated with giant cell arteritis [18].

### Case Report

Female patient, date of birth 03/09/1958. She is a Medicine doctor and noticed low vision in Right eye since June of 2021. She lacks breathing at night, paresthesia's. There is no history of diabetes mellitus, she only suffers from systemic arterial hypertension of several years of evolution that she controls herself by oral antihypertensives.

The oximetry on the day of the first consultation (07/21(2021) was 97%, the heart rate of 67 per minute, and the blood pressure of 155/95mm Hg. Intraocular pressure was 15mm Hg (Figures 1 to 6). The ophthalmological diagnoses were findings compatible with glaucomatous optic neuropathy (low tension glaucoma), moderate nuclear sclerosis of the right lens, and venous occlusion of the superior temporal branch of the retinal vein.



**Figure 1:** The right eye did not show gross abnormalities, maybe a little bit of nuclear sclerosis of the lens.

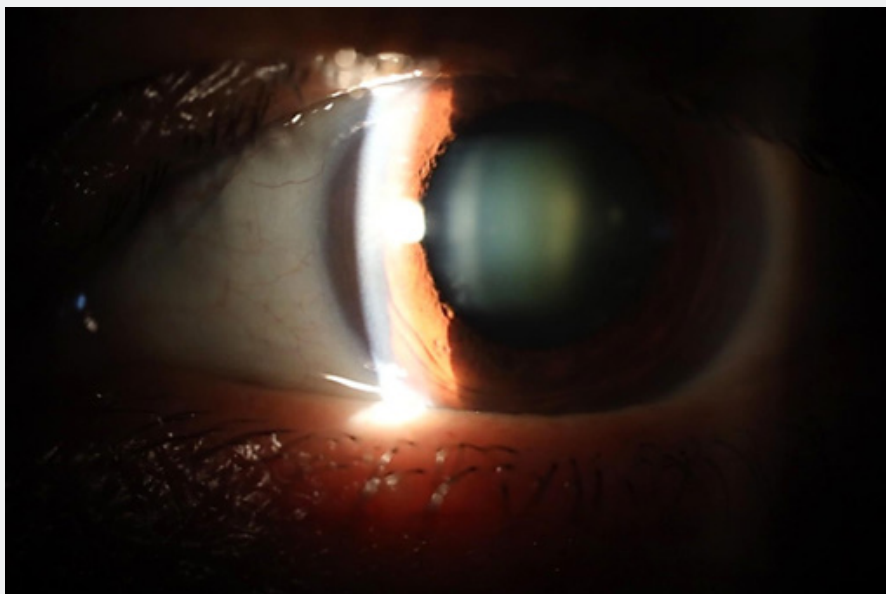

Figure 2: Examination of Left eye with biomicroscope was within normal limits.

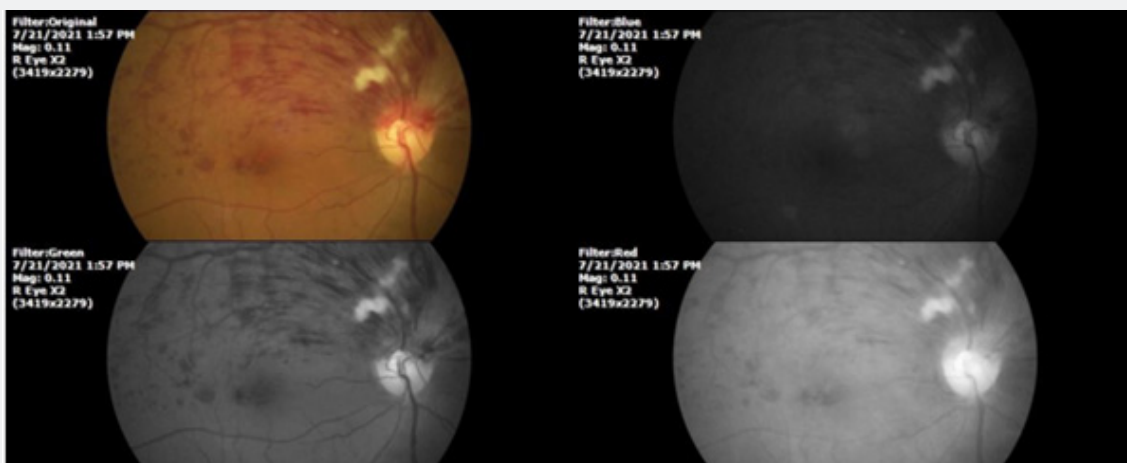


Figure 3: Right eye. Retinal vein occlusion of upper temporal branch, and increased excavation of the optical disc.

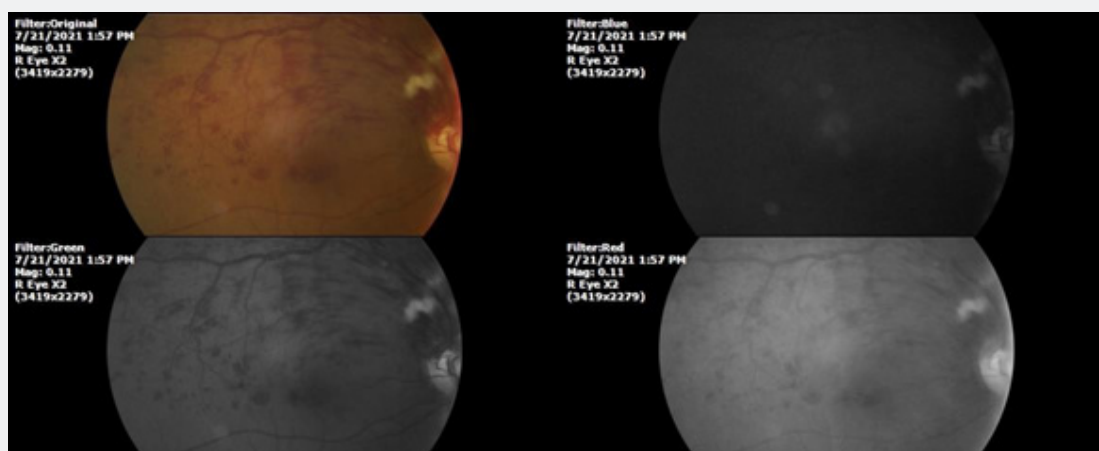
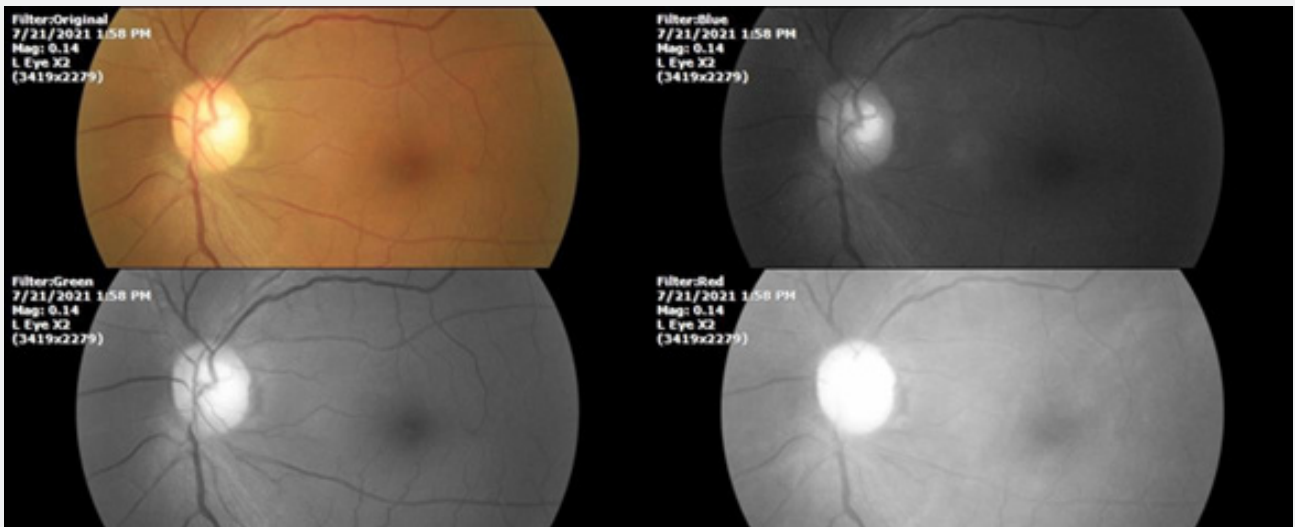
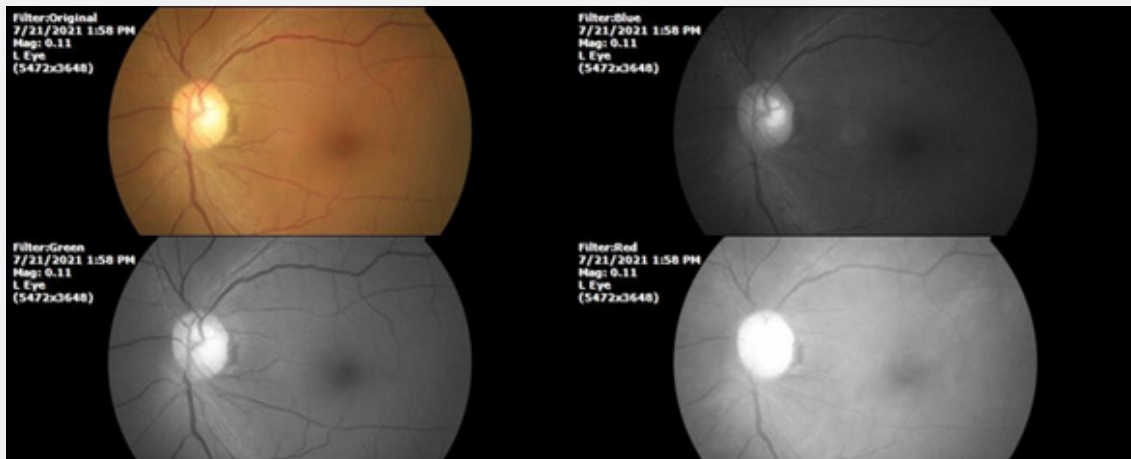


Figure 4: The extension towards the temporal region of the retinal alterations derived from the vascular event are extensive.



**Figure 5:** The optic disc of the left eye has significantly increased excavation, because when mass and energy are not in balance, the nerve fibers tend to retract.



**Figure 6:** Photography of the left eye showed increased optic disc excavation, as well as data consistent with moderate to severe hypertensive retinopathy.

We explain to the doctor (and patient), the severity of the vascular event, and the theoretical bases of our therapeutic approach. The patient agreed and we immediately started QIAP1 1™ at the dose of three sublingual drops for as long as she was awake. Due to the pandemic and the fact that the patient lives about 800 km away from our clinic, the patient did not attend periodic reviews and only continued with the instituted treatment. The patient was only able to return to our facilities until February 9, 2022, and the clinical photographs of both the fundus and the anterior segment, taken that day, are shown below: (Figures 7 to 15)

### Comment

The body functions as a whole, so it is not surprising that an alteration as important as a retinal vascular event is preceded or

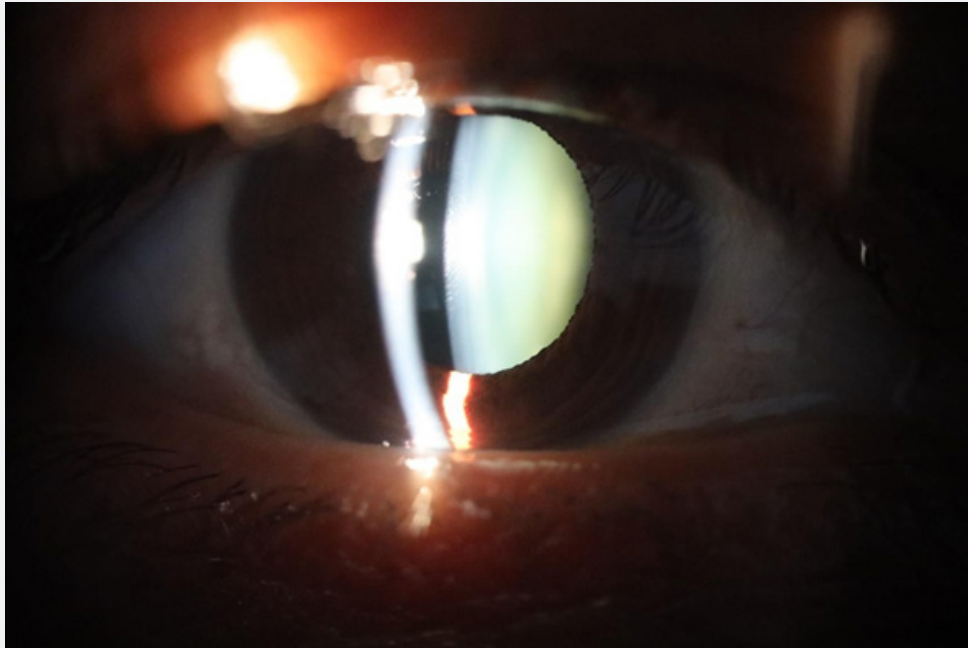
accompanied by systemic alterations such as systemic arterial hypertension, nephropathy, antiphospholipid antibody syndrome and others. By restoring the balance of the very first reaction in the chain of biochemical events that lead to life, this is the dissociation of water, or in other words the production of energy. The cells, tissues, organs or systems that make us up begin to rearrange, to reshape, to recombine, to reorganize, regardless of the name of the disease, the body does not pay attention to the names of the diseases.

### Conclusion

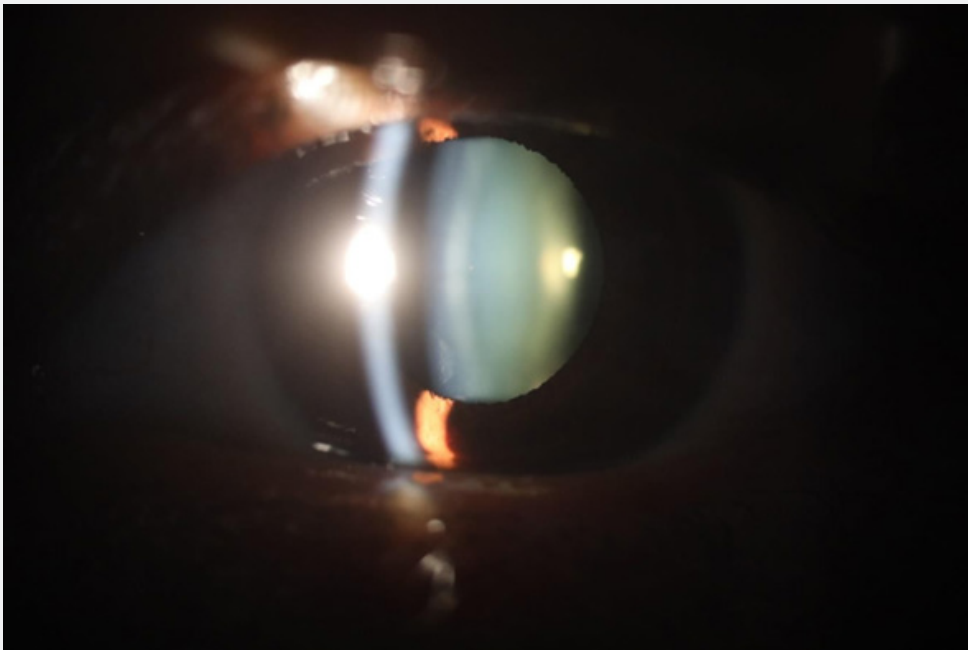
In the body there is a harmony between mass and energy. The balance between mass and energy is exact, amazingly accurate. But to date, the dogma prevailed that our body took energy and at the same time it can built biomass from a single molecule:

glucose. And glucose is a fascinating molecule, nature builds it from CO<sub>2</sub>, and it is widely spread in all living beings, because it is the universal precursor of any organic matter. It's the big building block. But at the same time glucose has many mysteries, because even more is known about the metabolism of proteins than about the metabolism of glucose. The study of glucose metabolic

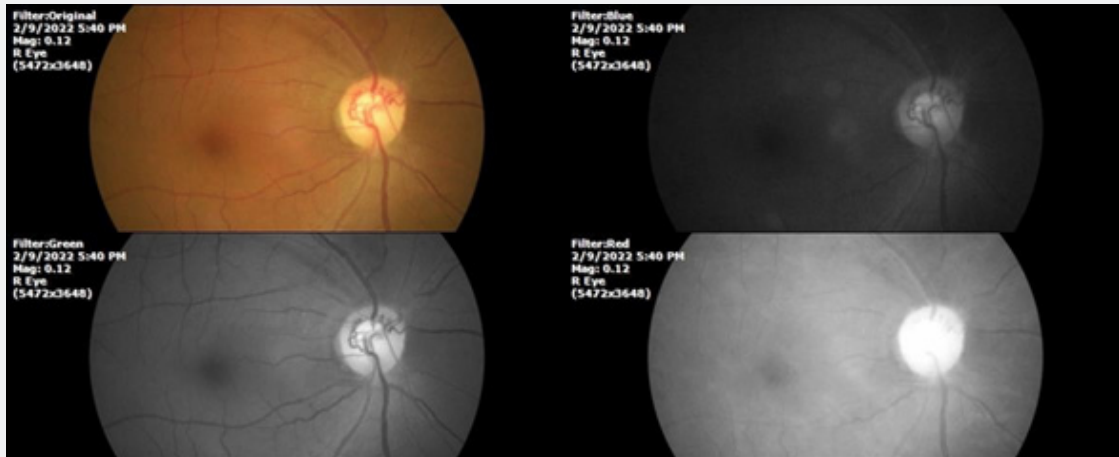
pathways is 95% theoretical. Such is the theoretical and practical difficulty of studying the most soluble of carbohydrates. So much so, that to date, most researchers, most doctors, most biologists, most university professors, still think that glucose is capable of providing the energy that your own metabolism needs.



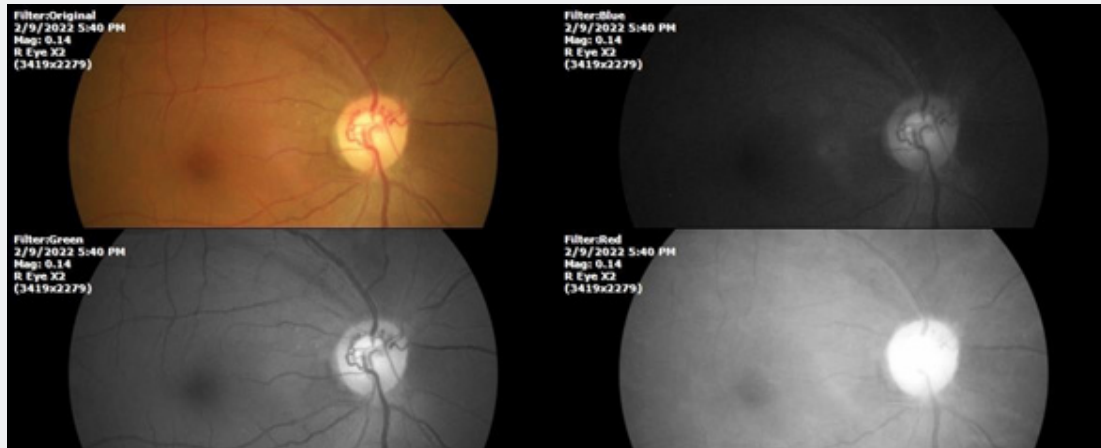
**Figure 7:** The anterior segment of the right eye only shows moderate sclerotic changes of the lens. There is no growth of blood vessels or data of uveitis.



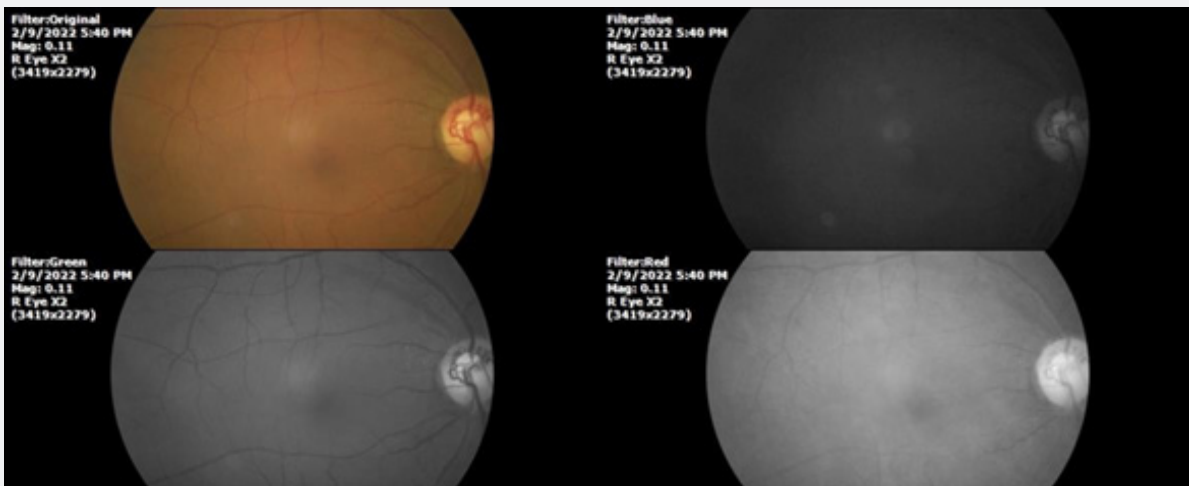
**Figure 8:** The anterior segment of the left eye shows a more transparent lens, there is also no data of edema, angiogenesis, or uveitis.



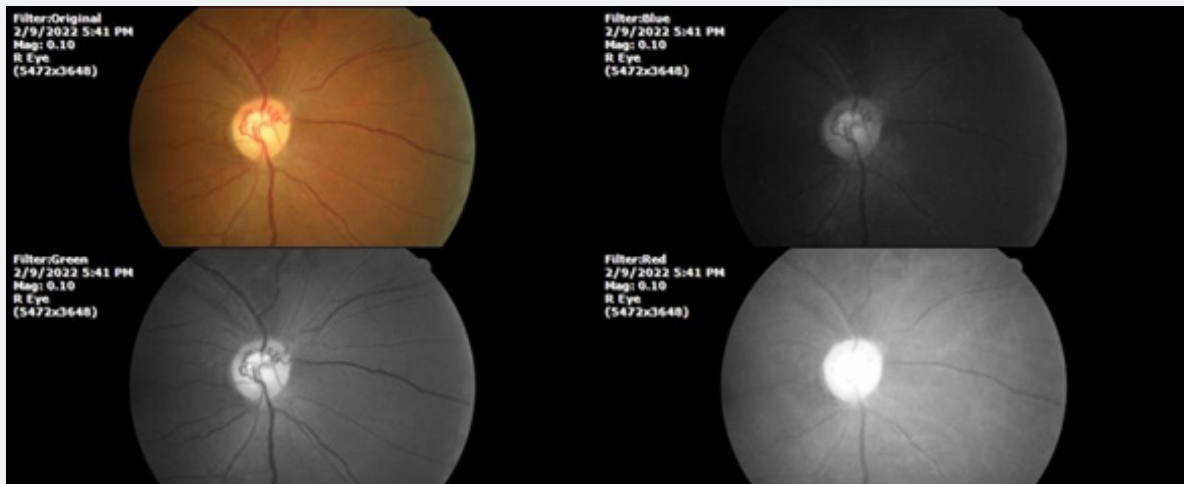
**Figure 9:** The right fundus photograph taken on 02/09/2022, shows a remarkable recovery of retinal and choroidal tissues affected by retinal venous branch occlusion.



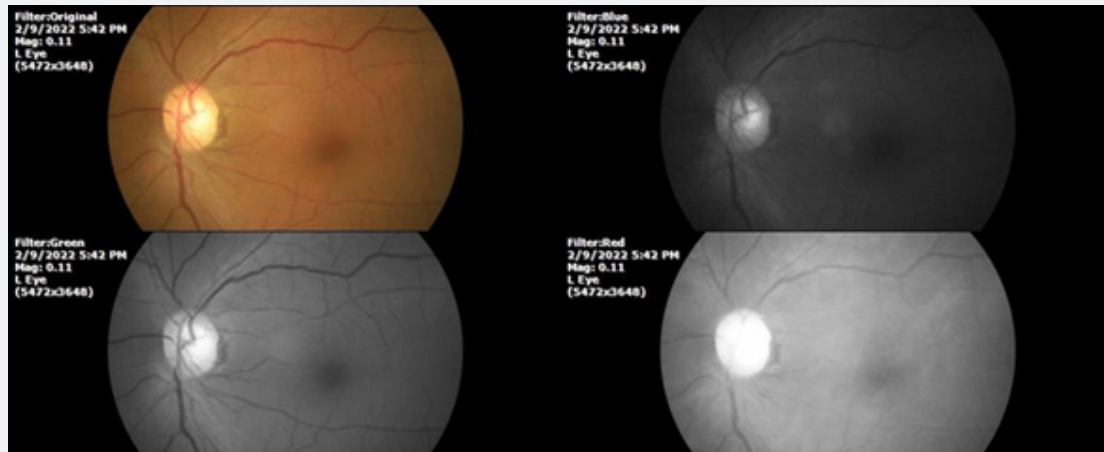
**Figure 10:** In the area where the occlusion of the temporal retinal vein presumably began, I overcomes, spiral vessels are appreciated, without proliferation data.



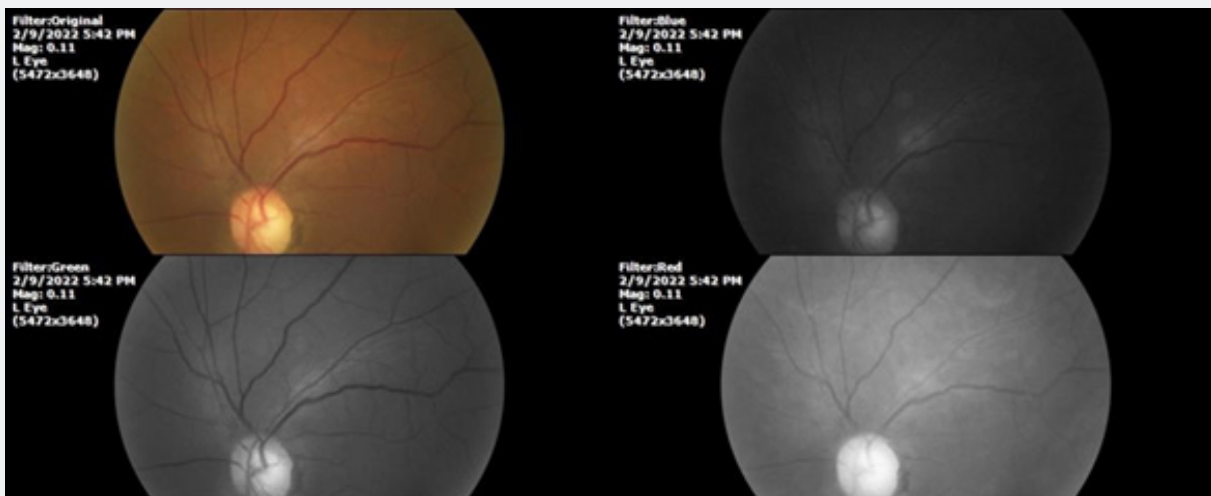
**Figure 11:** The temporal region of the retina and choroid of the right eye, shows significant anatomical integrity. Vision is 20/25.



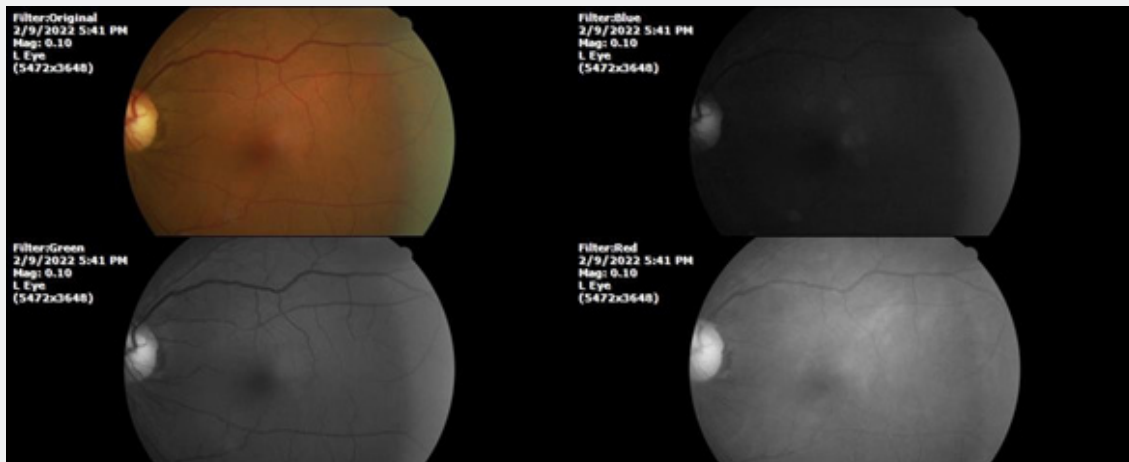
**Figure 12:** Exploring the nasal region of the right eye, no data of inflammation are appreciated, the tissues are very preserved, very recovered.



**Figure 13:** In relation to the left eye, the excavation has not increased, there is no data of edema, or even angiogenesis. Vision is 20/20, which was to be expected given the integrity of the fundus structures.



**Figure 14:** In the upper nasal region of the left eye, two small hyper refringent areas are observed, on the 11 o'clock meridian.

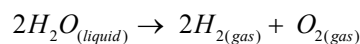


**Figure 15:** The choroid layer can be seen well vascularized, as can be seen in the lower right photograph, taken with a red filter. These are details that indicate that the tissue is in good condition.

Curricula need to be changed at all levels to banish the age-old idea that our body takes energy and mass from the same molecule. Our body has known glucose since the beginning of time, because glucose originates before life itself, hence the sea normally contains glucose; for the very first forms of life required nourishment from the first day 4. And according to Kleiver’s law ( $E=M^{3/4}$ ), the smaller the living entity, the more food it needs; and vice versa: greater you are, less food you need. Glucose is the universal precursor of any organic matter in both plants and animals, the eukaryotic and prokaryotic cells know it well and use it in many ways, because they stretch it, shorten it, twist it, combine it with other elements and molecules, etc.

But the energy that living entities need to drive each and every transformation that the biochemical logic of life requires is taken directly from light, like plants. And human beings are no exception, but they had not been detected, or identified, or at least understood the various molecules that the human body possesses and that are capable of transforming light energy into chemical energy by means of the dissociation of water, in a plant-like way [19]. Among the molecules that we have identified in the human organism capable of dissociating water we have hemoglobin, bilirubin, myoglobin, melanin, neuromelanin, and cytochrome P50.

In general terms, the dissociation of water can be represented as follows:



And in the vast majority of the molecules referred to above, the dissociation of water is irreversible, since the toxicity of oxygen is high and therefore it is expelled into the environment, otherwise the molecule itself would denature and stop exercising the function for which it was created. The dissociation of water is a strongly endergonic reaction, because it requires a lot of energy to happen, for example, if we wanted to replicate the dissociation

of water in the laboratory, we would have to heat the water to 2000 degrees Celsius, and even then, we would not replicate the perfection with which nature carries out this process on a daily basis.

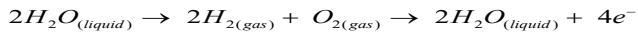
And life has been possible because, for practical purposes, it does not cost living entities the enormous amount of energy required to break the water molecule, because we take it directly from the sun. And since both plants and animals, whether vertebrates or invertebrates, have the same origin, it is that we can exchange molecules through food. The important product of the dissociation of the water molecule is hydrogen because the carrier par excellence in the entire universe, so living beings cannot be different. By injecting the power of light into the water molecule, it breaks down and releases energy, and some of which is carried by molecular hydrogen, which is formed by dissociating water. And although the amount of energy that the minuscule diatomic hydrogen ( $H_2$ ) can carry is small, the process is so constant (day and night) and so efficient, that from that small amount of energy, all the biochemical reactions that make us up, that make up life, are driven properly.

Both water and molecular hydrogen have the exact physical and chemical properties to form part of the fascinating biochemical process of life. For molecular hydrogen, like most gases, does not combine with water, and therefore only moves through the water of the cellular cytoplasm, from its main place of production: the perinuclear space, and moves symmetrically, in all directions, which allows the valuable energy charge of hydrogen to drive (nourish) both the cell nucleus, which has no mitochondria or ATP, and on the other hand moves through the cytoplasm, following the laws of simple diffusion.

On the other hand, water is the exact substrate for the most efficient of the molecules we possess in relation to transforming light energy into chemical energy, such as plants, this is through the dissociation of water.



I refer to melanin, because it is the only molecule capable of absorbing enough energy from the environment, of any kind, not only visible and invisible electromagnetic radiation, and dissipating it in a unique way: dissociating and reassociating water, because melanin is sufficiently strong to tolerate the toxicity of oxygen without decomposing, without denaturing. The chemical reaction that happens continuously inside the melanin can be represented as follows:



For every two water molecules that are re-formed (within melanin) four high-energy electrons are generated. The exactness with which energy is produced inside cells is exact, astonishingly accurate, and has not changed since the beginning of time. But this accuracy is unbalanced with contaminated water, polluted air, pesticides, herbicides, fertilizers, metals, plastics, industrial solvents, etc., and when the very first reaction of life (the dissociation of water) is in imbalance, the whole body tends to become disorganized.

And sooner or later some symptoms or any disease is going to appear. The name of the disease does not matter, because the body does not pay attention to it. We can infer that almost any disease begins with the disturbance of the very first reaction (water dissociation), for nature makes all the cells, all the organisms, all the bodies, without errors. Such is their righteousness, Say Chinese philosophers. When restoring in major or minor degree the accuracy of water dissociation by QIAPI 1, then the rest of the process sequence will tend to improve by itself. That is why we see surprising results with this therapeutic approach, although it is the body that is repairing itself, because when the mass and energy are in balance, the body is very efficient to restore itself, to recompose itself, to reorganize itself, such and as it has been since the beginning of time.

**Acknowledgements:** This work was supported by Human Photosynthesis™ Research Center, Aguascalientes 20000, México.

## References

1. Scott IU, Campochiaro PA, Newman NJ, Biousse V (2020) Retinal vascular occlusions. *Lancet* 396(10266): 1927-1940.
2. Vestergaard N, Torp-Pedersen C, Vorum H, Aasbjerg K (2021) Risk of Stroke, Myocardial Infarction, and Death Among Patients with Retinal Artery Occlusion and the Effect of Antithrombotic Treatment. *Transl Vis Sci Technol* 10(11): 2.
3. Woo SC, Lip GY, Lip PL (2016) Associations of retinal artery occlusion and retinal vein occlusion to mortality, stroke, and myocardial infarction: a systematic review. *Eye (Lond)* 30(8): 1031-1038.
4. Lee CS, Lee ML, Gibbons LE, Yanagihara RT, Blazes M, et al. (2021) Associations Between Retinal Artery/Vein Occlusions and Risk of Vascular Dementia. *J Alzheimers Dis* 81(1): 245-253.
5. Seong HJ, Lee JH, Heo JH, Kim DS, Kim YB, et al. (2021) CLINICAL SIGNIFICANCE OF RETINAL VASCULAR OCCLUSION IN MOYAMOYA DISEASE: Case Series and Systematic Review. *Retina* 41(9): 1791-1798.
6. Vasavada D, Baskaran P, Ramakrishnan S (2017) Retinal Vascular Occlusion Secondary to Retrobulbar Injection: Case Report and Literature Review. *Middle East Afr J Ophthalmol* 24(1): 57-60.
7. Parchand SM (2016) Combined central retinal vein and branch retinal artery occlusion in hyperhomocysteinaemia. *BMJ Case Rep* 2016: bcr2016218379.
8. Sinha S, Rau ATK, Kumar RV, Jayadev C, Vinekar A (2018) Bilateral combined central retinal artery and vein occlusion in a 3-year-old child with nephrotic syndrome. *Indian J Ophthalmol* 66(10): 1498-1501.
9. Gan MA, Moshfeghi DM (2017) Strangulation-Induced Central Retinal Artery Occlusion: Case Report and Review of the Literature. *Retin Cases Brief Rep* 11(3): 258-260.
10. Gelman R, Tsang SH (2016) Sequential Central Retinal Vein and Ophthalmic Artery Occlusions in a Pediatric Case of Primary Antiphospholipid Syndrome. *Retin Cases Brief Rep* 10(1): 58-62.
11. Stepanov A, Hejsek L, Jiraskova N, Feuermannova A, Rencova E, et al. (2015) Transient branch retinal artery occlusion in a 15-year-old girl and review of the literature. *Biomed Pap Med Fac Univ Palacky Olomouc Czech Repub* 159(3): 508-511.
12. Hande P, Sinha B, Nayak S, Srinivasan S, Shetty J (2017) Amalric sign: An augur of ophthalmic artery occlusion. *Indian J Ophthalmol* 65(10): 1033-1035.
13. Caglar C, Caglar Z, Gul A (2013) The central retinal artery occlusion in the right eye followed by a branch retinal artery occlusion in the left eye four days later. *Indian J Ophthalmol* 61(11): 667-669.
14. Beckhauser AP, Arana LA, Skare TL (2008) Síndrome do anticorpo antifosfolípide causando oclusão bilateral de artérias e veias centrais da retina: relato de caso [antiphospholipid syndrome and bilateral retinal artery and vein occlusion: case report]. *Arq Bras Oftalmol* 71(2): 282-285.
15. Park SW, Woo SJ, Park KH, Huh JW, Jung C, et al. (2012) Iatrogenic retinal artery occlusion caused by cosmetic facial filler injections. *Am J Ophthalmol* 154(4): 653-662.
16. Hong JH, Sohn SI, Kwak J, Yoo J, Ahn SJ, et al. (2017) Retinal artery occlusion and associated recurrent vascular risk with underlying etiologies. *PLoS One* 12(6): e0177663.
17. Laczynski DJ, Gallop J, Lyden SP, Bena J, Yuan A, et al. (2020) Retinal artery occlusion does not portend an increased risk of stroke. *J Vasc Surg* 72(1): 198-203.
18. Stoffelns BM, Laspas P (2015) Cilioretinal artery occlusion. *Klin Monbl Augenheilkd* 232(4): 519-524.
19. Herrera AS (2017) Towards a new ophthalmic biology and physiology: the unsuspected intrinsic property of melanin to dissociate the water molecule. *MOJ Cell Sci Rep* 4(2): 49-60.



This work is licensed under Creative Commons Attribution 4.0 License  
DOI: [10.19080/JOJO.2022.09.555762](https://doi.org/10.19080/JOJO.2022.09.555762)

**Your next submission with Juniper Publishers  
will reach you the below assets**

- Quality Editorial service
- Swift Peer Review
- Reprints availability
- E-prints Service
- Manuscript Podcast for convenient understanding
- Global attainment for your research
- Manuscript accessibility in different formats  
**( Pdf, E-pub, Full Text, Audio)**
- Unceasing customer service

**Track the below URL for one-step submission**  
<https://juniperpublishers.com/online-submission.php>