

Inferior Rectus Myositis after an Uneventful Repair of Blowout Fracture



Mohsen Bahmani Kashkouli*, Abtin Heirati and Hamed Sianati

Eye research center, Iran University of Medical Sciences, Iran

Submission: December 19, 2016; Published: March 21, 2017

*Corresponding author: Mohsen Bahmani Kashkouli, Rassoul Akram Hospital, Sattarkhan-Niayesh St., Tehran, Iran, Tel: +9821-66509162; Fax: +9821-66558811; Email: bahmanik@yahoo.com

Summary

PA 7-year-old girl who had undergone a successful orbital floor blow-out fracture repair continued to have up-gaze and down gaze restriction post-operatively. She was observed for 6 weeks when an orbital imaging showed inferior rectus enlargement. Enlarged IR muscle associated with pain and restriction of up and down gaze led to a provisional diagnosed of myositis to which oral steroid was commenced and resulted in full recovery of up-gaze in 2 months.

Keywords: Blowout fracture; Inferior rectus; Myositis; Orbital fracture

Background

Early repair of a white-eyed blowout orbital floor fracture has been recommended in order to avoid permanent ischemic damage to the entrapped inferior rectus (IR) muscle [1]. However, even after a proper surgical repair of orbital floor fracture, up-gaze restriction may persist predominantly in children [1,2]. This may result from necrosis of muscle [2], IR muscle fibrosis [1], residual entrapped IR muscle sheath or peri-

muscular tissue [3], and preoperative severe injury and swelling of the IR muscle [4].

This is, to the best of our knowledge, the first report of IR myositis after an uneventful white eyed blow out fracture repair. Iran University Eye Research Center ethic approval and patient's parents' consent were obtained.

Case Presentation

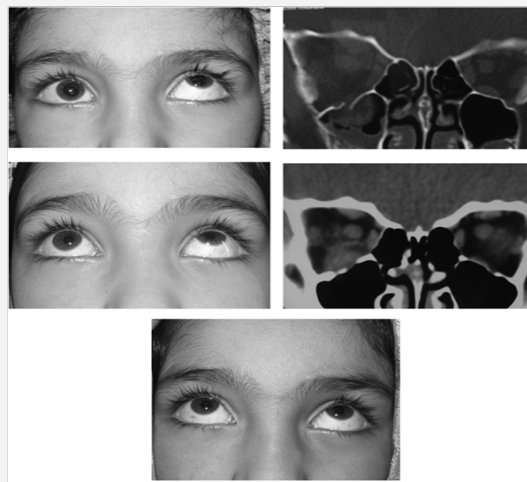


Figure 1: Top; Significant (-4) up-gaze restriction (left) and a trapdoor orbital floor fracture (right) in a 7-year-old girl, preoperatively. Middle; Remained (-2) up-gaze restriction (left) and significant inferior rectus muscle enlargement (right) 1.5 months after fracture repair. Bottom; marked improvement of up-gaze after commencing oral steroid.

A 7 year-old girl was referred 2 days after a facial trauma. On examination, there was no or little eyelid swelling but marked painful restriction of up-gaze (-4) and moderate restriction of down gaze (-2) on the right eye. There was also hypoesthesia on the right cheek area. Vision (20/20 on both eyes) and ocular examinations were otherwise normal. Coronal Computed tomography (CT) scan showed a trapdoor floor fracture with inferior rectus entrapment which was extended from mid-globe to mid-orbit sections (Figure 1). Forced duction test was performed just before starting the operation 4 days after trauma which was strongly positive. Using trans-conjunctival approach, the entrapped muscle and peri-orbital tissue were released and the fracture site was covered by a properly fashioned porous polyethylene (Medpor, USA) sheet (0.85mm). The IR muscle was found to be discolored but viable. Forced duction test showed no restriction at the end of operation. Postoperatively, she was instructed to take oral systemic antibiotic (Cephalexin 250 mg, 4 times daily for 5 days), topical antibiotic and topical steroid (4 times daily for a week). A day after operation, there was less limitation of motion in down gaze (-1) and up-gaze (-2). However, she continued to have the same degrees of restriction associated with mild pain throughout post-operative follow ups at 1, 4, and 6 weeks. Since the repair was uneventful and postoperative follow up did not show improvement of muscle restriction, an orbital CT scan was requested. It showed no residual entrapment but significantly enlarged IR muscle. Increased thickness of IR muscle associated with pain on movement led to a provisional diagnosis of post-operative IR myositis and or persistent intra-sheath hematoma. Therefore, oral prednisolone (1mg/kg/day) was commenced and tapered within 6 weeks time. Up- and down restriction improved a week after its commencement. Completely normal examination was observed 1 year afterward with no recurrence of restriction and pain.

Conclusion

Possible explanations for persistent up-gaze restriction after a successful blowout fracture repair are: residual entrapment of any part of orbital soft-tissue [3] especially in the presence of posterior floor fracture [5], strangulation and necrosis of IR muscle [2], IR muscle fibrosis [1] and preoperative severe injury and swelling of the IR muscle [4]. Younger patients seem to recover longer than adults and a satisfactory force duction test

at the end of the operation does not guarantee free voluntary movement of the involved eye [1,2]. In the presenting case, up- and down gaze restriction mildly improved a day after operation, but remained the same up to 1.5 months then after. In order to assess the possibility of residual IR entrapment, an orbital CT scan was requested which showed no entrapment but significantly enlarged IR muscle. In the context of up and down gaze restriction, pain, and enlarged IR muscle an orbital inflammatory myositis and or persistent IR hematoma were the provisional diagnoses. A rapid response to oral steroid was in favor of post-operative IR myositis. Post strabismus surgery extraocular myositis has been previously reported [6]. Whereas, to the best of our knowledge, there has been no any report of IR myositis after orbital fracture repair. Preoperative IR muscle swelling was reported to be a useful indicator of longer recovery after orbital floor fracture repair [4]. On reviewing the case, there was no significant IR enlargement preoperatively. Since this patient was treated with systemic steroid, it is not possible to comment on whether post-operative myositis is self limited if left untreated. The myositis did not recur one year after steroid treatment which may imply that it was due to either trauma or intra-operative manipulation. In conclusion, post-operative IR myositis should be considered in cases with residual up-gaze limitation after an uneventful orbital floor fracture repair.

References

1. Jordan DR, Allen LH, White J, Harvey J, Pashby R, et al. (1998) Intervention within days for some orbital floor fractures: The white-eyed blowout. *Ophthal Plast Reconstr Surg* 14(6): 379-390.
2. Cope MR, Moos KF, Speculand B (1999) Does diplopia persist after blow-out fractures of the orbital floor in children? *Br J Oral Maxillofac Surg* 37(9): 46-51.
3. Dutton JJ (1991) Management of blow-out fractures of the orbital floor (Editorial). *Surv Ophthalmol* 35(4): 279-280.
4. Matsunaga K, Asamura S, Morotomi T, Wada M, Wada Y, et al. (2011) Association between preoperative inferior rectus muscle swelling and outcomes in orbital blowout fracture. *J Craniomaxillofac Surg* 39(7): 509-514.
5. Biesman BS, Hornblass A, Lisman R, Kazlas M (1996) Diplopia after surgical repair of orbital floor fractures. *Ophthal Plast Reconstr Surg* 12(1): 9-16.
6. Wolf AB, Yang MB, Archer SM (2007) Postoperative myositis in reoperated extraocular muscles. *J AAPOS* 11(4): 373-376.



This work is licensed under Creative Commons Attribution 4.0 License
DOI: [10.19080/JOJO.2017.02.555586](https://doi.org/10.19080/JOJO.2017.02.555586)

Your next submission with Juniper Publishers will reach you the below assets

- Quality Editorial service
- Swift Peer Review
- Reprints availability
- E-prints Service
- Manuscript Podcast for convenient understanding
- Global attainment for your research
- Manuscript accessibility in different formats (Pdf, E-pub, Full Text, Audio)
- Unceasing customer service

Track the below URL for one-step submission

<https://juniperpublishers.com/online-submission.php>