



Interest of *Moringa oleifera* in the Treatment of Fungal Mycetoma



Nomtondo Amina Ouédraogo^{1,2*}, Bénilde Marie Ange Tientore-Kambou^{3,2}, Nina Astrid Nde/Ouédraogo^{3,2}, Fagnima Traoré⁴, Muriel Sidnoma Ouédraogo^{2,5}, Gilbert Patrice Tapsoba^{2,5}, Nessine Nina Korsaga/Somé^{2,5}, Fatou Barro-Traoré², Pascal Niamba^{2,5} and Adama Traoré^{2,5}

¹Service of Dermatology, Center Raoul Follereau, Burkina Faso

²Unit of Research in Health Sciences, University of Ouagadougou, Burkina Faso

³Department of Radiology and Medical Imaging, Bogodogo District Hospital, Burkina Faso

⁴Department of Dermatology, Hospital Center Régional, Burkina Faso

⁵Department of Dermatology, Hospital Center University Yalgado Ouédraogo, Burkina Faso

Submission: January 31, 2017; Published: May 30, 2017

*Corresponding author: Nomtondo Amina Ouédraogo, Service of Dermatology, Center Raoul Follereau, Burkina Faso, Email: nomtondo2000@yahoo.fr

Abstract

Fungal mycetoma is inflammatory pseudotumor of subcutaneous soft tissue and bone due to exogenous fungi. Its evolution is chronic, often polyfistulated with emission of fungal grains. We report a case of a 44-year-old grower with a fungal mycetoma of the foot with bone damage due to *Aspergillus fumigatus*. The tumefaction partially regressed after 6 months daily consumption of *Moringa oleifera* seeds. Also called "miracle tree", *M. oleifera* is a shrub, growing in a tropical region, having several properties recognized in traditional medicine, its grains would have an antifungal activity. Doppler, by demonstrating hyper vascularization reflecting the presence of inflammatory remodeling controls the activity of the disease, is an interesting, non-invasive factor for the follow-up of the disease.

Keywords: Eumycetoma; Madura foot; *Aspergillus fumigatus*; Hypervascularization; Antifungal activity

Introduction

Mycetomas are pathological processes in which agents of fungal or actinomycotic origin emit grains. They are common in tropical and sub-tropical countries. Fungal mycetomas due to fungi and actinomycotic mycetomas due to actinomycetes [1]. Mycetomas are still endemic in the mycetomic belt (on both sides of the fifteenth northern parallel) where Burkina Faso is located and in which the climate makes possible the survival of the agents (long dry season of at least Seven months followed by a short rainy season) [2].

Eumycetomas or fungal mycetomas are inflammatory pseudotumors of subcutaneous soft tissues due to exogenous fungi. They are often polyfistulated with an emission of fungal grains and a chronic evolution. They evolve slowly, determining after certain duration of evolution, osseous attacks that involve the functional prognosis, then visceral attacks sometimes fatal [3]. Treatment poorly codified, recourse to long-term antifungals and surgery in the event of associated bone involvement.

We report a case of fungal mycetoma of the foot with bone involvement that partially regressed after 6 month regular consumption of seeds of *Moringa oleifera*.

Observation

A 44-year-old man Burkinabe, a farmer, consulted the dermatology department of the Raoul Follereau Center for a polyfistulized tumor of the right foot. The anamnesis did not find any notion of local trauma. The disease had begun 5 years ago by a subcutaneous nodule of the sole of the foot, which gradually increased in volume impeding walking. Clinical examination at admission indicated a firm tumefaction of the anterior 2/3 of the foot, going from the back to the sole of the foot about 15cm in diameter, giving rise to black grains of 1 to 2mm in diameter as well as hematic and nauseous (Figure 1). The examination had not found loco-regional and distant nodes. The neurological examination was normal. The rest of the somatic examination was without anomaly. The biological exploration

noted only a moderate increase in sedimentation rate to 36mm at the first hour. The hemogram, liver function, renal function, muscle enzymes were normal. Histology compatible with mycetomanoted a polymorphic granulomatous infiltrate (histiocytes, polynuclear neutrophils and lymphocytes) with suppuration foci circumscribing small-sized pigmented grains with irregular contours.

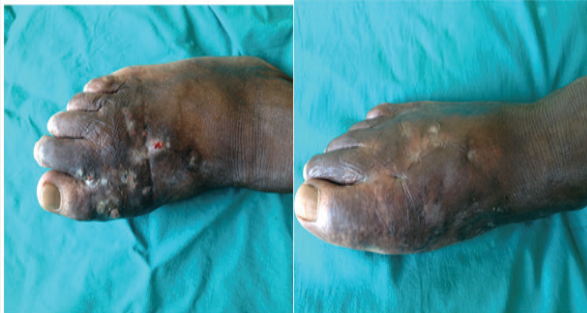

Figure 1: Comparative iconography of the dorsal aspect of the foot showing the mycetoma before (polyfistulized) and after 6 months (cicatrizated of fistulas and tumor) consumption of *M. Oleifera*.

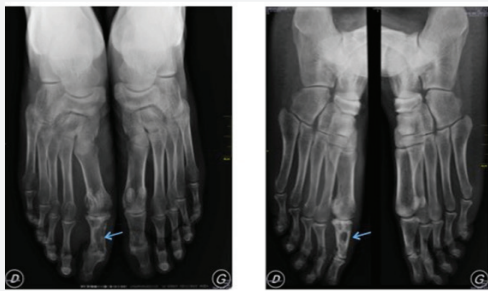

Figure 2: Radiography of the frontal and posterior feet: Bone luminosity with sharp, regular and opaque contours in the first phalanx of the first ray of the right foot. Thickening of the cortical bone of the 1st phalanx and the head of the right 1st margin.

The mycological study concluded a fungal mycetoma by highlighting *Aspergillus fumigatus* in the tumor collection. The X-ray of the right foot performed in frontal incidence and 3/4 revealed bone luminosity with sharp, regular and opaque contours in the first phalanx of the first radius of the right foot. A thickening of the cortical bone of the 1st phalanx and the head of the right 1st margin was noted. There were no other abnormalities in the bones (Figure 2). CT scan of the feet without and with injection of contrast agent with reconstruction in soft parts and in bone window revealed bone deficits hypodense of cortico-medullary seat, interesting the diaphyso-epiphyseal regions of the first phalange of the right foot and the head of the 1st metatarsal. Their contours were sharp, regular and dense. The sesamoids were dense and atrophic. There was hypertrophy of the soft parts of the forefoot, enhanced after injection of contrast medium (Figure 3). No subcutaneous fluid collection was detected. These imaging aspects led to the conclusion that

the 1st metatarsal head of the 1st metatarsal head and the 1st right foot phalanx with the thickening of the bone cortex and thickening of Soft parts of the tarsus facing.

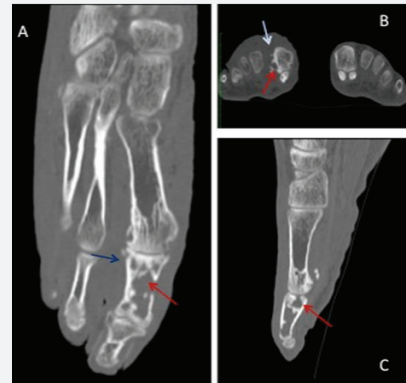


Figure 3: CT sections of the right forefoot: Axial reconstruction (A) in bone window of the right forefoot passing through the first ray, showing the two types of bone lesions in the mycetoma: destruction and construction. Lesions affect the 1st phalanx and the head of the 1st metatarsal. The bone lyses are regular, with dense contours and erodes the cortical that is thickened in places. Coronal (B) and sagittal (C) cut in bone window passing through the head of the 1st metatarsal, showing the regular cortical bone lyses and the thickening of the soft parts of the tarsus.

These imaging aspects led to the conclusion that the 1st metatarsal head and the 1st phalanx of the right radius of the right foot were found to have type Ia (Madwell Classification) osteolysis plaques, with thickening of the cortical bone and thickening of Soft parts of the tarsus facing. Subcutaneous hypoechoic formations containing hyperechogenic grains, compatible with a fungic ultrasound. Hyper vascularization at the Doppler may reflect the presence of active inflammatory changes.

A surgical management associated with a terbinafine treatment of 1g per day and antiseptic was proposed but did not meet the consent of the patient, who did not wish to undergo surgery and did not have financial resources for it and no medical insurance to cover him. He interrupted the medical follow-up.

Contacted several times by the healthcare team without success, the patient is finally reviewed after 6 months. The clinical examination noted a significant clinical improvement of the mycetoma lesions with a swelling of the tumefaction compared to the 1/3 middle of the right foot, complete cicatrizated of the polyfistulae lesions of the back of the foot. A regression with partial healing of the lesions of the foot is observed (Figure 1 & 4). One notes a persistence of blackish lesions in the middle 1/3 and opposite the plantar face of the toes of the foot. The discomfort with walking has been considerably improved. When questioned, the patient reported initiating a traditional medicine treatment consisting of daily oral intake of 4 seeds of *Moringa oleifera* (*M.oleifera*) and applying of the leaves on the lesion for 6 months.

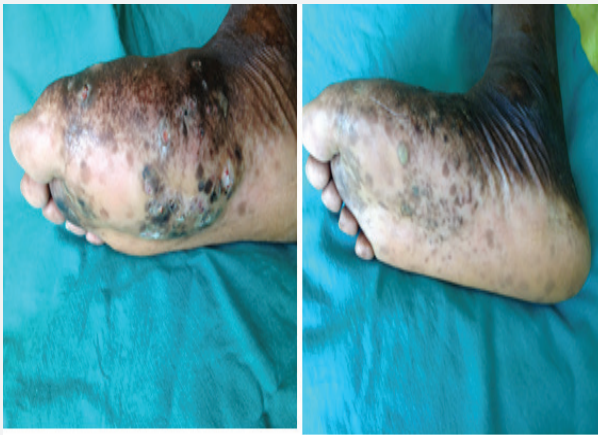

Figure 4: Comparative Iconography of the front foot (polyfistulization) and after 6 months of consumption of *M. Oleifera* (partial healing).

A mycological control (realized for free) of tumefaction was negative as well as the aspergillary serology (realized for free) performed (Ac antiA fumigatus EIA bio rad=0 AU/ml, and Ac anti A fumigates HAI <80).

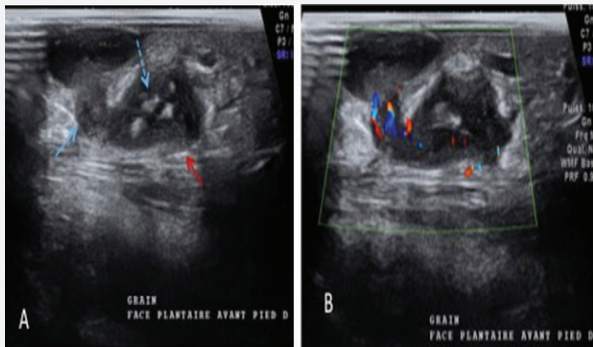


Figure 5: Ultrasound sections through cutaneous papules. (A) Diffuse subcutaneous hypoechoic oval ranges of different depths communicating through pertuis with more superficial ranges. Hyperechoic punctiform elements with angular contours, measured between 1 and 2mm corresponding to the grains. (B) Hyper vascularization at the Doppler. Note the presence of an overall thickening of the soft parts of the right forefoot.

Doppler ultrasound (realized for free) performed in projection of the plantar face of the right foot, visualized opposite the cutaneous papules, hypoechoic oval beaches. They had different depth levels in the subcutaneous tissue. The deepest ones communicated by pertuis with the more superficial beaches. Within certain deep collections, spontaneously hyperechoic elements with angular contours, measured between 1 and 2mm corresponding to the grains, were visualized. At the Doppler, there is an arterial hyper-vascularization within hypo-echogenic rearrangements (Figure 5). An overall thickening of the soft parts of the right forefoot was noted. These subcutaneous hypoechoic formations on the plantar surface of the right foot containing hyperechogenic grains in them, are compatible with a

fungal ultrasound. Doppler hypervascularization may reflect the presence of active inflammatory remodeling.

Discussion

The diagnosis of fungal mycetoma of our patient was raised and retained by the anamnestic aspects: long duration of evolution, the notion of trauma not recovered. Indeed, the delay between the occurrence of the disease and the inoculant bite of the germ being very long, the latter is often forgotten [1].

The clinical aspect: the polyfistulized swelling of the foot emitting black grains, the black grains always being of fungal origin [1]. The attack of the foot is usual and defines the classic foot of Maduræ.

The histological aspect: a polymorphous granulomatous infiltrate (histiocytes, neutrophilic polynuclear cells and lymphocytes) with suppuration foci circumscribing small pigmented grains with irregular contours suggestive of mycetoma. This is confirmed by the mycological study which isolated *Aspergillus fumigatus* confirming the fungal origin.

The first particularity of this case is the isolation of *Aspergillus fumigatus* from mycology. Indeed, the germs usually incriminated in fungal mycetomas are *Madurella Mycetomatis* in our context [2,3]. Verma & Kotwal [4,5] studies have reported *Aspergillus* as the germ involved in eumycetoma [4-7].

The second feature is its clinical regression with *M. oleifera* seeds consumption, which resulted in complete healing of the lesions of the back of the foot and partial healing of the plantar surface in 6 months.

M. oleifera is a small shrub of the family of Moringaceae, native to India, growing in tropical and subtropical zone, including 13 species, known in traditional oriental medicine for its medicinal properties [8,9]. The species *M. oleifera* Lam or *M. pterogo sperma* Gaertn is the most popular in Africa notably in Burkina Faso Called "miracle tree", all parts of the plant (leaves, bark, seeds, flowers, roots) have significant pharmacological activities: antifungal, hypocholesterolemic, hypoglycemic, anti-tumor, anti-infectious, antioxidant, antibacterial. Antifungal activity on certain skin fungi such as *Trichophyton rubrum*, *Trichophyton mentagrophytes*, *Epidermophyton floccosum* and *Microsporium canis* [10-13]. Thus, in our patient, *M. oleifera*, by his antifungal properties, would have permitted the complete melting of the tumefaction of the foot, the partial cicatrization of mycetoma of the foot? These questions could serve as a hypothesis for further studies to confirm the antifungal activity of *M. oleifera* active in the eumycetoma. This anti-fungal activity may prove to be a major step forward in the therapeutic management of fungal mycetomas, especially in developing countries where long-term treatment and the financial inaccessibility of antifungal drugs are a barrier to taking in efficient charge.

The last feature is that the Doppler showed active internal inflammation despite clinical improvement. According to Dikhayev, the use of imaging is essential to the assessment of pre-therapeutic extension, but also to the evolutionary follow-up of the bone involvement, essentially and the soft parts of fungal mycetoma, conditioning the indication of medical and surgical treatment as well as the surgical gesture to be realized [14]. The involvement outside the soft parts can be manifested at the articular and extra synovial level as in the case of Thiouri where there was a fusing carpet. Iniesta [15] found the same lesions in the type of destructions and fusion of the leg and foot bones after 20 years of evolution [14,15].

Osteolysis has been described radiologically with varying degrees of developmental outcome. Chronic osteitis (X-ray builder and destructive aspect) and endemic Kaposi disease may be discussed but clinic and mycology were directed towards fungal mycetoma [1,16,17].

At the Doppler, the presence of inflammatory rearrangement always active on the plantar face, indicates the persistence of the activity of the germ in this part of the foot reached. The ultrasound, non-invasive, reproducible, inexpensive appears best adapted in our working context. Mycetomas give characteristic ultrasound images described by Sudanese authors: multiple cavities with thick walls without acoustic reinforcement [18]. It is possible to distinguish, according to these same authors, the action mycetomas of the fungal mycetomas according to the echo graphic aspects. The former have poorly individualized echoes corresponding to small and cement less grain in most species. They are usually grouped together at the bottom of the cavities. Echoes are sharp, shiny, hyper reflective in black fungal mycetomas. Ultrasound makes it possible to delineate the extension of the mycetoma more precisely than the clinical examination [17-19]

Conclusion

This finding reveals a rare fungal mycetoma cause: *Aspergillus fumigatus*. It also arouses interest in *M. oleifera* in the management of eumycetoma, which would be appreciable in our working context. Further studies could validate or invalidate this hypothesis. Doppler ultrasound could be an interesting examination for the monitoring and surveillance of fungal mycetoma, which can take several years to manage and help with therapeutic decisions.

References

1. Develoux M, Dieng MT, Kane A (2003) Management of mycetomas in West Africa. Bull Soc Pathol Exot 96: 376-382.

2. Diallo S, Diatta BA, Diallo M (2013) Dorsal mycetoma with pseudo-tumoral presentation. Ann Dermatol Venereology 140: S30.
3. Diatta BA, Ndiaye M, Sarr L (2014) A dorsal tumor fungal mycetoma: interest of broad surgery associated with terbinafine. J Mycol Med J Med Mycol 24: 351-354.
4. Verma R, Vasudevan B, Sahni AK (2015) First reported case of *Aspergillus nidulans* eumycetoma in a sporotrichoid distribution. Int J Dermatol 54(1): 74-77.
5. Kotwal N, Yanamandra U, Badwal S (2012) Mycetoma foot caused by *Aspergillus* in a diabetic patient. Intern Med 51(5): 517-518.
6. Hopps S, Roach A, Yuen C (2015) Treatment for a eumycetoma infection caused by *Aspergillus* in an immunocompromised host: a case report. Transpl Infect Dis 17(1): 94-97.
7. Costa F, Polini F, Zerman N (2007) Surgical treatment of *Aspergillus* mycetomas of the maxillary sinus: review of the literature. Oral Surg Oral Med Oral Pathol Oral Radiol Endodontology 103(6): e23-e29.
8. Anwar F, Latif S, Ashraf M (2007) *Moringa oleifera*: a food plant with multiple medicinal uses. Phytother Res 2(1): 17-25.
9. Adejumo OE, Kolapo AL, Folarin AO (2012) *Moringa oleifera* Lam. (Moringaceae) grown in Nigeria: In vitro antisickling activity on deoxygenated erythrocyte cells. J Pharm BioalliedSci 4(2): 118-122.
10. Dahot MU (1998) Antimicrobial activity of small protein of *Moringa oleifera* leaves. J Islam Acad Sci 11: 6.
11. Dubey DK, Dora J, Kumar A (2013) A multipurpose tree-*Moringa oleifera*. Int J Pharm ChemSci 2: 415-423.
12. Bukar A, Uba A, Oyeyi T (2010) Antimicrobial profile of *Moringa oleifera* Lam. Extracts against some food-borne microorganisms. Bayero J Pure Appl Sci 3(1): 43-48
13. Fatima T, Sajid MS, Jawad-ul-Hassan M (2014) Phytomedicinal value of *Moringa Oleifera* with special reference to antiparasitics. Pak J AgricSci 51(1): 251-262.
14. Benaissa HT, Ammari L, Aoun K (2010) Fungal mycetoma of the hand: about the first Tunisian case. J Mycol Med J Med Mycol 20: 223-226.
15. Iniesta A, Baptista C, Guinard D Actino-mycoticmycetoma of the foot, about a case. In: Annals of Aesthetic Plastic Surgery. Elsevier, Netherlands, pp. 164-167.
16. Develoux M, Ndiaye B, Dieng MT (1995) Mycetomas in Africa. Cah Studies Rech Francoph 5(4): 211-217.
17. Develoux M (2016) Mycetomas and their treatment. J Mycol Med 26: 77-85.
18. Fahal AH, Sheik HE, Homeida MMA (1997) Ultrasonographic imaging of mycetoma. Br J Surg 84(8): 1120-1122.
19. Padhi S, Uppin SG, Uppin MS (2010) Mycetoma in South India: retrospective analysis of 13 cases and description of two cases caused by unusual pathogens: *Neoscytalidium dimidiatum* and *Aspergillus flavus*. Int J Dermatol 49(1): 1289-1296.



This work is licensed under Creative
Commons Attribution 4.0 License
DOI: [10.19080/JOJCS.2017.02.555600](https://doi.org/10.19080/JOJCS.2017.02.555600)

Your next submission with Juniper Publishers will reach you the below assets

- Quality Editorial service
- Swift Peer Review
- Reprints availability
- E-prints Service
- Manuscript Podcast for convenient understanding
- Global attainment for your research
- Manuscript accessibility in different formats
(Pdf, E-pub, Full Text, Audio)
- Unceasing customer service

Track the below URL for one-step submission

<https://juniperpublishers.com/online-submission.php>