Juniper Online Journal of Case Studies

Juniper Publishers key to the Researchers

Case Report
Volume 2 Issue 2 - March 2017
DOI : 10.19080/JOJCS.2017.02.555584

JOJ Case Stud

Emphysematous Cholecystitis Complicating a Transarterial Chemoembolization Procedure

Talal Alnabelsi[1]*, RamziMulki[1] and Gabor Varadi[2]

[1]*Department of Internal Medicine, Einstein Medical Center, USA*

[2]*Departments of Hematology and Oncology, Einstein Medical Center, USA*

Submission: February 04, 2017; **Published:** March 03, 2017

***Corresponding author:** Talal Alnabelsi, 5501 Old York Road, Philadelphia, PA 19141, Einstein Medical Center Philadelphia, USA, Tel: 2672700683; Email: alnabelt@einstein.edu.t

Abstract

Abdominal pain is a common complaint following transarterial chemoembolization (TACE). It is often attributed to hepatocyte damage and regarded as an expected side effect of therapy. Cholecystitis is an uncommon but documented complication of TACE procedures due to reflux of embolic material into the cystic artery. In most cases, cholecystitis can be managed expectantly without the need of any intervention. Our case is interesting as it describes an uncommon complication of TACE procedures: emphysematous cholecystitis requiring emergent open cholecystectomy. It highlights that physicians should be cognizant of the complications of advanced radiological interventions as these conditions can have a poor prognosis if remain unrecognized.

Keywords: Transarterial chemoembolization (TACE); hepatocellular carcinoma (HCC)

Introduction

Transarterial chemoembolization (TACE) is a well-established treatment for patients with hepatocellular carcinoma (HCC). Knowledge of the common and rare complications arising from this procedure is necessary for everyone who comes across this patient group. Cholecystitis is a rare complication of TACE procedures due to reflux of embolic material into the cystic artery. Our patient reported abdominal pain, a very common complaint following a TACE procedure. Before disregarding it as an expected side effect of therapy, one must remain vigilant as serious pathology may exist underneath.

Case Presentation

A 61 year old Asian male presents to the hospital for an elective TACE procedure. He has a history of hepatitis C cirrhosis and HCC status post left hepatic lobectomy a year prior to this admission. The patient underwent a successful right hepatic artery chemoembolization with a mixture of doxorubicin, ethiodol and embosphere particles. A few hours following the procedure, he developed moderate right upper quadrant pain which was managed supportively with intravenous opiates and close monitoring overnight.

Over the next 2 days his pain persisted and was accompanied by intermittent "shakes" and a low grade fever at 38 degrees. He was tachycardic to 110 beats per minute but remained normotensive. He had a tender right upper quadrant with a negative murphy's sign, no rebound and no guarding. Laboratory markers were remarkable for a white cell count of 22.2 x 103cells/μL, alanine and aspartate transaminase peaking at 1190 U/L and 877 U/L respectively, alkaline phosphatase of 180 U/L and bilirubin of 1.1 mg/dL. The INR and hemoglobin levels remained stable. A liver ultrasound revealed changes related to the TACE procedure but also a moderately distended gallbladder with non-dependent air and wall edema. A CT scan of the abdomen and pelvis revealed an infracted gallbladder with emphysematous cholecystitis and small areas of gallbladder wall perforation (Figure 1).

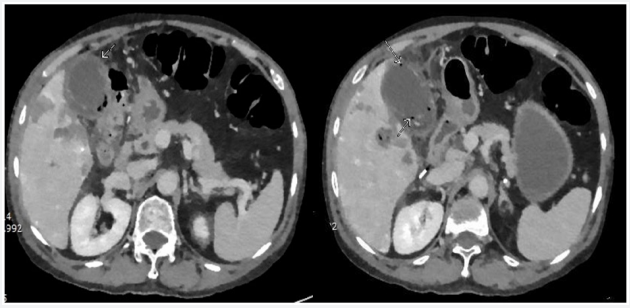

Figure 1: CT of the abdomen and pelvis revealing gallbladder wall edema (arrow head) and evidence of micro perforations with air in the gallbladder wall (arrows). Also noted are wedge-shaped areas of hypoattenuation in the liver compatible with post TACE changes.

The patient received appropriate resuscitative measures including antibiotic coverage for intra-abdominal pathogens. The general surgery team was consulted and given the patient's deteriorating clinical status and impending gallbladder perforation a decision was made to proceed with an emergent open cholecystectomy. The patient had an uneventful postsurgical course and was discharged home 3 days later. The final pathology report revealed a perforated transmural acute necrotizing cholecystitis with identifiable chemoembolization material.

Discussion

TACE has become a commonly utilized treatment for HCC. It is offered for palliative purposes in inoperable tumors, to shrink tumors prior to surgery or as a bridge to liver transplant [1,2]. Major complications occur in 5% of patients and the risk of death is 1% [3]. Complications related to the procedure include access site injuries, hepatic failure, biloma or abscess formation, pulmonary embolization or cholecystitis [3].

Following a TACE procedure it is not uncommon for patients to experience abdominal pain. This can be accompanied by systemic symptoms such as fatigue and fever, a constellation referred to as postembolization syndrome. Additionally, laboratory abnormalities including leukocytosis and elevation in liver enzyme levels are expected after the procedure. The mechanism of these changes can be explained by hepatocyte damage however some authors postulate cystic artery embolization to be the cause of this pain [4,5].

Therefore on many occasions it may be difficult to discern the etiology of the pain and imaging may be necessary to rule out serious complications. Unfortunately, there are currently no guidelines or recommendations to image patients with abdominal pain following TACE. Clues to pursue further investigations may include persistence of symptoms and deterioration in the hemodynamic or clinical status of the patient. Cholecystitis is a rare but well-documented complication with a variable incidence ranging from 0.3 to 10% [6].

The gallbladder unlike the liver has a single vascular supply through the cystic artery. This makes the gallbladder susceptible to injury or infarction due to inadvertent embolization during the TACE procedure. The cystic artery arises most commonly from the right hepatic artery before dividing into anterior and posterior divisions. This implies that right hepatic artery chemoembolization, as the case in our patient, carries the highest risk of post TACE cholecystitis [6]. The pathogenesis of cholecystitis in TACE patients is related to gallbladder wall ischemia and infarction which is believed to be related to lipiodol embolization to the gallbladder wall [7].

For most cases, cholecystitis following TACE is a benign and self-limiting complication [6]. Patients usually do not require intervention and can be managed expectantly. However in cases such as ours, when there is evidence of gallbladder perforation or emphysematous cholecystitis, surgical intervention is mandatory [8].

Conclusion

We describe a case of emphysematous cholecytitis complicating a TACE procedure. Early imaging with ultrasound and computed tomography of the abdomen may be essential to assess patients with persistent abdominal pain following the procedure as serious pathology may exist underneath.

Author Contribution: TA and RM were responsible for literature review, preparation and final synthesis of the manuscript. GV was the attending physician on the case and the final reviewer of the manuscript. The authors obtained informed consent from the involved patient in the case. Emphysematous cholecystitis complicating atransarterial chemoembolization procedure.

References

1. Llovet JM, Real MI, Montana X, Planas R, Coll S, et al. (2002) Arterial embolization orchemoembolization versus symptomatic treatment in patient's withunresectable hepatocellular carcinoma: a randomized controlled trial. Lancet 359(9319): 1734-1739.
2. Lo CM, Ngan H, Tso WK, Liu CL, Lam CM, et al. (2002) Randomized controlled trial of transarterial Lipiodol chemoembolization for unresectable hepatocellular carcinoma. Hepatology 35(5): 1164-1171.
3. Clark T (2006) Complications of hepatic Chemoembolization. Semin Intervent Radiol 23(2): 119-125.
4. Hemingway AP, Allison DJ (1988) Complication of embolization: analysis of 410 procedures. Radiology 166(3): 669-672.
5. Takayasu K, Moriyama N, Muramatsu Y, Shima Y, Ushio K, et al. (1985) Gallbladder infarction after hepatic artery embolization. Am J Roentgenol 144(1): 135-138.
6. Wagnetz U, Jaskolka J, Yang P, Jhaveri KS (2010) Acute ischemic cholecystitis after transarterial chemoembolization of hepatocellular carcinoma: incidence and clinical outcome. J Comput Assist Tomogr 34: 348-353.
7. Yeung E, Jackson J, Finn JP, Thomas MG, Benjamin IS, et al. (1989) Acalculous cholecystitis complicating hepatic intraarterial Lipiodol: case report. Cardiovasc Intervent Radiol 12(2): 80-82.
8. Nakamura H, Kondoh H (1986) Emphysematous cholecystitis: complication of hepatic arterial embolization. Cardiovasc Intervent Radiol 9(3): 152-153.

How to cite this article: Talal A, RamziMulki, Gabor V. Emphysematous Cholecystitis Complicating a Transarterial Chemoembolization Procedure. JOJ Case Stud. 2017; 2(2) : 555584. DOI: 10.19080/JOJCS.2017.02.555584.

DOI: 10.19080/JOJCS.2017.02.555584

How to cite this article: Talal A, RamziMulki, Gabor V. Emphysematous Cholecystitis Complicating a Transarterial Chemoembolization Procedure. JOJ Case Stud. 2017; 2(2) : 555584. DOI: 10.19080/JOJCS.2017.02.555584.