

Review Article

Volume 12 Issue 1 - August 2018
 DOI: 10.19080/JOCCT.2018.12.555827

J Cardiol & Cardiovasc Ther

Copyright © All rights are reserved by Jagdish Butany

Aortic Stenosis: Causes and Management



Aisling Kinsella¹, Annamalar Muthu², Cusimano RJ³, Eric Horlick⁴ and Jagdish Butany^{5*}

¹Department of Cardiac Surgery, Toronto General Hospital -Peter Munk Cardiac Centre, Canada

²Interventional Cardiology, Toronto General Hospital -Peter Munk Cardiac Centre, Canada

³Cardiac Surgeon, University of Toronto, Canada

⁴Interventional Cardiologist, University of Toronto, Canada

⁵Pathologist, University Health Network and Canada

Submission: June 08, 2018; **Published:** August 22, 2018

***Corresponding author:** Jagdish Butany, Consultant Cardiovascular Pathologist, Co-Editor-in-Chief, Cardiovascular Pathology, Professor, University of Toronto, Canada, Fax: 416-586-9901; Tel: 416-340-3003; Email: jagdish.butany@uhn.on.ca

Keywords: Aortic valve; Valvular stenosis; Prosthetic heart valves; Complications of prosthetic heart valves

Introduction

Aortic stenosis is an underappreciated yet serious and growing conundrum. As the aging population increases the incidence of aortic stenosis will increase [1]. Clinicians are encouraged to participate in a “heart team” to personalise management for each patient. As the choice of biological and trans-catheter valves increases, selection of the optimum prosthesis for a given patient becomes more complex. The balance between procedural risk,

patient preference and available data on durability all contribute to this increased complexity.

Aortic Stenosis

a. Aortic stenosis causes a progressive obstruction to the outflow of blood from the Left Ventricular Outflow Tract (LVOT) to the aorta, due to the narrowing of the aortic valve orifice.

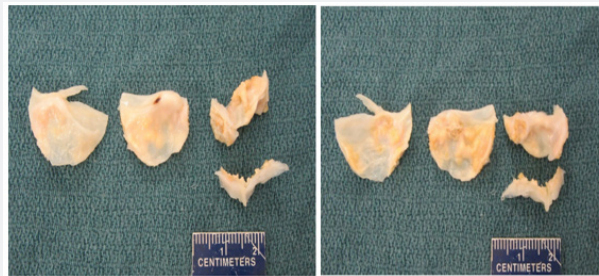


Figure 1A & B: Figs A and B are gross images of the flow and non-flow surfaces of this surgically excised three cusp aortic valve from 77-year-old male. All three cusps show diffuse thickening due to fibrosis and to multifocal calcification.

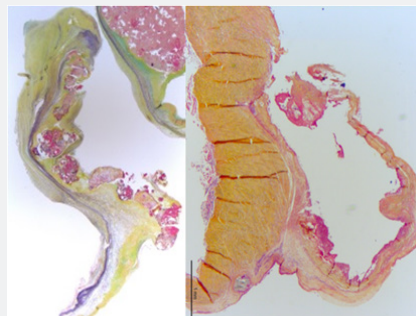


Figure 1C: This porcine aortic site bioprosthesis, shows a large tear (arrow). The adjacent cuspal tissues show thickening and finely nodular calcification. Fig B shows a histopathological image of one of the cusps with thrombus (arrow) adherent to the sinus surface of the cusp. (Stain-Movat pentachrome. Original magnification-x1.25).

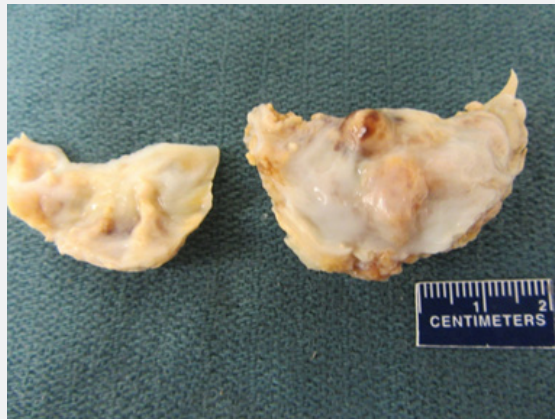


Figure 2A: shows a low power histopathological image of a longitudinal section of one cusp (a part of a second cusps section is seen in the upper right corner). The lowest part of the image shows the normal layers of a cusp, while the rest of the section shows fibrosis, thickening and multifocal calcification of the cusp, primarily in the zona fibrosa. (C. stain-Movat pentachrome. Original magnification-x1.25).

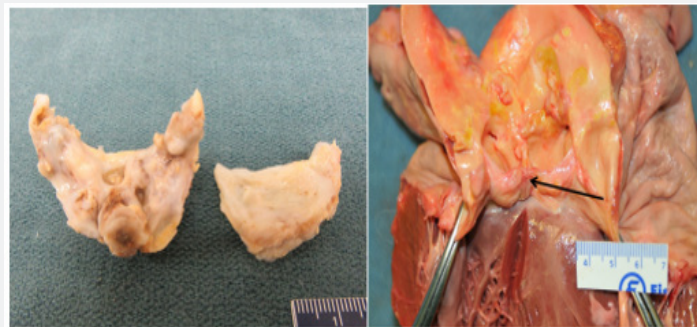


Figure 3A: Gross images of a surgically excised, congenitally bicuspid aortic valve. Both pieces of cuspal tissue show marked fibrosis, thickening and multifocal calcification. B shows the sinus surface and the raphe is seen at its middle. The latter is also markedly thickened and diffusely calcified.

b. The causes include; degenerative calcification of three cusp valves (Figure 1A-1C) congenital bicuspid valves (1-2% of population) (Figure 2A & 2B), and rheumatic fever (Figure 3). Each of the above results in the cusps showing increased fibrosis, thickening, stiffening and progressive multinodular calcification.

c. For people over the age of 75 years, the pooled prevalence of aortic stenosis is 3.4% [2].

d. Patients most commonly present with angina, syncope and dyspnea, however they may be asymptomatic. The degree of obstruction can be classified as mild, moderate and severe as per the AHA/ACC guidelines [3] (Table 1).

Table 1: Grading severity of aortic stenosis.

	Mild	Moderate	Severe
Aortic Jet velocity (m/s)	2.6-2.9	3.0-4	>4
Mean gradient (mmHg)	<20	20-40	>40
AVA (cm ²)	>1.5	1.0-1.5	<1.0

Indexed AVA (cm ² /m ²)	>0.85	0.6-0.85	<0.6
Velocity ratio	>0.5	0.25-0.50	<0.25

Table 2: Indications for surgery in aortic stenosis.

Class of Recommendation	Recommendations
1	Severe AS + symptoms Severe AS + asymptomatic + EF <50% Severe AS + other cardiac surgery
2a	Very Severe AS (velocity >5m/s) + asymptomatic Severe AS + asymptomatic + reduced exercise tolerance Severe AS + symptomatic + low-flow/low-gradient Moderate AS + other cardiac surgery
2b	Severe AS + asymptomatic + rapid disease progression

Obstruction of the LVOT causes an increase in left ventricle systolic pressure, symmetrical LV hypertrophy, reduced diastolic compliance and heart failure if untreated. Valvular aortic stenosis is progressive and life threatening. Once symptoms appear, untreated patients have a poor prognosis; they will experience worsening symptoms, eventually leading to death. After the onset

of symptoms, average survival is 50% at two years and 20% at five years [4]. The 2017 guidelines by the AHA/ACC summarise recommendations for intervention [3] (Table 2).

Choice of valve prosthesis depends on the patient's age, comorbidities, operative risk and individual preference (Figure 4A & B & 5A & B).

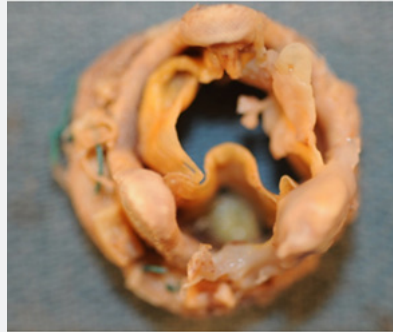

Figure 4A: The open left ventricular outflow tract, from a 57 year old man who had a history of rheumatic fever, shows the features of chronic rheumatic aortic valve stenosis. The cusps are thickened and somewhat prolapsed. The commissure (red arrow) is fibrosed, thickened and calcified.

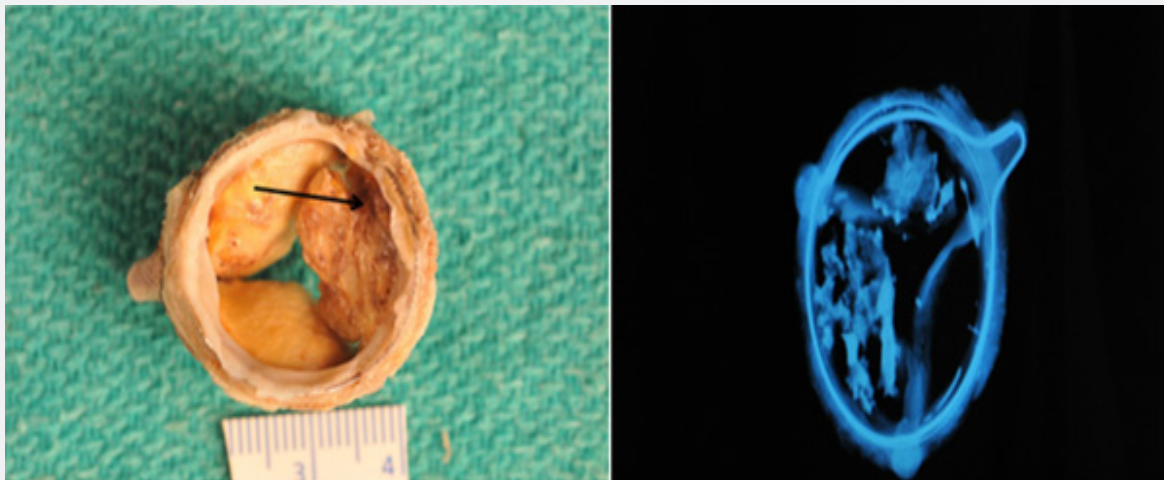


Figure 5A & B: This pericardial bioprosthesis was explanted at 11 years. It shows areas of fine nodularity, and thickening, with one cusp showing more pronounced change and this cusp shows a large tear (arrow). B. Anteroposterior X-ray image shows marked calcification of 2 cusps (arrow).

Tran Catheter Aortic Valve Implantation (TAVI) is indicated in patients with severe symptomatic AS who are not suitable for AVR as assessed by a "heart team" and should be considered in high risk patients who may still be suitable for surgery, but in whom TAVI is favoured by a "heart team" based on the individual risk profile [5]. Tran catheter Aortic Valve Implantation (TAVI) has undergone exponential technological improvements since the first successful implantation in 2002 for symptomatic severe aortic valve stenosis (AS) [6]. It is currently considered the standard of care for severe AS in patients who have high or prohibitive surgical risk, based largely on co-morbidities [5]. The indications for TAVI continue to expand now include additional patients and indications, such as those with intermediate surgical risk [7], valve-in-valve procedures [8] and bicuspid AS [9].

The transcatheter aortic valve prostheses can be divided into the Balloon-Expandable (BE) valve and self-expanding valve. A balloon-expandable aortic stent valve, consisting of a trileaflet bovine pericardial valve mounted in a stainless-steel frame, was the first BE valve prototype implanted in humans [6]. Subsequent improvements of the valve and the delivery systems resulted in a newer generations of BE prosthesis: Edwards SAPIEN®, SAPIEN XT® and SAPIEN 3® valves (Edwards Life sciences, Irvine, CA) [10,11]. The Core Valve, Evolute R® (Medtronic Inc; Minneapolis, MN), prototype of SE valves, is comprised of trileaflet porcine pericardial tissue sutured into a Nitinol® wire frame, a nickel-titanium alloy that has temperature-associated shape memory features (Figure 6A & 6B) [11]. The TAVI valves have potential for serious complications during implantation. (Figure 7A & 7B and Figure 8A & 8B) & (Figure 9).

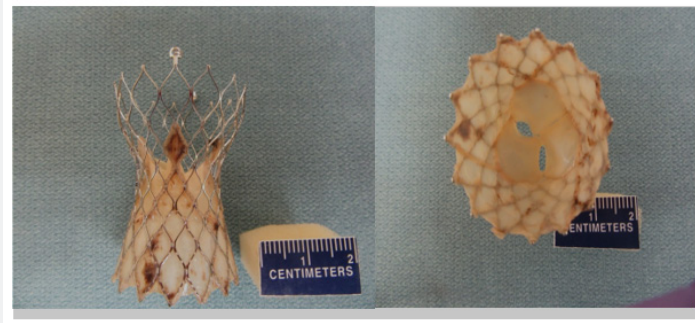


Figure 6A & B: Images of an explanted CoreValve © showing the pericardial cusps.

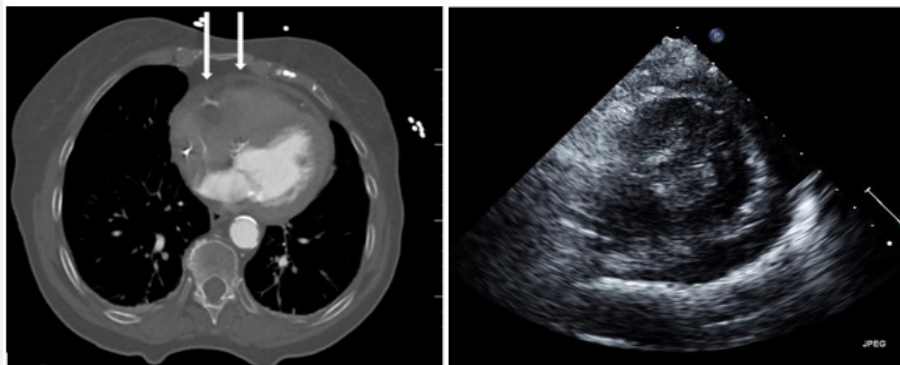


Figure 7A & B: A/. Patient post TAVR with small hemopericardium most likely secondary to wire injury. White arrow pointing to hemopericardium. B. Large pericardial effusion post TAVR secondary to annular rupture. White arrow pointing to pericardial effusion.

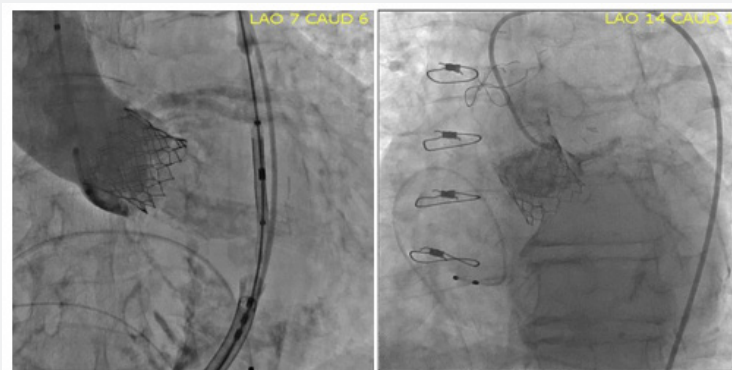

Figure 8A & B: Annular rupture post TAVR. White arrow pointing to extravasation of contrast around the Aortic annulus. B. Left Main Coronary Obstruction post TAVR.

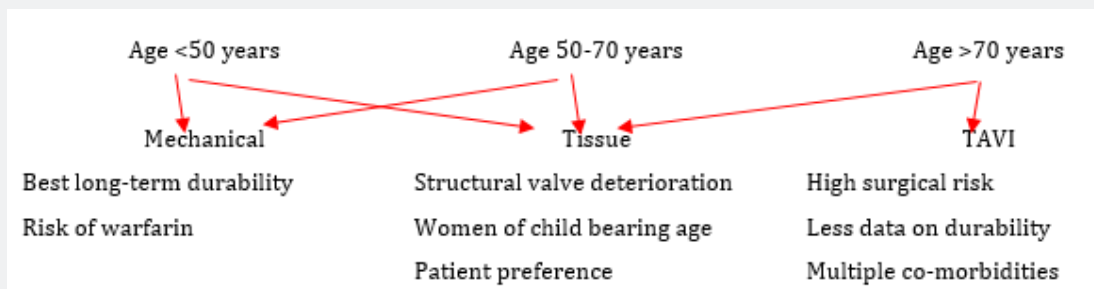


Figure 9: Choice of valve prosthesis based on age.

Newer self-expanding, balloon expanding and mechanical valves such as Lotus® (Boston Scientific, Natick, MA), Acurate® (Symetis SA, Ecublens, Switzerland), Portico® (St. Jude Medical, St Paul, MN) (Figure 8), Centera® (Edwards Life sciences, Irvine, CA), Engager® (Medtronic Minneapolis, MN) and Jena Valve® (Jena

Valve Technology GmbH, Munich, Germany), Colibri® (Colibri Heart Valve, Broomfield, USA), Innovare valve® (Brail Biomedical, Brazil) are the new kids on the block aiming to address potential limitations of earlier devices [12-17] (Table 3A & 3B).

Table 3A: Complications of prosthetic heart valve devices. Early (<30 days) [17].

Device	M-HVD	B HVP	TAVI
Paravalvular leak	Yes (rare)	Yes (rare)	Yes
Infection (IE)	Yes	Yes	Yes
Anticoagulant Problems	Yes	No	No (rare - minimal)
Persistent Gradient	Yes (mild)	Yes (mild)	No (rarely - minimal)
Prosthesis Dysfunction	Yes (rare)	Yes (rare)	Yes (rare)
Periaortic leak (aortic sinus / root rupture)	Yes (rare)	Yes (very rare)	Yes (rare)
Occlusion of Coronary ostium and acute MI	No	No	Yes (Rare)
Device “embolization”	No	No	Yes (rare)

Table 3B: Complications of prosthetic heart valve devices. Intermediate/Late.

Device	M-HVD	B-HVP	TAVI
Paravalvular leak	Yes (rare)	Yes (rare)	Yes rare
Infection	Yes	Yes	Yes
Prosthesis dysfunction - PTF	Yes very Rare	Yes	Yes*
Causes of prosthesis dysfunction (#3 above)	Thrombosis Materials failure-very rare	Tissue degeneration a) Cusp tear b) Cusp calcification	Yes*
Host Tissue Reaction	Yes - late impact	Yes - Impact significant	Yes*
Thrombosis / Embolism	Yes	Yes-but rare	*
Clinical Effect			
a) Stenosis	Yes	Yes (late)	*
b) Regurgitant	Yes	Yes	*
c) Combination	Yes	Yes	*
Structural Failure	Very rare	Yes	*

Conclusion

The gold standard for treatment of severe symptomatic aortic stenosis is aortic valve replacement. The choice of optimum valve prosthesis depends on patient age, comorbidities, individual preference and calculated operative risk. All valve prosthesis is associated with their own risks and benefits. Clinicians are encouraged to work in a collaborative effort to choose the best treatment option for each patient. As more prosthetic valve options are available it is the responsibility of the clinician to rigorously evaluate new devices for durability and associated complications. It is important that groups publish their negative as well as positive outcomes to further our collective knowledge and advance patient care.

References

1. Thaden JJ, Nkomo VT, Enriquez SM (2014) The global burden of aortic stenosis. *Prog Cardiovasc Dis* 56(6): 565-571.
2. Osnabrugge RLJ, Mylotte D, Head SJ, Van Mieghem NM, Nkomo VT, et al. (2013) Aortic stenosis in the elderly: Disease prevalence and number of candidates for transcatheter aortic valve replacement: A meta-analysis and modeling study. *J Am Coll Cardiol* 62(11): 1002-1012.
3. Bonow RO, Carabello BA, Chatterjee K, De Leon AC, Faxon DP (2008) 2008 Focused update incorporated into the ACC/AHA 2006 guidelines for the management of patients with valvular heart disease. *Circulation* 118(15): e523-e661.
4. Ross J, Braunwald E (1968) Aortic stenosis. *Circulation* 38(1 Suppl): 61-67.
5. Baumgartner H, Falk V, Bax JJ, De Bonis M, Hamm C, et al. (2017) ESC/EACTS Guideline for the management of valvular heart disease. *Eur Heart J* 38(36): 2739-2791.
6. Cribier A, Eltchaninoff H, Bash A, Borenstein N, Tron C, et al. (2003) Percutaneous transcatheter implantation of an aortic valve prosthesis for calcific aortic stenosis; first human case description. *Circulation* 106(24): 3006-3008.

7. Piazza N, Kalesan B, van Mieghem N, Head S, Wenaweser P, et al. (2013) A 3-center comparison of 1-year mortality outcomes between transcatheter aortic valve implantation and surgical aortic valve replacement on the basis of propensity score matching among intermediate-risk surgical patients. *JACC Cardiovascular Intervention* 6(5): 443-451.
8. Makkar RR, Jilaihawi H, Chakravarty T, Fontana GP, Kapadia S, et al. (2014) Determinants and outcomes of acute transcatheter valve-in-valve therapy or embolization: a study of multiple valve implants in the US partner trial (Placement of Aortic Transcatheter Valve Trial Edwards SAPIEN Transcatheter Heart Valve). *J Am Coll Cardiol* 62(5): 418-430.
9. Mylotte D, LT, SL (2014) Transcatheter aortic valve replacement in bicuspid aortic valve disease. *Journal of American College of Cardiology* 64: 2003-2009.
10. Ribeiro HB, Urena M, Allende R, Amat-Santos IJ, Rodés-Cabau J (2014) Balloon-expandable prostheses for transcatheter aortic valve replacement. *Prog Cardiovasc Dis* 56(6): 583-595.
11. Kumar R, Latib A, Colombo A, Ruiz CE (2014) Self-expanding prostheses for transcatheter aortic valve replacement. *Prog Cardiovasc Dis* 56(6): 596-609.
12. Meredith It, Kristin LH, Haratani N, Dominic JA, Keith DD (2012) Boston Scientific Lotus valve. *Euro Intervention* 8: 70-74.
13. Spence MS, Lyons K, McVerry F, Smith B, Manoharan GB, et al. (2013) New St. jude medical portico transcatheter aortic valve: features and early results. *Minerva Colangiologica* 61(3): 263-269.
14. Sundermann SH, Grünenfelder J, Corti R, Rastan AJ, Linke A, et al. (2012) Feasibility of the engager aortic transcatheter valve system using. *Eur J Cardiothorac Surg* 42(4): e48-e52.
15. Binder RK, Schäfer U, Kuck KH, Wood DA, Moss R, et al. (2013) Transcatheter aortic valve replacement with a new self-expanding transcatheter heart valve and motorised delivery system. *JACC Cardiovasc Interv* 6(3): 301-307.
16. Kempfert J, Rastan AJ, Mohr FW, Walther T (2011) A new self-expanding transcatheter aortic valve for transapical implantation first- in-man implantation of the jenavalve™. *Eur J Cardiovasc Surg* 40(3): 761-763.
17. Vongpatanasin W, David H, Richards AL (1996) Prosthetic heart valves. *N Engl J Med* 335(6): 407-416.



This work is licensed under Creative Commons Attribution 4.0 License
DOI: [10.19080/JOCCT.2018.12.555827](https://doi.org/10.19080/JOCCT.2018.12.555827)

Your next submission with Juniper Publishers will reach you the below assets

- Quality Editorial service
 - Swift Peer Review
 - Reprints availability
 - E-prints Service
 - Manuscript Podcast for convenient understanding
 - Global attainment for your research
 - Manuscript accessibility in different formats
- (Pdf, E-pub, Full Text, Audio)**
- Unceasing customer service

Track the below URL for one-step submission

<https://juniperpublishers.com/online-submission.php>