

Case Report

Volume - 11 Issue 1 - November 2018
DOI: 10.19080/JFSCI.2018.11.555804

J Forensic Sci & Criminal Inves

Copyright © All rights are reserved by Sabyasachi Nath

Why Murder After Rape?



Sabyasachi Nath* and HK Pratihari

State Forensic Science Laboratory, Tripura, India

Submission: October 29, 2018; Published: November 09, 2018

*Corresponding author: Sabyasachi Nath, State Forensic Science Laboratory, Tripura-799015, India; Email: drsabyasachinath@gmail.com

Abstract

The murder and rape are two major heads under different crimes in India. It is seen women are vulnerable to sexual violence reported in the age group from seven months to seventy year old even physically/mentally handicapped. There is also report that in some sexual offence cases, the rape victim is murdered after having sex desire (rape). Such crime is committed by the rapist to conceal his identity and also to escape punishment. In one case, a disabled girl developed sexual relation with her boyfriend having assurance of marriage. The physical relation continued for a long time, was the only motive to enjoy sex. One day, after usual physical relation, the girl (victim) insisted to fix a date to solemnize the marriage. There was hot altercation between two because of disinterest in marriage. Subsequently, the girl (victim) threatened her boyfriend to lodge complaint to the police. Being upset, the boy friend lost his mental balance and fearing shame and harsh punishment, in a fit of anger strangulated the girl resulting death. The body was dragged and left in an abandoned place. On the following day, police got the information about detection of a dead body. The police and forensic team visited the undisturbed crime spot for investigation. The physical evidence detected in the case and their examination could help to nab the suspect. The details have been discussed in this paper.

Keywords: Disabled girl; Strangulation; Crime spot; Physical evidence; Autopsy study

Introduction

The crimes under head rape and murder are very alarming in India. As per National Crime Records Bureau (NCRB) report, there were 38,947 rape and 30,450 murder cases registered in the year 2016 [1]. The incident of rape followed with murder is very less; as such the statistics on such cases are not available in literature. But it is seen women of different age groups are victims of such crime and take place indoor/outdoor/moving vehicle even in custodial place [2]. There are different following factors to kill the victim after having sex [2-4]:

- a. To satisfy sex desire (lust) and wipe out evidence by killing
- b. Honor killing
- c. Serial killing after having sex (Promiscuous sexual behavior)
- d. Ritual/occult belief among women disciple
- e. Resulting pregnant of the victim being raped several occasion
- f. Destroy oral witnesses of rape victim to escape arrest by the police and harsh punishment
- g. Satisfy sadistic pleasure

- h. Opposition from both families (different communities) to wipe out love-pact by killing
- i. Distance between rape-murder is wafer-thin
- j. Anger rape

Statistics reveal violence against women are considerably in increasing order due to various social, economic and other factors like lack of education, poverty, male dominance, workplace harassment, extra marital affair, etc. [5]. But there is no exact figure available on rape followed with murder in record since such heinous crimes are very less and rarely reported. In such crime cases, very often the emotional distress of the rapist found aggressive and violent resulting in murder of the victim after committing rape.

Case Report

A disabled unmarried girl developed sex relation with a boyfriend. Both are resident of the same village. The physical relation continued since the boy promised to marry her. One day, in the evening hour after having sex, the girl insisted to solemnize the marriage. There was hot discussion between two and the disabled girl threatened to lodge complaint to the police. Hearing such threat, the boy was upset, lost his temper and cruelty overpowered. Subsequently, in a fit of anger

manually strangulated her to death and abandoned the body. On following day having seen a half-naked dead body, the villagers informed the police. Subsequently the police and forensic team investigated the crime spot to collect physical evidence for forensic evaluation to establish the crime/criminal.

Observation

The sketch map of the crime scene showing position of the deceased and other features on and around the dead body are shown in Figures 1-5.

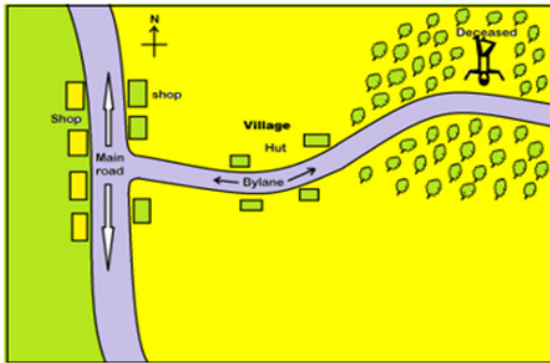


Figure 1: Sketch map of the crime scene showing exact location of dead body (victim girl).



Figure 2: The half-naked victim girl with tilted face lying dead on the floor of a bushy area.

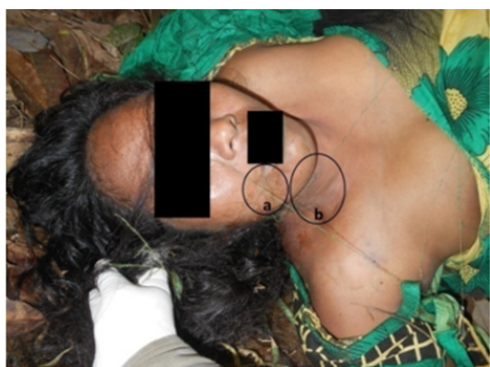

Figure 3: Victim with congested face, salivation from the right corner of the mouth (a) and bruises around the neck (b).

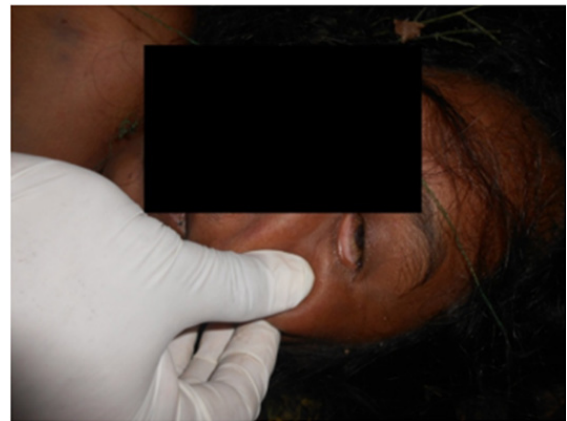

Figure 4: Victim having sub-conjunctival hemorrhage.



Figure 5: A pair of slippers near the spot suspected to be abandoned by the suspect.

Forensic evidence on the spot observed

The crime spot visit reveals the following points:

- a. Victim lying dead in half naked position on the floor of a bushy area in an isolated place
- b. Presence of bruises around the neck and in the chest
- c. Face was congested and tilted towards right side
- d. There was salivation from right corner of the mouth
- e. Eyes were partially open
- f. Bleeding present near the private organs
- g. Soil beneath the dead body was stained with blood (spot test by Tetramethyl Benzidine found positive)
- h. No loose hair could be detected
- i. Vaginal swab to be preserved for forensic analysis to match with the suspect
- j. Some overlapping foot prints were present on the ground, but not suitable for examination/comparison
- k. Sign of dragging was present on the spot

1. A pair of slippers was found on the spot suspected to be abandoned by the suspect. Sweat swab from the slipper to be analyzed for matching with the suspect.

Autopsy Findings

External

Body of the deceased was average, stout; eyes and mouth were partially closed; mild frothing from mouth was present; post mortem lividity was present over the back; bruises were present around the neck and in the chest wall at sternal area; vaginal bleeding was also present; and hymen was found ruptured.

Internal

On dissection, all the organs were found congested. On dissection of neck, there was fracture of hyoid bone and engorgement of the tissue at the level of compression present. No abnormality was detected in scalp, skull, vertebrae, brain and spinal cord. Peritoneum, lungs, pericardium, heart, stomach, small intestine, large intestine, liver, spleen and kidneys were found congested. In the stomach, undigested food particles were found.

Cause of death

Cause of death was asphyxia and cardiac arrest due to occlusion of carotid arteries followed by throttling/manual strangulation.

Discussion

There is alarming number of rape cases registered every year, but incident of rape-murder cases are comparatively less.

In this case, the love bond was not strong and heavenly between the love couple. The boyfriend (accused) made the physical relation only to fulfill his sex desire/lust. Had there been true love the situation would not have been heinous. However, the accused fearing allegation to be made to the police, in a fit of anger strangulated and killed with a motive not to be identified by the victim if alive. In such situation, the motive of the killer appears to be psychopath, lack of remorse and empathy having promiscuous sexual relation behavior. The profile of the criminal is unique in this case. However, forensic results, autopsy findings and other circumstantial evidence could establish the crime and criminal beyond doubt in this case.

Acknowledgment

The authors are thankful to the autopsy surgeons for providing necessary documents

References

1. National Crime Records Bureau (2016) Ministry of Home Affairs, Government of India.
2. Nath S, Pratihari HK (2018) Gang Rape and Murder – A Case Report. *J Forensic Sci & Criminal Inves* 10(1): 1-4.
3. Fisher, Barry AJ (2004) *Techniques of crime scene investigation*. Seventh Edition, CRC Press LLC, Boca Raton, USA.
4. Becker, Ronald F (2009) *Criminal Investigation*. Third Edition, Jones and Bartlett Publishers, Sudbury, Massachusetts, USA.
5. Master's Thesis: Factors that contribute to the violence against women: a study from Karachi, Pakistan: MA, Peace and Development Studies (4FU42E): Author: Eraj Khurram, Supervisor: Christopher High, Examiner: Heiko Fritz.



This work is licensed under Creative Commons Attribution 4.0 License
DOI: [10.19080/JFSCI.2018.11.555804](https://doi.org/10.19080/JFSCI.2018.11.555804)

Your next submission with Juniper Publishers will reach you the below assets

- Quality Editorial service
- Swift Peer Review
- Reprints availability
- E-prints Service
- Manuscript Podcast for convenient understanding
- Global attainment for your research
- Manuscript accessibility in different formats
(Pdf, E-pub, Full Text, Audio)
- Unceasing customer service

Track the below URL for one-step submission

<https://juniperpublishers.com/online-submission.php>