

Case Report

Volume 2 Issue 2 - August 2017
DOI: 10.19080/GJORM.2017.02.555581

Glob J Reprod Med

Copyright © All rights are reserved by Otheman Fahs

Semenoma Originated from an Ectopic Testis



OthemanFahsi¹, Hafssa El Ouazani², Adil Kallat¹, Amine Kessab², Hicham Ouazize¹, Amine Slaoui¹, Fouad Zouaidia², Hachem El Sayegh¹, Ali Iken¹, LounisBenslimane¹ and Yassine Nouini¹

¹Department of Urology, Hospital Ibn Sina, Morocco

²Department of Anatomic Pathology, Hospital Ibn Sina, Morocco

Submission: June 12, 2017; Published: August 09, 2017

*Corresponding author: Otheman Fahs, Department of Urology, Hospital Ibn Sina, CHU Rabat, Morocco; Email: othefahsi@gmail.com

Abstract

The authors report an observation of a meta static seminoma on an ectopic testicle in a 23 years old patient and discuss the epidemiological, diagnostic, therapeutic and evolutionary aspects of this entity. Clinical diagnosis is often difficult due to the diversity of clinical symptoms, the use of imaging, biological markers and percutaneous biopsy essential to make the diagnosis. The anatomopathology and therapeutic aspects are similar to the testis in normal situations. Early diagnosis of these tumors involves the lowering of the cryptorchid testicles, because even if this lowering does not prevent the setumors, it allows better monitoring.

Keywords: Ectopic testicle; Abdominal Mass; Semenoma

Introduction

Abnormal testicular migration occurs in 2-5% of boys, with most cases unilateral (90%). In 20% of cases the testicle is not palpable, of which 20% are absent [1]. Intra-abdominal localization is less frequent but has a higher risk of malignant degeneration compared to the testis in the inguinal canal. This risk of degeneration varies between 30 to 40% of cases and most are germ-cell tumors; Semenoma being the most frequent [2].

Case Report

A young man of 23 years without significant pathological history has been present for 6 months bilateral low back pain especially on the left, progressive aggravation the whole evolving in a context of alteration of the general state. The clinical examination revealed a mass of the left iliac fossa fixed and sensitive, with a vacuity of the left purse making suspect a tumor on ectopic testicle. The right testicle was in place. The rest of the examination is unique.

The biological balance found

HCGt: 62.59 ui / ml, aAFP: 3.91 ui / ml, and LDH: 839.4 ui / l

Abdominal ultra sound showed a mass of the left iliac fossa with left uretero-hydro nephrosis. The thoraco-abdomino-pelvic CT scan (Figure 1) demonstrated a left lateral-vesical mass of retro peritoneal extension tissue compatible with a malignant process on the ectopic testicle with a retro peritoneal abdominal

lymph adomectomyencom passing large vessels and A left uretero-hydronephrosis (Figure 2). Surgical exploration revealed a voluminous left lateral-vesical poly lobal testicular tumor. The anatomopathological examination concluded in a seminome on ectopic testicle with invasion of the epididymis and infiltration of the albuginea without lympho-vascular invasion. The patient received just after 3 BEP cures (bleomycin, etoposide, cisplatin). The thoraco-abdomino-pelvic CT scan and tumor control markers were not shown to have residual mass.

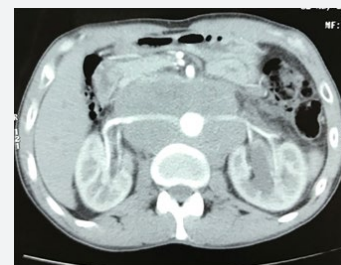

Figure 1: left lateral-vesical mass of retroperitoneal compatible with a malignant process on the ectopic testicle.

Surgical exploration revealed a voluminous left lateral-vesical testicular tumor (Figure 3). The anatomopathological (Figure 4) examination concluded in a seminome on ectopic testicle with invasion of the epididymis and infiltration of the albuginea without lympho-vascular invasion. The patient received just

after 3 BEP cures (bleomycin, etoposide, cisplatin). The thoraco-abdomino-pelvic CT scan and tumor control markers were not shown to have residual mass.

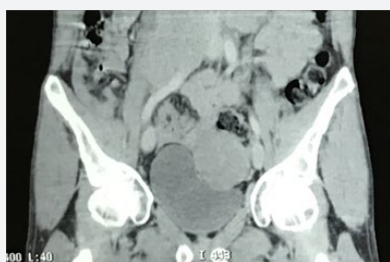

Figure 2: Retroperitoneal abdominal lymph adomectomyencom passing large vessels and A left uretero-hydro nephrosis.

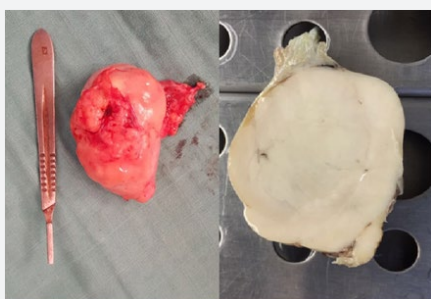


Figure 3: Surgical specimen and aspect macro scopique: Tumor of whitish appearance with invasion of the epididymis and infiltration of the albuginea.

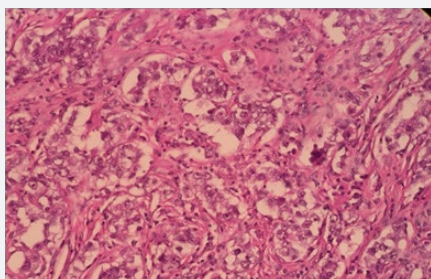


Figure 4: Aspect microscopique: embryonal cells with oval nuclei and clear cytoplasm and typical focal lymphocyte infiltrate.

Discussion

Gerster described in 1897 the first case of torsion of an intra-abdominal testicular tumor. It is an exceptional event. Nearly one in 500 men have an undescended testicle and some complications such as cancer, ischemia, infertility and torsion can be caused. Since the 1940's cryptorchidism and testicular germ cell tumors (TGCT) association has been well-documented. Because of the heat and other environmental insults on the gonads, the relative risk of developing TGCT is 3.7-7.5 times higher for a cryptorchid testis than normal intra scrotal testis [3]. That's why an abdominal testis presents a greater risk for TGCT than an inguinal testis [4]. Seminoma is the most common single histologic type of germinal testicular neoplasms. Nevertheless

5-10% of testicular tumours occur in the contra lateral, normally descended testis. Contrary to popular belief or chiopexy does not alter the malignant potential of the cryptorchid testis; Indeed, it only facilitates examination and tumour detection [5]. We describe three clinical stages for the extension of the tumour.

In the first one the tumour is limited to the testis with or without invasion of epididymis or the spermatic cord. While for the second stage the tumour has retroperitoneal lymphnode metastases. And finally with regard to the third Stage tumour has distant metastases. Seminoma has a high metastatic potential especially as it is highly predictable. Indeed, lymphatic metastases concern the retroperitoneal ganglia before an additional systemic implantation [6]. Finally, if the metastasis sites were to be classified in decreasing order of frequency, the retroperitoneal lymphnodes, the lungs, the liver, the mediastinal lymphnodes, the brain, the kidney, the gastrointestinal tract -intestinal, bones, adrenals, peritonoma and finally the spleen [7]. It is important to remember that unlike other germ cell tumors, the choriocarcinoma, is characterized by an early hematogenous spread. The main possible prognostic factors in the treatment of seminomas are age, tumor size, lymphovascular invasion, number of mitotics, necrosis, percentage of giant cell and tumour in filtrating lymphocytes [8].

Clinical presentations of intra-abdominal malignant testicles may range from asymptomatic mass to symptoms simulating an acute abdomen: appendicitis a strangulated hernia. Sometimes it mimics a simple urinary infection or dysuria by mass effect on a bladder or retroperitoneal heaviness [9]. The radiological and preoperative diagnosis of torsion of the intra-abdominal testicular tumor is rare and often difficult. Indeed, at the time of the anamnesis the cryptorchidia is not found and the imaging characteristic scan be non-specific.

This is why mindful interrogation, thorough physical examination of the abdomen and genital organs, heed ful reading of radiological films and, above all, awareness of such complications badly lowered testicle. All this will improve diagnostic performance.

Conclusion

Any abdominal mass in a patient with a testicular migration abnormality, requires the clinician to suspect germ cell tumor regardless of the value of the tumor markers. A percutaneous biopsy may be indicated to prove the existence of germ cells. Only early diagnosis of undescended testicles and their lowering in the bursa make it possible to avoid such clinical forms.

References

- González Méndez M, Solís Alfonso L, González López A, RamírezSimono M (2010) Seminomatesticular intra abdominal. Reporte de un caso. Actas Urol Esp. 34n.3
- Mishari HA (2010) A gyant intra abdominal testicular seminoma. Biomedicalresearch 21(3): 227-229.

3. Thorup J, McLachlan R, Cortes D, Nation TR, Balic A, et al. (2010) What is new in cryptorchidism and hypospadias – A critical review on the testicular dysgenesis hypothesis. *J Pediatr Surg* 45(10): 2074-2086.
4. Cortes D, Thorup JM, Visfeldt J (2001) Cryptorchidism: Aspects of fertility and neoplasms. A study including data of 1,335 consecutive boys who underwent testicular biopsy simultaneously with surgery for cryptorchidism. *HormRes* 55(1): 21-27.
5. Canakli F (2010) Cancer and Fertility: Long term Cryptos of Cryptorchidism. *TurkUrol Sem* pp : 56-59.
6. Nguyen MM, Corr AS, Evans CP (2004) Testicular cancer metastatic exclusively to the brain and spleen. *Urology* 63(1): 176-178.
7. Johnson DE, Appelt G, Samuels ML, Luna M (1976) Metastases from testicular carcinoma. Study of 78 autopsied cases. *Urology* 8(3): 234-239.
8. Imaz AY, Bayraktar B, Sagioglu J, Gucluer B (2011) Giant seminoma in an undescended testis presenting as an abdominal wall mass. *J Surg Case Rep* (12): 9.
9. Manisha M, Satyanarayana S, Anindita M, Rao KV, Rao GB (2009) Seminoma of undescended testis presenting as acute abdomen. *Indian J Pathol Microbiol* 52(2): 278-280.



This work is licensed under Creative Commons Attribution 4.0 License
DOI: [10.19080/GJORM.2017.02.555581](https://doi.org/10.19080/GJORM.2017.02.555581)

Your next submission with Juniper Publishers will reach you the below assets

- Quality Editorial service
- Swift Peer Review
- Reprints availability
- E-prints Service
- Manuscript Podcast for convenient understanding
- Global attainment for your research
- Manuscript accessibility in different formats
(Pdf, E-pub, Full Text, Audio)
- Unceasing customer service

Track the below URL for one-step submission
<https://juniperpublishers.com/online-submission.php>