

Staining in Tympanoplasty; Is Methylene blue Rationale?

Bhushan Kathuria^{1*}, Himani dhingra², Joginder gulia¹, Vikas kakkar¹, SPS Yadav¹, Sharad Hernot³ and Surender bishnoi¹

¹Department of Otolaryngology and Head and Neck Surgery, Pt. B D Sharma PGIMS, India

²Department of Paediatric, KEM Hospital, Lower Parel, India

³Department of Otolaryngology and Head and Neck Surgery, Maulana Azad Medical College, India

Submission: November 05, 2015; **Published:** November 30, 2015

***Corresponding author:** Bhushan kathuria, Department of Otorhinolaryngology and Head and Neck Surgery, Pt. B D Sharma. PGIMS Rohtak, India, Email; kathuriabhushan56@gmail.com

Abstract

Objective: Is there any advantages of using methylene blue in myringoplasty? To compare the results of methylene blue stained temporalis fascia graft with unstained temporalis fascia graft in underlay myringoplasty.

Materials and Method: In this prospective study, 120 patients of either sex in age group of 15-50 years with non-cholesteatomatous chronic suppurative otitis media (CSOM) were recruited. Patients were initially managed medically to make the ear dry and after that they were operated upon. Sixty patients underwent underlay myringoplasty using methylene blue stained temporalis fascia graft and 60 patients underwent underlay myringoplasty using unstained temporalis fascia graft. Follow-up period was at least 6 months.

Results: Graft uptake and hearing improvement was comparable in both groups. Although there was 10% higher graft uptake using methylene blue stained temporalis fascia (95%) as compared to unstained temporalis fascia graft (85%), however the difference was not statistically significant ($P = 0.5$). But there was statistically significant difference in gain in hearing threshold (gain in A-B gap) in the myringoplasty using methylene blue stained temporalis fascia graft ($18 \text{ dB} \pm 7.156$) as compared to myringoplasty using unstained temporalis fascia graft ($13.7 \text{ dB} \pm 5.70814$) ($P = 0.04$).

Conclusion: Methylene blue use in myringoplasty allows improved identification of the graft, can be very helpful for trainee residents and reduce the time of a graft placement. Also, methylene blue as an antioxidant and antimicrobial properties, prevents degradation and lysis of fascia graft, improves the overall success rate of graft uptake with no adverse effects.

Keywords: Methylene blue; Temporalis Fascia; Underlay; Myringoplasty

Introduction

Chronic suppurative otitis media (CSOM) is an inflammatory process of the mucoperiosteal lining of the middle ear cleft. Infection of the middle ear has been encountered in the human's race, since humanity itself.¹ Myringoplasty i.e. surgical repair of a perforated tympanic membrane is the most frequently performed otologic surgery. An adequate area of contact between graft and tympanic membrane remnant is fundamental to the successful closure of any perforation. Graft failure is considerably higher in anterior perforation, large perforation and more so by the dexterity of grafts placement. The need to clearly identify the graft is heightened more so for the trainee residents or less experienced surgeons in relation to margins of

perforation, as the better a grafts is visualized, the better it will be placed to resist disruptive forces. This study was carried out to compare the results of methylene blue stained temporalis fascia graft with unstained temporalis fascia graft in myringoplasty in terms of graft uptake and gain in hearing threshold in inactive mucosal CSOM.

Materials and Method

In this prospective study 120 patients of either sex in age group of 15-50 years with non-cholesteatomatous chronic suppurative otitis media (inactive mucosal otitis media) were recruited during the period of January 2012 to January 2015 from the outpatient clinic of Otorhinolaryngology department,

Pt. B.D. Sharma post graduate institute of medical sciences, Rohtak (India)

Patients were divided into 2 groups randomly.

Group I (n=60) patients were operated by underlay myringoplasty using methylene

blue stained temporalis fascia graft.

Group II (n=60) patients were operated by underlay myringoplasty using unstained

temporalis fascia graft.

Informed consent was obtained from every patient and ethical approval was granted for the study by institutional ethical committee.

Inclusion Criteria: Patients in the age group of 15-50 years, uncomplicated (central) perforation of pars tensa, dry perforation for at least 4 weeks prior to surgery, absence of cholesteatoma and air bone gap more than 25 db on pure tone audiogram.

Exclusion Criteria: Patients with history of ear surgery in the past having age <15 years and >50 year with conductive hearing loss >60dB, actively discharging ear, cholesteatomatous ear, marginal or attic perforation, marked deviated nasal septum & active sinus disease.

All the patients were subjected to full history taking including onset, course, and duration of the disease, associated symptoms, previous medications, and operations. Patients were subjected to full otological examination to exclude scar of previous operation, condition of the tympanic membrane, condition of the middle ear mucosa, tuning fork tests (rinne's, weber and absolute bone conduction test), and also nasal and oral examination along with x-ray imaging to exclude predisposing factors like, sinusitis, tonsillitis etc.

All patients were subjected to preoperative pure tone audiometry and it was repeated 6 months postoperatively. Routine preoperative laboratory investigation was done for all patients as required for surgery. If the ear was not already dry patients were given oral and topical antibiotics to ensure that the ear was not discharging or remained dry for at least 1 month before surgery.

All the patients were operated via permeal or transcanal approach. The graft was harvested via horizontal incision and was spread on the slide. Then, 1 mL of 1% MB was dropped on the graft. Only one surface of the graft was stained with methylene blue. The dried stained graft was rinsed briefly with saline just before its placement to give it optimal flexibility & the graft regained bluish color as it was observed that the color of the graft got faint on drying.

After usual de-epithelization of margins of perforation, permeal incision was given and the tympanomeatal flap was elevated.

In Group-1: Graft was advanced with the stained side facing laterally under the tympanomeatal flap and under the malleus handle to the anterior most extent of the perforation and the edges of the graft was tucked under the margin of the drum remnant (Figure 1). Gelfoam soaked in antibiotic solution will be placed lateral to the tympanic membrane.

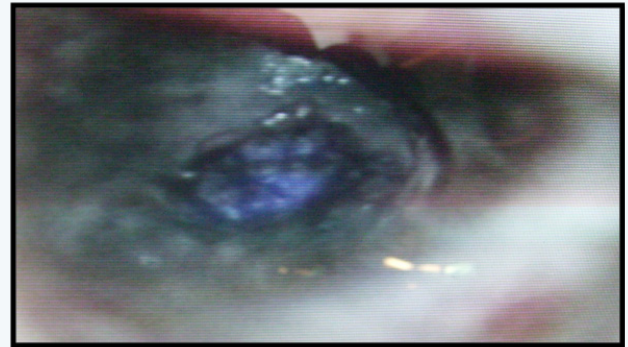


Figure 1: Methylene blue stained underlay temporalis fascia graft in place.

While in Group- II, Unstained temporalis fascia graft was placed by same technique. Gelfoam soaked in antibiotic solution will be placed lateral to the tympanic membrane.

Patients were operated upon by the same surgeon and all patients were followed for at least 3 months after the operation.

Post-operatively the patients were given, tablet amoxicillin +clavulanic acid 1 gm to times a day and tablet levocetirizine 5 mg once in day for seven days and tablet ibuprofen 400 mg three times a day for 3 days.

Patients were discharged from the hospital after 24 hours of surgery. All the patients at the time of discharge were instructed to take adequate precautions to prevent the entry of water into the ear canal. They were advised to avoid blowing of nose and lifting heavy weights. Further follow up was done on out-patient basis. All the operated patients were regularly followed up for a minimum period of 6 months in the out-patient department.

On 10th post-operative day, the sutures were removed along with pack from the external auditory canal. Any evidence of infection was looked for. Patients were advised to keep the ear dry. At 4th week the meatus was examined for any gel foam, and if present it was removed. Condition of the graft was noted regarding take-up, residual perforation or rejection. Thereafter, the patient was followed up for 6 months until the graft uptake could be finally assessed and a pure tone audiogram was taken at the frequency of 500 hz, 1Khz, 2Khz and 4Khz and A-B gap was calculated.

Collection of Data and Statistical Analysis

All collected clinical sheets from the patients were revised for completeness and consistency. Data was summarized using mean, and standard deviation for quantitative variables and

frequency and percentage for qualitative ones. Comparison between groups was performed using independent sample *t*-test for quantitative variables and Chi-square test for qualitative ones.

Paired *t*-test was conducted to signify the changes in the related quantitative measurements (Air–Bone gap). *P* values less than 0.05 were considered statistically significant, and less than 0.01 were considered highly significant.

The study included 120 patients who were divided randomly into two groups; group 1 (myringoplasty using methylene blue stained temporalis fascia graft) included 60 patients where 24 were males and 36 were females. Group 2 (myringoplasty using unstained temporalis fascia graft) also included 60 patients where 39 were males and 21 were females. All the patients were in the age group of 15-50 years, 63 males and 57 females with mean age 23.04±5.296 and 31.73±9.0728 respectively in two groups.

The most common presenting symptoms of these patients were otorrhea and hearing loss.

In group I, patients were complaining of ear discharge for 0-3 years -27(45%), 4-6 years -27 (45%) and 06(10%) were complaining of ear discharge for 7-8 years.

In group II, 15 % of cases were having ear discharges for 0-3 years, 50% had discharge for 4-6 years and 35 % had discharge for 7-9 years (Table 1).

Table 1: Duration of Ear Discharge.

Duration (Years)	Total Number of Patients	
	Group I	Group II
0-3	27 (45%)	09 (15%)
4-6	27 (45%)	30(50%)
7-9	06(10%)	21(35%)

Based on the pure tone audiogram, hearing loss was classified as mild (25-40 dB), moderate (41-55dB), moderately severe (56-70dB), severe (71-90dB) or profound (>90 dB).

In group I, 35% of patients were having hearing loss in the range 25-40db, 55 % of patients were having hearing loss in the range 41-55db and 10 % of patients were having hearing loss in the range 56- 70Db (Figure 2).

In group II, 90 % of patients were having hearing loss in the range of 25-40dB, 10 % of patients were having hearing loss in the range 41-55dB (Table 2).

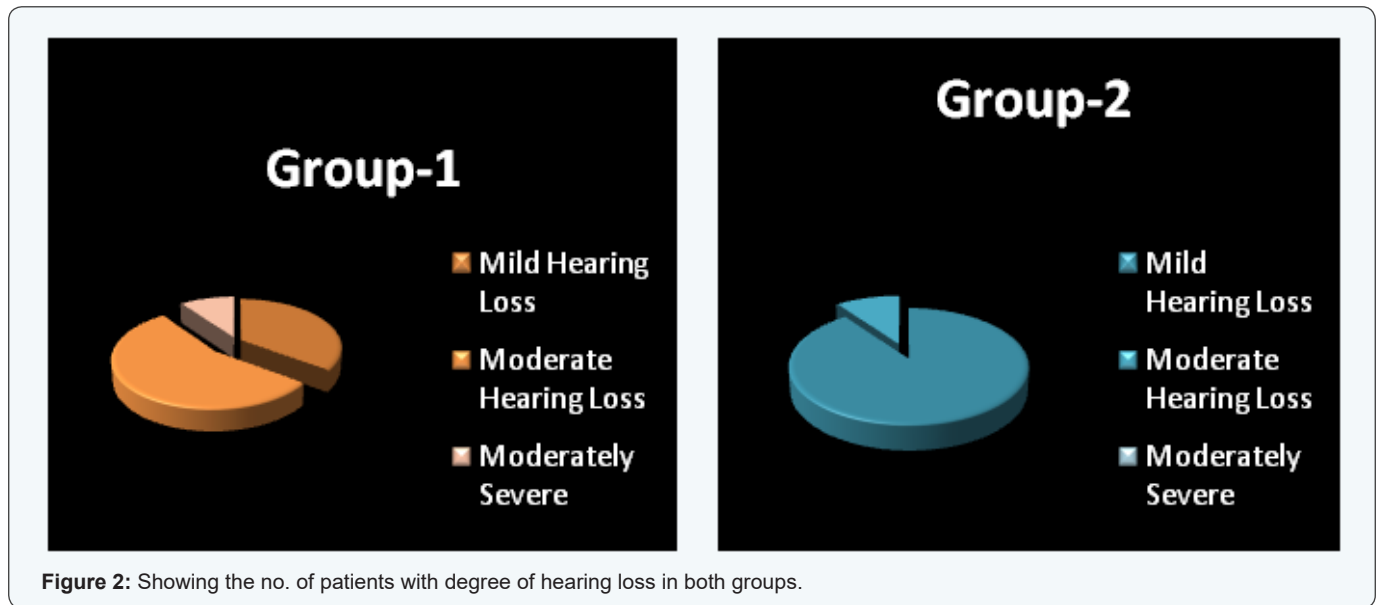


Figure 2: Showing the no. of patients with degree of hearing loss in both groups.

Table 2: Pre Operative Hearing Assessment.

Degree of Hearing Loss	Hearing Loss in dB	Total Number of Patients	
		Group I	Group II
Mild	25-40 db	21(35%)	54(90%)
Moderate	41-55 db	33(55%)	06(10%)
Mod Severe	56-70 db	06(10%)	00
Severe	71-90 db	00	00
Profound	>90 db	00	00

Otoscopic examination was done and size of perforation was assessed.

Group I

Eighteen (30%) cases had subtotal perforation (Grade-V) whereas 27(45%) cases had large central perforation (Grade-IV). Rest of the patients (25%) had medium size perforation (Grade-III)

Group II

Nine (15%) cases had subtotal perforation, whereas 15 (25%) cases had large central perforation. While, 60% patients had medium size perforation (Figure 3).

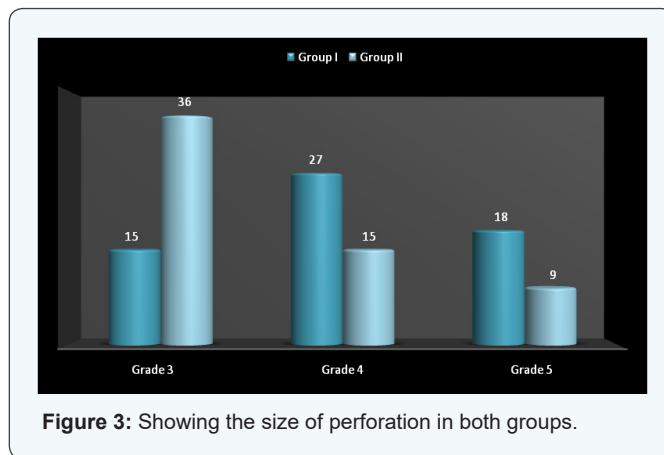


Figure 3: Showing the size of perforation in both groups.

Follow up examination and Results

All patients were followed up on 10th day for suture and pack removal. Suture site and external ear were examined for any

discharge or pus. In all patients, no discharge or pus was noticed on 10th day in both groups. Otoscopic findings are described in Table 3 & 4.

Group - I

Table 3: Follow-Up Examination and Results.

Otoscopic Findings	10 th Day	4 th Week	3 rd Month	6 th Month
1. Intact Graft	-	54 (90%)	57 (95%)	57 (95%)
2. Anterior sulcus blunting	-	-	-	-
3. Graft lateralization	-	-	-	-
4. Discharge	-	6(10%)	-	-
5. Residual perforation	-	-	-	-
6. Graft Rejection	-	-	3(5%)	1(5%)

Group - II

Table 4: Follow-Up Examination and Results.

Otoscopic Findings	10 th Day	4 th Week	3 rd Month	6 th Month
1. Intact Graft	-	54 (90%)	54 (90%)	54 (90%)
2. Anterior sulcus blunting	-	-	-	-
3. Graft lateralization	-	-	-	-
4. Discharge	-	06 (10%)	-	-
5. Residual perforation	-	-	-	-
6. Graft Rejection	-	-	06 (10%)	06 (10%)

All patients presented themselves for regular follow up. Discharge was noted in 6 patients which resolved by change of antibiotic and only 3 patient had graft rejection in group-I. While in group II discharge was noted in 6 patients which resolved by change of antibiotic and 6 patients had graft rejection with residual perforation (Table 3 & 4).

In group I graft uptake was 100% in both grade III and grade

V perforations and in group II graft uptake was 91.6 % for grade III perforations and & 66.6 % for grade V perforations. While in grade IV perforation, graft uptake was 100% in both groups but there is small residual perforation in anterior-inferior quadrant region in a patient in group I (Table 5). On applying chi square test, value was 4.919 with degree of freedom value 2. The p value was 0.0855 which was statistically insignificant.

Table 5: Relationship between Graft Take up and Size of Perforation.

Size of Perforation	Total Number of Cases	
	Group I	Group II
Grade I		
Grade II		
Grade III	15/15(100%)	33/36(91.6%)
Grade IV	24/27(88.8%)	15/15(100%)
Grade V	18/18(100%)	06/09(66.6%)
Oval All	57/60(95%)	54/60(90%)

Hearing assessment: Hearing levels were assessed at 6 months

Group I

The average preoperative hearing threshold was 45.69 db while the average postoperative hearing threshold was 27.69 db. The average gain in hearing threshold was 18 dB. The average preoperative A-B gap was 32.44 dB while the average postoperative A-B gap was 14.44 dB, giving an average postoperative gain of 18 dB.

Majority of patients 33 (55%) had a gain in the range of 11-20 dB. Eighteen patients had a gain of more than 20 dB (30%) while 18 patients (15%) had 6-10 dB gain (Figure 4). This group comprised of 03 cases with graft rejection. Mean pre-operative hearing threshold was 45.69 dB with standard deviation of ± 8.95415 (Median 45). Mean post-operative hearing threshold was 27.69 with standard deviation of ± 4.98806 (Median 30). The average gain in hearing level was 18 dB with standard deviation of ± 7.15661 (Median 15.625). (Table 6).

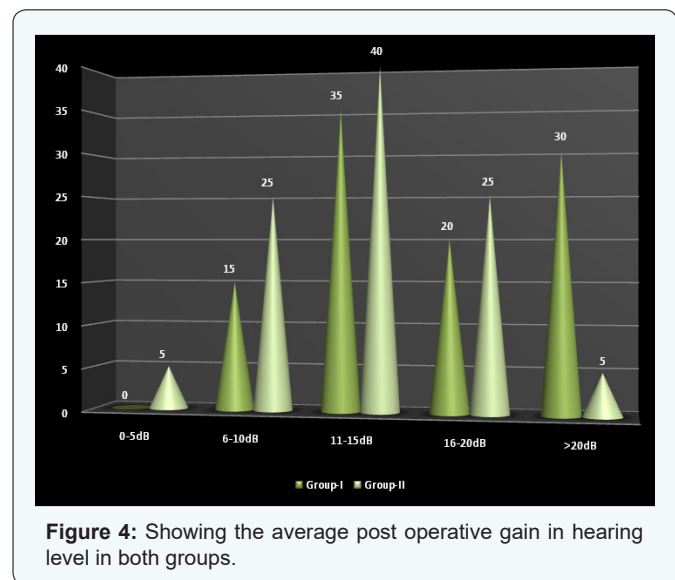


Figure 4: Showing the average post operative gain in hearing level in both groups.

The average preoperative A-B gap was 32.44 dB with standard deviation of ±8.1865(Median 30) while the average postoperative A-B gap was 14.44 dB with standard deviation of ± 3.8575(Median 14.37), giving an average postoperative gain

of 18 dB with standard deviation of ± 7.15661(Median 15.625) (Table 7).

Table 6: Average Postoperative Gain Group-I.

0-5 db	00
6-10 db	09(15%)
11-15 db	21(35%)
16-20 db	12(20%)
>20 db	18(30%)

Table 7: A-B Gap IN dB before and Sixth Month after Myringoplasty.

	Group 1 (n = 60)	Group 2 (n = 60)	P Value
Preoperative A-B gap	32.44 ± 8.18	26.94 ± 6.8	0.026
Postoperative A-B gap	14.44 ± 3.857	13.24 ± 6.02	0.45
A-B gap difference	-18 ± 7.156	-13.17 ± 5.708	0.042

Group II

The average preoperative hearing threshold was 37.95 db while the average postoperative hearing threshold was 24.25 dB, thereby average gain of 13.7 dB. The average preoperative A-B gap was 26.94 dB while the average postoperative gap of 13.24 dB, thereby average gain of 13.7 dB.

Majority of patients 39 (65%) had a gain in the range of 11-20 dB. Three patients (5%) had a gain of 0-5 dB while 15 patients (25%) had 6-10 dB gain (Figure 4). This group comprised of 06 cases with graft rejection. Mean pre-operative hearing threshold was 37.95 with standard deviation of ± 8.0727 (Median 36.25). Mean post-operative hearing threshold was 24.25 dB with standard deviation of ± 7.8786(Median 22.5). The average gain in hearing level was 13.7 dB with standard deviation of ± 5.70814(Median 13.125) (Table 8).

Table 8: Average Postoperative Gain Group-II.

0-5 db	03(5%)
6-10 db	15(25%)
11-15 db	24(40%)
16-20 db	15(25%)
>20 db	03(5%)

The average preoperative A-B gap was 26.94 dB with standard deviation of ± 6.8402(Median 25) while the average postoperative A-B gap was 13.24 dB with standard deviation of ± 6.0227(Median 11.75), giving an average postoperative gain of 13.7 dB with standard deviation of ± 5.70814(Median 13.125) (Table 8).

The statistical analyses of the data were done by applying Student T-test & mentions groups have equal variance:

- P value for preoperative hearing threshold and A-B

gap between both groups was 0.00667 and 0.026 respectively which was statistically significant.

- P value for postoperative hearing threshold and A-B gap between both groups was 0.10747 and 0.45 respectively which was statistically insignificant.
- P value was 0.04236 for gain in hearing threshold (A-B gap gain) between both groups which was statistically significant (Table 8).

Discussion

Myringoplasty is a procedure, in which the reconstructive procedure is limited to repair of tympanic membrane perforation. Implicit in the definition is that the ossicular chain is intact and mobile, and the middle ear is disease free [2]. Tympanic membrane repair has undergone significant refinements over the years. The anterior or subtotal tympanic membrane perforation is difficult to repair because of less vascularity; moreover the anterior bony overhang blocks visualization. The graft may fall in the middle ear, resulting in re-perforation and obliteration of the anterior part of middle ear cavity [3].

To manage these problems variety of surgical techniques, such as the use of William's microclip, sandwich graft tympanoplasty and loop overlay myringoplasty, over-underlay technique and mediolateral myringoplasty has been used [4-8].

The prognostic factors influencing the success rate of myringoplasty are technical, including the surgical approach, the dynamics operative field and the skills of the surgeons; for example, the worst results obtained in the transmeatal approach are consequent to the more difficult positioning of the graft through this narrower operative field. Graft failure is considerably higher in anterior perforation, large perforation & possibly influenced by difference in grafts placement. Schuknecht emphasized that the surgical technique is most important variable for the success of myringoplasty [9].

Proper positioning of the graft improves the graft uptake rate. Therefore, it is very important to position the graft in the proper position by allowing the surgeon to visualize operative field better for proper handling of the graft. The need to clearly identify the graft is heightened for residents or less experienced surgeon. Applebaum used fluorescence dye for determining the vascularisation of the tympanic membrane to study kinetic of blood stream using xenon light source [3].

Lee (2005) used gentian violet in grafting technique in which a part of handle of malleus is exteriorized by making it pass through a stained hole created in fascia graft in overlay myringoplasty. This allow the surgeon to better see the hole and better handle the graft, it is useful regardless of the experience of the surgeon without any adverse effect of genitan violet. Such improved identification of a hole can be very helpful for trainee residents or less experienced surgeons and reduce the time of a graft placement and it can substantially decrease the failure rate

of the grafting [10].

Talas et al. [11] advocated the use of methylene blue stained temporalis fascia and emphasized that the graft should be stained only on one side. The side receiving the pigment is brighter than unstained side. This allows the surgeon to differentiate one side from other side, making it easier to see if graft is twisted or folded. They reviewed the charts of 30 consecutive patients undergoing this technique and found the graft take up rate was 100% at the two-month follow-up. No patients had otherwise unexplained inner ear dysfunction attributed to the use of tissue stains. We also observed the same in the present study.

Vaiman et al. [12] compared the tympanoplasty results of methylene blue stained temporalis fascia graft with results of tympanoplasty using unstained temporalis fascia graft. Tympanoplasty with graft placement was performed by young surgeons on 30 patients (30 ears) with anterior perforations using intra operative staining of tympanoplasty grafts with methylene blue (Group 1). The same number of patients/ears was operated by the young surgeons without intra operative staining (Group 2). Results showed tympanic membrane healing (graft take) in 30 (100%) cases in Group 1 and in 26 (86.66%) cases in Group 2. The pure-tone audiogram testing revealed significant improvement of hearing in all successful cases ($p < 0.05$). No side effect immediate or postponed effects were detected. They concluded that intravital staining with methylene blue in tympanoplasty simplifies the operation and could assist in better visualization and proper placement of the graft. This technique could be most useful in a training process for resident surgeons. All surgeries were performed by young surgeons. They reported 100% graft take up in methylene blue stained temporalis fascia graft as compared to 86.66% graft take up in unstained temporalis fascia graft.

Wong stated that difficulty may be experienced in the placement of the graft during tympanoplasty, especially in anterior tympanic membrane perforation. The author observed that the use of methylene blue stained temporalis fascia graft provides contrast between the edges of the tympanic membrane perforation and the graft. This contrast allows the surgeon to better visualize the graft and thus ensures that the perforation is totally covered with the graft [13]. We also observed the same in the present study.

In this study we used methylene blue as topical dye staining temporalis fascia graft. Our study revealed that graft success rate was 95% in group-1 and 85% in group-2 with no statistically significance in the uptake rate. There was statistically significant difference ($p = 0.04$) between group 1 and group 2 regarding gain in A-B gap postoperatively. These results are comparable with previous study in view of graft uptake and hearing improvement [12].

Addition to staining purpose, methylene blue has been used as antioxidant and antibacterial agent Hydrofera blue

bacteriostatic dressing utilizes the agents: gentian violet and methylene blue to help manage wound bio-burden and protect against infection in variety of etiologies that may have contributed to the wound's slow progression toward healing including diabetes, obesity, venous insufficiency, sickle cell anemia, and acute respiratory distress syndrome, acute necrotizing wound infected with methicillin-resistant staphylococcus aureus (MRSA) and vancomycin-resistant enterococcus. To further protect wounds from harmful microorganisms, hydrofera blue absorbs bacteria-laden exudates away from the wound and does not inhibit the activity of enzymatic debriders, fibroblast growth factors, or platelet-derived growth factors [14]. However the field in patients undergoing myringoplasty is clean and almost sterile.

Over the years, methylene blue has also been used in human and veterinary medicine for a number of therapeutic and diagnostic procedures. Methylene blue has been used as vital stain in conjunctival, corneal staining and for guiding layered excision in Mohs' micrographic surgery [15]. Methylene blue also has been used for staging nodal metastasis in rectal and breast carcinoma also used in diagnosis of displaced central line and abnormal parathyroid gland [16-19]. It has been also used in diagnosis of uterovesical, vesicovesical fistula, parotid fistula, preauricular and brachial sinuses or fistulae [20].

The advantages of using methylene blue in myringoplasty include: better visualization of the graft, proper alignment & placement of the graft in relation to margins of perforation, allowing complete closure of the perforation. The stained side is brighter than unstained side & this allows the surgeon to rule out twisting/folding of the graft. The graft is positioned so that dyed surface faces laterally, it makes it easier to inspect the margins of perforation & the stained surface of graft allowing accurate placement of the graft, the because of better visualization of the graft. It is useful regardless of the experience of the surgeon. Such improved identification of the graft can be very helpful for trainee residents or less experienced surgeons and reduce the time of surgery. Also, methylene blue as an antioxidant and antimicrobial properties, prevents degradation and lysis of fascia graft, improves the overall success rate of graft uptake with no adverse effect [11-14].

Conclusion

Our study emphasizes the fact that overall satisfactory hearing outcome with adequate air-bone closure and improved graft uptake in methylene blue stained temporalis fascia in myringoplasty. Although our study results are comparable with previous study in view of graft uptake and hearing improvement but long duration follow-up (6 month) and large data as compare to previous study values the overall outcome. Although, various modalities has been used in myringoplasty for better graft visualization as, geniton violet, formalin, alcohol and florescent dye and methylene blue. Here we discuss the role of methylene blue as antioxidant and antimicrobial agent along with staining

property that may play additional role in surgical outcome. So, methylene blue as staining agent can be practiced in routine basis to improve myringoplasty outcome among trainee residents and less experience surgeons.

Acknowledgments

We gratefully thank the Department of Otolaryngology and Head and Neck Surgery, Pt. B.D Sharma, PGIMS Rohtak, as well as the patients who have voluntarily collaborated to this study.

All procedures performed in studies involving human participants were in accordance with the ethical standards of the institutional and/or national research committee and with the 1964 Helsinki declaration and its later amendments or comparable ethical standards.

References

1. Smyth GD (1976) Tympanic reconstruction. Fifteen year report on tympanoplasty. Part II. *J Laryngol* 90(8):713-741.
2. Bhat NA, De R (2000) Retrospective analysis of surgical outcome, symptoms changes and hearing improvement following myringoplasty. *J Otolaryngol* 29(4): 229-232.
3. Applebaum EL, Deutsch EC (1986) An endoscopic method of tympanic membrane fluorescein angiography. *Ann Otol Rhinol Laryngol* 99(5 Pt 1): 439-443.
4. Forrior JB (1989) Sandwich graft tympanoplasty: experience, results and complications. *Laryngoscope* 99(2): 213-217.
5. Weider DJ (1981) Use of William's microclips in various aspect of tympanoplastic surgery. *Laryngoscope* 91(12): 2106-2125.
6. Lee YP, Auo HJ, Kang JM (2010) Loop overaly tympanoplasty for anterior or subtotal perforations. *Auris Nasus Larynx* 37(2): 162-166.
7. Park SK, Jung TT (2005) Mediolateral graft tympanoplasty for anterior or subtotal tympanic membrane perforation. *Otolaryngol Head Neck Surg* 132(4): 532-536.
8. Kartush JM, Elias M, Michaelides EM, Becvarovski Z, LaRouere MJ (2002) Over-underlay myringoplasty. *Laryngoscope* 112: 802-807.
9. Schuknecht HF (1976) Myringoplasty. *Clin Otolaryngol Allied Sci* 1(1): 53-65.
10. Lee DH, Lee HY, Seo JH, Choi HG (2008) Intraoperative marking of overlay graft: A simple technique to pass a malleus through a hole. *Mediterr J Otol* 2008; 217-220.
11. Talas D, Nguen-Huynh A, Blevins NH (2008) Intraoperative staining of tympanoplasty graft; a technique to facilitate graft placement. *Otolaryngol Head Neck Surg* 138(5): 682-683.
12. Vaiman M, Sarfaty S, Gavriel H, Kraus M, Kaplan D, et al. (2010) Intravital staining with methylene blue in myringoplasty. *Eur Arch Otorhinolaryngol* 267(9): 1351-1354.
13. Wong RT (1983) Methylene blue stained temporalis fascia graft tympanoplasty. *Laryngoscope* 93(2): 241.
14. Steed DL, Attinger C, Colaizzi T, Crossland M, Franz M, et al. (2006) Guidelines for the treatment of diabetic ulcers. *Wound Repair Regen* 14(6): 680-692.
15. Yu DD, Yeatts P, Leshin B (1991) Methylene blue stain guiding layered excision in Mohs' micrographic surgery. *Ophthalmic Surg* 22(4): 233-

- 236.
16. Liu J, Huang P, Zheng Z, Chen T, Wei H (2014) Modified methylene blue injection improves lymph node harvest in rectal cancer. *ANZ J Surg.*
17. Simmons RM, Smith SM, Osborne MP (2001) Methylene blue dye as an alternative to isosulfan blue dye for sentinel lymph node localization. *Breast J* 7(3):181-183.
18. Namachivayam P, Tibballs J (2006) Methylene blue for diagnosis of displaced atrial lines. *Anaesth Intensive Care* 34(2): 280-281.
19. Dudley NE (1971) Methylene blue for rapid identification of parathyroids. *BMJ* 3(5776): 680-681.
20. Dickson JM, Riding KH, Ludemann JP (2009) Utility and safety of methylene blue demarcation of preauricular sinuses and brachial sinuses and fistulae in children. *J Otolaryngol Head Neck Surg* 38(2): 302-310.