

The Role of Radio Surgery in Brain Metastases Treatment – Attaining Local Control

*Or Cohen-Inbar^{1,2,3,4}

¹Department of Neurological Surgery, Rambam Health Care Center, Haifa Israel

²Molecular Immunology Laboratory, Technion Israel Institute of Technology, Israel

³Faculty of Medicine, Technion Israel Institute of Technology, Israel

⁴Department of Neurological Surgery and Gamma-Knife Radiosurgical Center, University of Virginia Health Care Center, USA

Submission: April 14, 2016; Published: April 21, 2016

*Corresponding author: : Or Cohen-Inbar, M.D., PhD, Department of Neurological Surgery, University of Virginia, Charlottesville, Virginia 22908, United States of America, Tel: 434-924-8129; Fax: 434-243-6726 Email: oc2f@virginia.edu

Introduction

Brain metastases are a common cause of morbidity and mortality. Surgical resection (SR), Radiosurgery (SRS) and Whole brain radiotherapy (WBRT) are the main treatment modalities aimed at attaining local control. SR allows for tissue diagnosis and for a swifter symptomatic relief, yet surgical morbidity in these frail patients, continues to taint its advantages.

Abbreviations

SR: Surgical Resection; SRS: Radiosurgery; WBRT: Whole Brain Radiotherapy; NSCLC: Non-Small-Cell Lung Carcinoma; CT: Computed Tomography

SRS and SR

SRS is an attractive treatment option for patients harboring a limited intracranial metastatic burden due to its single session, high dose, highly conformal nature. SRS has minimal side effects or time delay to starting systemic therapy as well. With regards to local control, reports from the last decade have shown good and comparable rates of SRS and SR, with lower morbidity in SRS and a swifter relief in SRS.

WBRT

A large body of evidence suggests WBRT should be used as an adjunct tool. As primary treatment, WBRT is inferior to SRS or SR in attaining local control. WBRT is reserved for lesions unsuitable for SRS or SR due to size, number or location constraints. Still, omitting WBRT as an adjunct tool after SR or SRS has led to worse local and distant intracranial control, with no influence on functional or overall survival.

The Nurse's Role

As an integral part of the radiosurgical team, the nurse's role is characterized by greater autonomy with emphasis on the

patient's quality of live, as well as guidance for the patient and family.

Summary

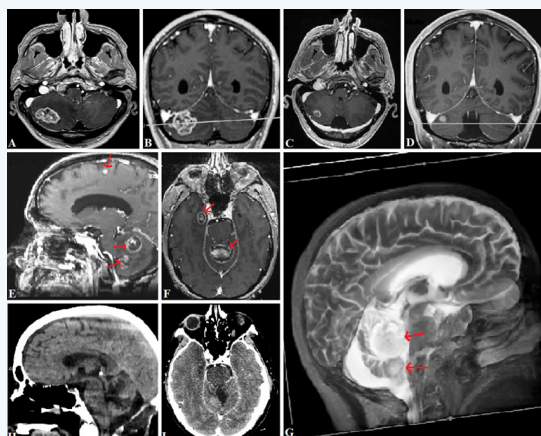


Figure 1: The multi-disciplinary treatment of brain metastases in an attempt to achieve local tumor control, sample patient.

Treatment should be multidisciplinary. SRS is comparable to SR, in attaining local control (Figure 1). This is a 52 years old man with a Non-Small-Cell Lung Carcinoma (NSCLC). A+B, 02.2013 T1WI MRI axial and coronal sections respectively, showing a solitary right cerebellar metastatic lesion. The patient was treated with upfront stereotactic radiosurgery (SRS). C+D, 05.2013, T1WI MRI axial and coronal sections respectively, showing a marked decrease in the size of the metastatic lesions, portraying local tumor control. E+F+G, 04.2014, T1WI MRI sagittal and axial sections respectively, as well as a T2WI 3-dimensional reconstruction showing distant disease progression (elsewhere in the brain, see arrows). A large cerebellar vermis lesions is shown, compressing the fourth ventricular with subsequent development of obstructive hydrocephalus. The patient

underwent a microsurgical open resection of this lesion and SRS for the distant spread. H+I, Computed Tomography (CT) without and with contrast agent sagittal and axial sections respectively (MRI was not performed due to the presence of a new ventriculo-peritoneal shunt), showing adequate local control of all lesions (both resected and irradiated).

Conflict of Interest Disclosure

The authors have no personal or institutional financial interest in drugs or materials in relation to this paper.