

Infertility- Celiac Disease Not To Be Missed

Parveen Malhotra*, Naveen Malhotra, Vani Malhotra, Ajay Chugh, Abhishek Chaturvedi, Parul Chandrika, Pansi and Sonia Chhabra

Department of Medical Gastroenterology, Anaesthesiology, Obstetrics & Gynecology and Pathology, PGIMS, India

Submission: December 16, 2015; **Published:** January 19, 2016

***Corresponding author:** Parveen Malhotra, Department of Medical Gastroenterology, Pt.B.D.S. Post Graduate Institute of Medical Sciences, 128/19, Civil Hospital Road, Rohtak – 124001, Haryana, India, Tel: 09671000017; Email: drparveenmalhotra@yahoo.com

Abstract

Background: Celiac disease (CD) is a common chronic immune-mediated, inflammatory disorder of the small intestine induced by a permanent intolerance to dietary wheat, barley, and rye.

Case: A married 25 year old female presented to infertility clinic with 5 year duration of infertility who could not conceive even after 3 cycles of ovulation induction. On detailed evaluation, she was found to have stage III celiac disease (modified marsh classification). Patient was put on Gluten Free Diet (GFD).

Result: After about 3 months, diarrhoea was eradicated and patient had spontaneous conception.

Conclusion: As reproductive alterations are reversible, a timely diagnosis and the introduction of a gluten-free diet are of paramount importance.

Keywords: Celiac disease; Infertility; Gluten free diet

Abbreviations: CD: Celiac Disease; GFD: Gluten Free Diet; TG2: Transglutaminase 2

Introduction

Celiac disease (CD) is a common chronic immune-mediated, inflammatory disorder of the small intestine induced by a permanent intolerance to dietary wheat, barley, and rye [1]. Celiac disease (CD) is a permanent intolerance to gluten, for which the only treatment currently available is a lifelong adherence to a Gluten-Free Diet (GFD). Once patients are diagnosed with celiac disease and begin the gluten-free diet, 70% report symptom relief within two weeks [2]. We are reporting a case report of a 25 year old female of unexplained infertility who was diagnosed with celiac disease on detailed evaluation.

Case Report

A married 25 year old female presented to infertility clinic with 5 year duration of infertility. There was no history of contraception. She had attained menarche at age of 14 years and her menstrual cycles were normal. Physical examination revealed only mild pallor with normal secondary sexual characters. There were no signs of hirsutism and acne. Lab

findings revealed normal semen analysis, hemoglobin-9gm% and normal hormonal assay. Endometrial biopsy was negative for tuberculosis and revealed secretory phase. Hysterosalpinogram was normal. She could not conceive even after 3 cycles of ovulation induction. On detailed evaluation, she gave history of intermittent and non-bloody diarrhea for past few years. Patient was referred to a gastroenterologist. In view of chronic diarrhea and long duration of infertility, serological tests (IgATtg) for celiac sprue was suggested which was found to be positive. Upper gastrointestinal endoscopy with biopsy of 2nd part of duodenum was done which revealed stage III celiac disease (modified marsh classification) (Figure 1). Patient was put on Gluten Free Diet (GFD).

Result

After about 3 months, diarrhoea was eradicated and patient had spontaneous conception. She had spontaneous onset of labour pains and delivered a healthy baby weighing 3 kg. She is at present totally asymptomatic on gluten free diet.

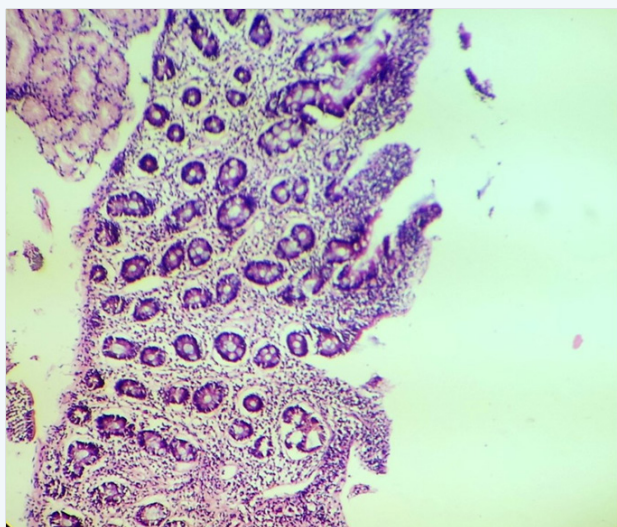


Figure 1: Duodenal biopsy showing stage III Marsh classification.

Discussion

Celiac disease is a unique autoimmune disorder in that the environmental precipitant is known. Until 2004, medical schools taught that celiac disease was a rare disease of childhood. However, current estimates state that nearly three million Americans suffer from celiac disease, but 95% of them remain undiagnosed, making celiac disease the most common, and one of the most under diagnosed, hereditary autoimmune disease.

When celiac disease patients consume gluten, the inflammatory cascade is initiated within hours resulting in a compromise of barrier integrity, followed by tissue degradation and eventual inhibition of nutrient absorption. Celiac disease (CD) has a multifactorial pathogenesis [3]. Common symptoms may include bulky stool, constipation, anemia, delayed growth, failure to thrive and infertility [4]. Celiac disease used to be perceived as presenting with gastrointestinal symptoms suggestive of malabsorption, such as edema secondary to hypoalbuminemia, hypocalcaemia, vitamin deficiency states and osteomalacia [5]. This manner of presentation is now described as the “classic” or “typical” form. Patients with celiac disease may have the “silent” or “atypical” form with no gastrointestinal symptoms and the condition may present outside the intestines and can affect any organ system [6]. The reproductive alterations most frequently found in women affected by CD include: infertility, spontaneous abortions, amenorrhea and shorter fertility period (delayed puberty, early menopause). Moreover, delay in the intrauterine foetal growth is not excluded. In a case-control study on women with infertility for unexplained reasons [7], 4.1% (4 out of 98 patients) of the cases were affected by CD in comparison to 0 out of 150 controls. Thus, it seems possible that, in some patients, unexplained infertility can be the consequence of a clinically silent disease, it being its first and, sometimes, only symptom.

The diagnosis of early developing celiac disease should be based on a combination of clinical features, histology, serology, and genetics. The majority of celiac patients visit five or more doctors prior to diagnosis, with a median time for diagnosis of five-to-11 years after initial presentation. Historically, diagnosis was suggested by positive serology and confirmed with endoscopy. Serum immunoglobulin IgA-class endomysial (EmA) and transglutaminase 2 (TG2) antibodies are powerful tools in diagnosing celiac disease with overt villous atrophy [8]. The diagnosis of celiac disease requires the presence of small intestinal mucosal villous atrophy and crypt hyperplasia.

Malnutrition and its derived symptoms most commonly present in undiagnosed females with celiac disease. This symptom can directly compromise the potential and ability to conceive due to a negative energy balance and the decreased ability to maintain fat storage in afflicted females. Those with undiagnosed celiac disease and who do not follow a gluten-free diet may intensify unfavorable conditions for conception within the body and, more specifically, within the reproductive system. Men also suffer from infertility stemming from undiagnosed celiac disease [9]. Affected males show a picture of tissue resistance to androgens. The increases of follicle-stimulating hormone and prolactin may indicate an imbalance at hypothalamus-pituitary level [10]. Hypogonadism is a known factor in male infertility and has been found in 7% of celiac males in one survey.

Conclusion

In the past years, reports on the existence of a possible association between celiac disease and reproductive tract disorders have increased. As reproductive alterations are reversible, a timely diagnosis and the introduction of a gluten-free diet are of paramount importance. Thus, the use of early CD indicators, such as vitamin and/or iron deficiencies, andrologic or endocrinologic dysfunctions, should allow a prompt adoption of prevention and treatment strategies.

References

1. Murray J (1999) The widening spectrum of Celiac Disease. *Am J Clin Nutr* 69(3): 354-365.
2. Taranta A, Fortunati D, Longo M, Rucci N, Iacomino E, et al. (2004) Imbalance of osteoclastogenesis-regulating factors in patients with celiac disease. *J Bone Miner Res* 19(7): 1112-1121.
3. Alaedini A, Green PH (2005) Narrative review: celiac disease: understanding a complex autoimmune disorder. *Ann Intern Med* 142(4): 289-298.
4. Stazi A, Montovani A (2000) A risk factor for female fertility and pregnancy: celiac disease. *Gynecol Endocrinol* 14(6): 454-463.
5. Green PH, Alaedini A, Sander HW, Brannagan TH, Latov N, et al. (2005) Mechanisms underlying Celiac Disease and its Neurologic Manifestations. *Cell Mol Life Sci* 62(7-8): 791-799.
6. Fasano A (2003) Celiac Disease - How to Handle a Clinical Chameleon. *NEJM* 348(25): 2568-2570.
7. Collin P, Vilska S, Heinonen PK, Hallstrom O, Pikkarinen P (1996)

- Infertility and celiac disease. *Gut* 39(3): 382-384.
8. Salmi TT, Collin P, Järvinen O, Haimila K, Partanen J, et al. (2006) Immunoglobulin A autoantibodies against transglutaminase 2 in the small intestinal mucosa predict forthcoming celiac disease. *Aliment Pharmacol Ther* 24(3): 541-552.
 9. Farthing M, Rees L, Edwards C, Dawson A (1983) Male gonadal function in celiac disease: 2. Sex hormones. *Gut* 24(2): 127-135.
 10. Stazi A, Trinti A (2005) Reproductive aspects of celiac disease. *Ann Ital Med Int* 20(3): 143-157.