Advances in Dentistry & Oral Health
ISSN: 2472-6389

Juniper Publishers
key to the Researchers

Research Article
Volume 14 Issue 2 - May 2021
DOI: 10.19080/ADOH.2021.14.555884

Adv Dent & Oral Health

Restorative Outlook on Mixed Application Techniques Involving Silver Diamine Fluoride

Kiana Rostamiani[1], Nechama Citrin[1,4], Colette Stewart[1,3], William Callahan[1,4] and Ammaar H Abidi[1,2,4]*

[1]*College of Dentistry, The University of Tennessee Health Science Center, Tennessee*

[2]*Department of Bioscience Research, The University of Tennessee Health Science Center, Tennessee*

[3]*Department of Dental Hygiene, The University of Tennessee Health Science Center, Tennessee*

[4]*Department of General Dentistry, The University of Tennessee Health Science Center, Tennessee*

Submission: May 10, 2021; **Published:** May 21, 2021

***Corresponding author:** Ammaar H Abidi, College of Dentistry, Department of Bioscience Research, Department of General Dentistry, The University of Tennessee Health Science Center, Tennessee

Abstract

Background: This study aimed to evaluate the effects on the aesthetics of restorations in both carious and non-carious teeth after the application of silver diamine fluoride (SDF) and the effects of silver diamine fluoride (SDF) on microleakage associated with two restorative materials composite resin and glass ionomer.

Methodology: Twenty-five Class I preparations on extracted molars were randomly divided into experimental groups (n=5 per 5 groups). Restorative materials used included TPH ST composite and Chemfil Rock GI (glass ionomer). TPH served as the control. SDF was applied to the floor of the tooth preparations for 1 minute and then air-dried. Treatment groups included Non-carious (NC): SDF+TPH and SDF+GI+TPH; and Carious (C): SDF+TPH and SDF+GI+TPH, respectively. Teeth were thermocycled 5000x at 5° and 55°C. Specimens were covered with two layers of nail varnish except for 1 mm around the interface, mounted in resin, and submerged in basic fuchsin dye for 24 hours. Specimens were sectioned mesiodistally, examined under a light microscope at 50x, and scored for microleakage according to the following criteria: 0) no leakage visible;1) penetration short of dentinoenamel junction; 2) penetration short of the axial wall; 3) penetration to and along the axial wall. The aesthetic evaluation was performed by male and female clinical examiners under standard daylight conditions with repeatable positioning of the head for all six observers. Evaluations for color, translucency, surface roughness, and appearance were scored. Results were analyzed using two-way ANOVA, and the Kruskal-Wallis test.

Results: Aesthetically, TPH scored significantly higher than all others ($P<0.001$). Subtle but no significant changes were visible in the aesthetic scoring between males and females. In the microleakage study, TPH exhibited the least microleakage, while SDF+TPH-NC ($p<0.05$) showed significantly more microleakage.

Conclusion: Aesthetically, TPH was superior and all SDF treated teeth led to discoloration/darkening. No restorative material was able to successfully mask the discoloration caused by SDF. Furthermore, microleakage results suggest SDF+GI+TPH-C was comparable to TPH in preventing microleakage and provided the best marginal seal in SDF-treated teeth.

Keywords: Non-carious; Fluoride varnish; Composite resin and Glass ionomer

Abbreviations: SDF: Silver Diamine Fluoride; NC: Non-Carious; C: Carious; FV: Fluoride Varnish; GI: Glass-Ionomer Resin; NHNE: National Health and Nutrition Examination Survey; KI: Potassium Iodide; GIC: Glass Ionomer Cement

Introduction

Dental caries is a complex multifactorial global problem seen in children and adults [1]. The current prevalence of cavitated carious lesions into dentin remains very high, even after improvement in dental hygiene awareness [2]. In deeply decayed dental lesions encroaching on the pulp, many have suggested the use of a medicament after removal of dental caries to sterilize the dental cavity. Several preventative approaches have been applied to reduce the burden of dental caries including placing medicaments or chemical barriers like fluoride varnish (FV) and silver diamine fluoride (SDF) to halt the progression of caries [3,4]. Ideally, to ensure sterilization of the preparation after complete removal of decay, the preparation would be hermetically sealed with resin material. The medicine would serve to disinfect the preparation and the restorative material would deprive the

infecting bacteria of acquiring nutrients. This concept could be an optimal solution to save teeth that are identified at an early phase of carious activity, and if left untreated, would routinely lead to endodontic procedures.

Interestingly, studies have demonstrated some success in the management of vital cavitated and asymptomatic teeth, which benefited from incomplete or partial removal of caries if the perimeter of preparation is absent of caries and an appropriate restorative material was used [5,6]. Therefore, in this study, we examined the use of silver diamine fluoride (SDF) as a chemical barrier/medicament on extracted teeth to improve our current knowledge of techniques and clinical approaches in this area. SDF has 38% w/v (weight/volume) silver that provides antimicrobial activity [7] with substantivity, while the fluoride helps with remineralization; diamine makes a metal complex with silver to stabilize concentrations of the fluoride and silver in solution [8]. Currently, a restoration technique termed SMART (Silver Modified Atraumatic Restorative Treatment) [9] uses SDF to arrest caries and is restored with conventional glass-ionomer resin (GI). The use of GI is usually avoided by dental practitioners in the occlusal regions or Class I type preparations because of lack of durability and potential failure of restoration due to the low mechanical strength of GI when compared to conventional composites [10]. Furthermore, the use of SDF has clinical concerns such as discoloration, which may compromise aesthetics [4].

Additionally, dentists are hesitant to place SDF under restorations due to clinical uncertainty of SDF interfering with bonding mechanisms and potentially leading to restoration failure. However, it has been reported that in non-carious teeth, contemporary composite bonding with SDF did not affect dentin bonding in either full-etch or self-etch systems [11]. Another study indicated an increase in bond strength after the application of SDF to dentin before cement placement [12]. Meanwhile, evidence of reduced bond strength of certain luting agents with SDF application has also been reported [13]. In a study published by Knight G.M, et al, leaving behind an SDF precipitate with potassium iodide on the dentin surface significantly reduced the bonding strength of auto-cured GI's [14].

Therefore, current data pertaining to the use of SDF along with composite resin is limited and requires more research to improve on current methods of application. In theory, the application of SDF on deep carious lesions is reliable, but the limited knowledge of microleakage and bondability requires further investigation. The present study focuses on microleakage, aesthetics, and restorative material of choice in vitro. The significant findings within the study may aid in the development of new clinical protocols that could be used to assist providers in establishing better protocols for patient care that may arrest dental caries and preserve more tooth structure. In this study, we aimed to improve clinical outcomes by clarifying the inconsistencies associated with the clinical application of SDF. Additionally, the study provides valuable information to dental practitioners to help improve current SDF protocols and to allow for the incorporation of SDF's desensitization and disinfection properties into clinical practice.

Materials and Methods

Samples and preparation

105 extracted molars (60-75 non-carious and 30 carious) were collected in accordance with guidelines for human subjects at the University of Tennessee Health Science Center (IRB 19-06513-XM). For a few weeks, the teeth were disinfected and stored in a 1:10 water/sodium hypochlorite solution and then were transferred into distilled water for storage until use. The teeth were cleaned and scaled to remove debris and polished with a prophy cup and pumice before class I cavity preparation. Using a high-speed electric handpiece with air-water coolant, Class I occlusal cavity preparations was prepared on the extracted teeth in accordance with the following dimensions: 2mm wide, 2.5-3.0mm deep, and 3-4mm in length. ISO size (No.330), (No.245) inverted fissured and straight fissured (No.056) carbide burs were used. The preparation for the carious teeth was based upon the depth of caries and/or 4mm (at least 1mm away from the pulp). If decay remained after 4mm, the tooth was maintained as part of the study even though decay remained. Following five cavity preparations, the bur was replaced. To maintain uniformity, the dimension of the cavity preparations was measured using a periodontal probe. The cavity preparations were performed by three separate operators. The restorative filling material was placed by only one operator to ensure consistency in the procedure.

Restorative material and procedures

Table 1: All five groups of samples were stored in distilled water immediately after completion. Group-I NC- Composite resin control (Non-carious teeth, Etch, Prime, TPH ST HV shade A2 composite), Group-II NC- SDF Composite (Non-carious teeth, SDF for 1 min, Etch, Prime, TPH ST HV shade A2 composite). Group-III NC- SDF GI + Composite (Non-carious teeth, SDF for 1 min, GI, Etch, Prime, TPH ST HV shade A2 composite). Group-IV C- SDF Composite (Carious teeth, SDF for 1 min, Etch, Prime, TPH ST HV shade A2 composite) Group-V C- SDF GI + Composite (Carious teeth, SDF for 1 min, GI, Etch, Prime, TPH ST HV shade A2 composite).

Groups	Carious (C)	Non-Carious (NC)
I	-	TPH only
II	-	SDF + TPH
III	-	SDF + GI + TPH
IV	SDF + TPH	-
V	SDF + GI + TPH	-

The extracted molar teeth were randomly divided into a total of five experimental groups with at least five teeth in each group. The SDF application (Advantage Arrest™, Elevate Oral Care, L.L.C.) was administered at the dentin surface only to mimic SDF placement in clinical settings at the affected or infected site encroaching the pulp. The restorative materials included etchant gel, prime, and bond dental adhesive, TPH composite resin, and glass ionomer cement by Dentsply Sirona (Charlotte, NC). The following chart (Table 1) represents the assignment of groups and the treatment regimen.

How to cite this article: Kiana R, Nechama C, Colette S, William C, Ammaar H A. Restorative Outlook on Mixed Application Techniques Involving Silver Diamine Fluoride. Adv Dent & Oral Health. 2021; 14(2): 555884. DOI: 10.19080/ADOH.2021.14.555884

Microleakage testing

In the microleakage testing, the restored teeth were subjected to 5000 thermal cycles. A thermal cycle consists of 30 seconds at 5.3°C and 30 seconds at 54°C. The non-restored tooth surface was covered with two layers of fast setting nail varnish within 1mm of the bonded restored interface. Following thermocycling, the teeth were retrieved and placed in a solution of basic fuchsin dye for 24 hours. The specimens were left undisturbed and allowed to dry for a minimum of one day. After drying, each tooth was sectioned mesiodistally through the center of the restoration. Microleakage was scored at the occlusal margins of the restorations under a stereomicroscope at 50X magnification. The extent of microleakage was scored according to the following criteria.

0 = no leakage visible 

1 = penetration short of dentino-enamel junction 

2 = penetration short of axial wall 

3 = penetration to and along the axial wall 

Clinical Aesthetic Evaluation of Restorations

The restorations were examined by six different clinicians who were unaware of the materials used to restore the Class I preparations. The criteria used to evaluate the teeth for clinical acceptance were based on color, marginal discoloration, surface texture, and marginal integrity. These were evaluated using the following grading criteria: A-Acceptable, U- Unacceptable, based on evaluation of color match, translucency, opacity, and surface roughness [15]. Next, the samples were ranked by different clinicians on an appearance system scale of 5 to 1 (where "5" is best and "1" is worst). To be able to have a uniform method for repeatable positioning of the head and face for clinical evaluation, the sample tooth was placed on a test plate on an inclined ramp that was centrally positioned in a light booth. To prevent the direct view of the tooth on the plate by the evaluator, a partition was placed. A mirror was positioned in the light booth so that the observer's line of sight intersected the mirror at an angle that allowed a normal (90 degree) view of the test plate and tooth sample. This created a straight view from the outside the light booth with no shadowing of the test plate and allowed the observer's head to be in a calibrated position. Administering the CRCD Test: A photograph of a similar color difference discriminating testing apparatus (Courtesy of Dr. James Ragain) is presented in Figure 1 below. The light booth was illuminated with a daylight spectral power illuminant.

Figure 1: Image of the CRCD Test.

Statistical analysis

The comparative aesthetic rating of restorations after thermocycling will be analyzed by two-way ANOVA and the Kruskal-Wallis test. The P-value will be set at ≤ 0.05 to demonstrate statistical clinical significance.

Results

Evaluation of microleakage in carious and non-carious teeth

Class I occlusal cavity preparations were performed on extracted teeth with the following dimensions (2.0mm W, 3.0-4.0mm in L, and 2.5-3.0mm deep). The preparations were performed by three operators and restorative materials were placed by a single operator to ensure consistency in the procedure. The TPH composite alone served as control; SDF+ TPH (NC); SDF+ GI+ TPH (NC); SDF+ TPH (C); SDF+ GI+ TPH (C). Restoration procedure consisted of etchant, prime, composite resin, and glass ionomer on carious and non-carious teeth, with and without the application of SDF. The microleakage-tested samples were viewed under a light microscope with 50X magnification, and the data were analyzed via a one-way ANOVA-Kruskal-Wallis test (Table 2); (Figure 2a & Figure 2b). Microleakage scores were analyzed on a numerical scale based on the depth of dye penetration, with 0: no

How to cite this article: Kiana R, Nechama C, Colette S, William C, Ammaar H A. Restorative Outlook on Mixed Application Techniques Involving Silver Diamine Fluoride. Adv Dent & Oral Health. 2021; 14(2): 555884. DOI: 10.19080/ADOH.2021.14.555884

leakage; 1: penetration short of the DEJ; 2: penetration short of the axial wall; 3: penetration to and along the axial wall. The results depict that TPH (control) demonstrated the lowest microleakage.

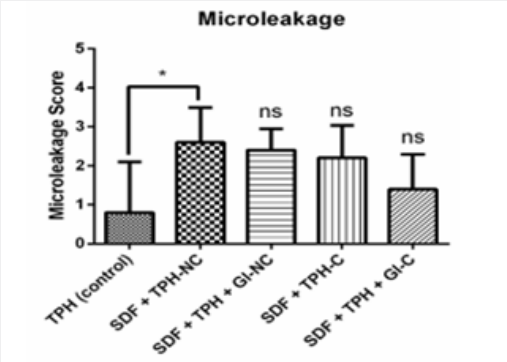

Figure 2a: The statistical analysis revealed the application of SDF with TPH on non-carious teeth presents with a statistically significant microleakage score (P-value<0.05) compared to control, while other groups did not show any significant difference from the control group TPH.



Figure 2b: The results depict that TPH (control) demonstrated the lowest microleakage.

Table 2: The microleakage tested samples were viewed under light microscope with 50X magnification, SDF+TPH in non-carious teeth exhibited significant microleakage, while TPH (control) and other treatments did not show significant microleakage. Below is an image depicting microleakage. Data was analyzed via one-way ANOVA-Krushal-Wallis test.

Specimen Material	Mean ± Std. Deviation (SD)	Significance from Control
TPH (control)	0.8 ± 1.30	N/A
SDF+TPH-NC	2.6 ± 0.89	P < 0.05
SDF+GI+TPH-NC	2.4± 0.55	NS
SDF+TPH-C	2.2 ± 0.84	NS
SDF+GI+TPH-C	1.4 ± 0.89	NS

Evaluation of restorations by gender for aesthetics

The aesthetic evaluation was performed by 3 male and 3 female clinicians. Each clinician viewed every individual specimen under the same daylight condition with a set viewing distance as noted earlier. Scoring was granted from 1 (worse) to 5 (best) in terms of color, translucency or opacity, and surface roughness. Results were analyzed using a two-way ANOVA test. As the following graphs illustrate (Figure 3), TPH (control) scores significantly higher in aesthetics than all other treatment categories. There are subtle differences in aesthetic scoring between male and female clinicians with the SDF+TPH+ GI (C), which scored higher in aesthetics among the female observers (Figure 4).

How to cite this article: Kiana R, Nechama C, Colette S, William C, Ammaar H A. Restorative Outlook on Mixed Application Techniques Involving Silver Diamine Fluoride. Adv Dent & Oral Health. 2021; 14(2): 555884. DOI: 10.19080/ADOH.2021.14.555884

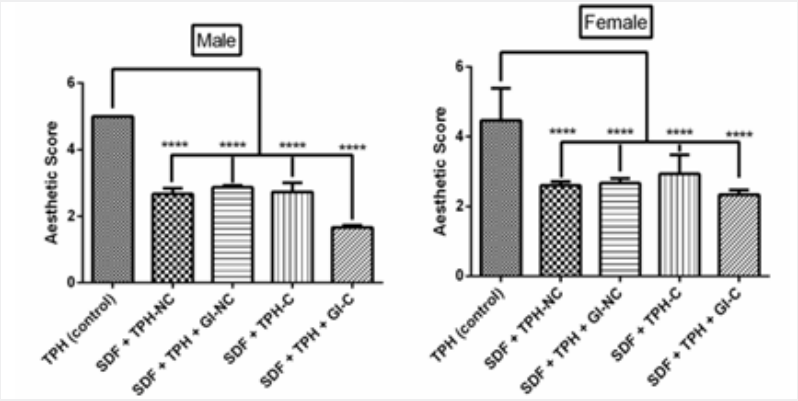

Figure 3: Aesthetic evaluation by male and female clinicians, showing TPH (control) scores significantly higher (P-value <0.001) in aesthetics than other categories.

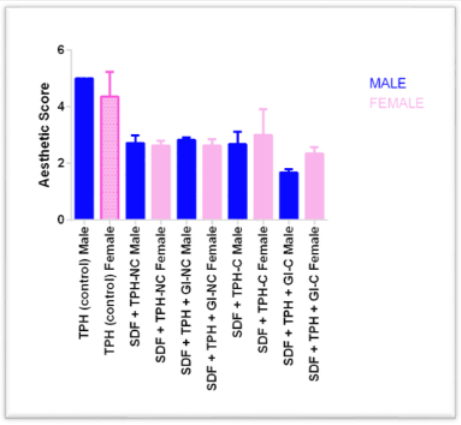

Figure 4: The bar graph illustrating male and female clinicians' aesthetics scores, reflecting that TPH (control) scores consistently higher in aesthetics. Noting subtle differences between the male and female clinicians, with the SDF+TPH+GI (C) samples scoring higher in aesthetics than other samples among the female observers.

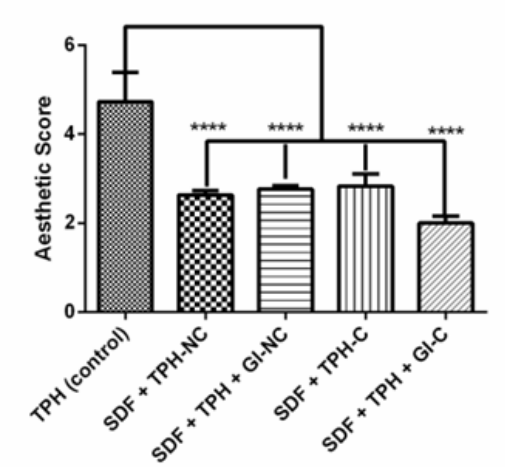

Figure 5: The graph shows each category with respect to the aesthetic scores given by all clinicians. Again, TPH (control) scores significantly higher (P<0.0001) than the rest of the samples, which were treated with SDF in combination with other restorative materials.

How to cite this article: Kiana R, Nechama C, Colette S, William C, Ammaar H A. Restorative Outlook on Mixed Application Techniques Involving Silver Diamine Fluoride. Adv Dent & Oral Health. 2021; 14(2): 555884. DOI: 10.19080/ADOH.2021.14.555884

Evaluation of restoration adequate/inadequate restorations and aesthetics

The aesthetic evaluation was performed by 6 clinicians including both male and female clinicians under standard daylight with repeated positioning of the head for all six evaluators. Results were analyzed using a two-way ANOVA test and graphed. TPH (control) scores significantly higher in aesthetics (P-value<0.001) than other groups, eluding to the fact that the application of SDF causes an unfavorable aesthetic change (Figure 5).

Discussion

Silver Diamine Fluoride (SDF) (Advantage Arrest™, Elevate Oral Care, L.L.C.) is composed of 38% w/v silver (Ag), which performs an antimicrobial role, fluoride helps with re-mineralization and diamine stabilizes the silver and fluoride complex. In 2015, SDF was approved by the U.S. Food and Drug Administration for treating dentinal hypersensitivity in adults. SDF has been used in some situations to arrest carious lesions and as of 2016, a new CDT code was developed D1354-interim caries arresting medicament application: Conservative treatment of an active, non-symptomatic carious lesion by topical application of caries arresting or inhibiting medicament and without mechanical removal of sound tooth structure. The off-label use of SDF for anti-cariogenic activity includes the placement of a thin layer of SDF at the base of the preparation as a liner, followed by restorative material of choice. The chemical barrier (SDF) aids in decontamination before a restorative material. This application along with a sound restorative approach has been proven to prolong the tooth life [16]. However, the use of SDF by clinicians has been limited due to aesthetic concerns such as staining or discoloration that is often observed after placement.

The study aimed to evaluate the aesthetics of silver diamine fluoride (SDF) application and the ability of SDF to manage the microleakage of restorative material. Evaluation of microleakage was done in carious and non-carious teeth after being restored with SDF with/without glass ionomer and composite. The aesthetic comparison was completed among all the restorations by an aesthetic index system evaluating color match, translucency or opacity, and surface roughness. This was followed by six clinicians ranking the restorations based upon appearance system 5 (best) to 1 (worst). Additionally, we evaluated the comparison between male and female clinicians to note if there are any significant differences in the aesthetics scores among the sexes. Clinicians examined and evaluated restorations randomly in a controlled environment to assess aesthetically adequate or inadequate restorations and to rank the restorations based upon appearance criteria. Based upon our results, the SDF treatment led to discoloration of teeth and was noticed by all clinicians. The discoloration of teeth after SDF treatment has been a major aesthetic concern and many clinicians apply opaque dental cement [17] to mask and help in shade matching of teeth.

There have also been investigations into other applications of SDF and the effects of potassium iodide (KI) treatment on secondary caries prevention in glass ionomer cement (GIC) restorations. However, the anticarcinogenic or inhibitory effects of SDF + KI treatment were not as effective as SDF treatment alone in the prevention of the development of secondary caries in GIC restorations. However, KI does help reduce discoloration after SDF application, and the staining is less intense compared to SDF treatment alone [18]. Another study examining the issue of SDF aesthetics found that the discoloration caused by SDF was considered acceptable by patients and only noted by clinicians [19]. In our assessment of SDF on aesthetics based on marginal discoloration, texture, and the overall aesthetics of the restorations with the use of composite resin (A2 vita shade) and glass ionomer, it was evident that TPH (control) provided the most aesthetically adequate restoration, and that the application of SDF consistently resulted in a less favorable aesthetic outcome. The findings comparing male and female clinicians were also of importance, to emphasize uniformity in the study. Although there were slight differences between male and female clinicians, these findings were not statistically significant.

Furthermore, SDF application in geriatric and pediatric dentistry is becoming more common to treat dental caries. The National Health and Nutrition Examination Survey (NHNE) data reported that 1 in every 7 children in the U.S. between ages 2 to 8 years exhibit untreated dental caries (decay) [20]. Although fluoride varnish application has shown to be an effective preventive method, it cannot arrest larger carious lesions. Meanwhile, SDF has been shown to not only provide a minimally invasive approach to the restoration of carious lesions, but SDF also exhibits at least twice the strength of 5% commercial fluoride [21]. Root caries in the geriatric population are an increasingly common occurrence and concern. In a study of community-dwelling elderly individuals, the annual application of SDF combined with annual oral hygiene instructions and a biannual oral health education program was more effective in preventing new root caries and arresting current root caries than annual oral hygiene instructions and a combination of annual oral hygiene instructions and annual SDF application [22].

Microleakage management is one of the key factors in producing a long-lasting restoration and is an important component of composite resin placement [22]. Extensive research has been performed assessing various dental materials and different approaches to reduce microleakage. Hernandez et al. [23] examined microleakage and adhesion with resin pit and fissure sealants with and without the application of SDF [23]. Although no statistical significance was found, the study indicated that there was a lower rate of microleakage in the SDF-treated teeth, which led to increased adhesion of the sealant material. The application of SDF in deep pits and fissures, therefore, may be protective to the tooth, while discoloration could be masked by resin sealants

How to cite this article: Kiana R, Nechama C, Colette S, William C, Ammaar H A. Restorative Outlook on Mixed Application Techniques Involving Silver Diamine Fluoride. Adv Dent & Oral Health. 2021; 14(2): 555884. DOI: 10.19080/ADOH.2021.14.555884

on the tooth surface [23]. More recently, FiteBac® produced a quaternary ammonium silane as a cavity cleanser to reduce the bacterial impregnation into dentin and anti-proteolytic activity to reduce the degradation of hybrid layer, thereby, extending longevity of resin-dentin bonds [24,25].

In our study, we examined the effect of microleakage on tooth samples treated with SDF within the dentinal surface with the use of different restorative materials. We found that TPH (control) had the lowest amount of microleakage when compared with the other combination of treatments. It is also important to note that the application of SDF with GI and composite resin on carious teeth showed comparatively less microleakage than other groups, indicating the benefit of using this method if the SDF application is clinically indicated. It is worth noting that the dental etchant (35% phosphoric acid solution) commonly used in dentistry is a gel that may be responsible for causing SDF to contaminate the walls and surface of the cavity preparation. It is plausible that the application of acid etch following SDF treatment causes the precipitation of SDF, and this precipitation allows SDF particles to travel along with the viscous etchant gel, contaminating various tooth surfaces, affecting bonding surfaces, and having an overall negative impact. Lutgen et al. [26] demonstrated that the negative effects of SDF on bonding strongly correlated with the application protocol followed. The bond strength was improved after the rinsing of the SDF application compared to non-rinsing groups [26].

Therefore, removal of the superficial layer of SDF application on dentin aided in recovered bond strength values similar to those observed for controls for multi-step adhesive protocol standards, specifically the standard etch bonding technique used in our study and Clear fill SE bond [26]. This is a key finding as it broadens the number of potential applications of SDF, suggesting clinically acceptable bonding strengths as controls. The current study also aided in the use of SDF at the University of Tennessee College of Dentistry to help develop protocols as SDF usage has grown dramatically in the past four years to arrest advanced and rampant caries cases. The current usage of SDF includes patients with psychological and medical issues which prevent them from receiving conventional dental restorative treatments. Additionally, patients with uncontrolled caries secondary to salivary dysfunction that may be due to pathological or chemical/medication use are also treated with SDF.

The protocol of the SDF application includes isolating the area with 2 x 2 gauze or cotton rolls, followed by cleaning and drying the field receiving the application. Petroleum jelly can be applied to the adjacent soft tissue (careful not to contaminate the area to be treated). The technique proceeds by applying the solution from the ampule (Advantage Arrest) with a micro brush and wiping off the excess with a 2 x 2 gauze, air drying for 60 seconds, and then wiping off the solution with gauze and rinsing the area with water thoroughly. The application may be repeated in 1 week if necessary. Re-applying SDF two to three times a year yields the best long-term results. The area may be restored in the future with conventional techniques. This protocol has been quite successful with pediatric patients, patients in the advanced stages of dementia, and cancer patients receiving chemotherapy or radiation treatments. Once SDF treatment has been initiated, every effort is made to follow the clinical progress of the individual patient in order to steer them to conventional restorative treatment or continuation of the SDF treatment at recall visits.

Our study has provided valuable information regarding the methodology and modifications needed to improve current SDF usage protocols and enable clinicians to properly desensitize and disinfectant teeth in conjunction with a bonding material to aid in improved clinical outcomes. The patients who have benefited from the application of SDF include advanced dementia patients with recurrent decay at the margins of existing crowns for whom conventional restorative treatment would be difficult, and those patients, especially children with extensive caries, who have little or no access to regular dental care.

Conclusion

In our study, the control restorative material TPH produced the most aesthetically pleasing restorations, and the addition of SDF resulted in discoloration and a less favorable aesthetic ranking. Male and female clinicians participated in the aesthetic ranking and resulted in different rankings, but the differences were not statistically significant. In the microleakage component of this study, TPH alone produced the least microleakage, and the addition of SDF to TPH in non-carious teeth produced a statistically significant increase in microleakage. The addition of SDF to glass ionomer and TPH on carious teeth did not produce a statistically significant increase in microleakage, illustrating the benefit of SDF application when indicated by caries. The sequence of SDF application is important and rinsing of applied SDF from dentin before acid etching has been proven to increase the bond strength of the restoration. SDF has valuable applications in restorative dentistry, including pediatric and geriatric care. As the protocols for SDF application continue to be studied, the potential for its use increases.

Acknowledgments: University of Tennessee Alumni Endowment Fund and Dr. James C. Ragain Jr. for access to CRCD Test.

References

1. Bruce A Dye, Gina Thornton-Evans TJI, Xianfen Li (2015) Dental Caries and Sealant Prevalence in Children and Adolescents in the United States, 2011–2012, in NCHS Data Brief 191: 1-18.
2. Frencken JE (2017) Global epidemiology of dental caries and severe periodontitis- A comprehensive review. Journal of Clinical Periodontology 44(S18): S94-S105.
3. Mohammadi (2015) Fluoride Varnish Effect on Preventing Dental Caries in a Sample of 3-6 Years Old Children. Journal of International Oral Health: JIOH 7(1): 30-35.

How to cite this article: Kiana R, Nechama C, Colette S, William C, Ammaar H A. Restorative Outlook on Mixed Application Techniques Involving Silver Diamine Fluoride. Adv Dent & Oral Health. 2021; 14(2): 555884. DOI: 10.19080/ADOH.2021.14.555884

4. Horst JA (2016) UCSF Protocol for Caries Arrest Using Silver Diamine Fluoride: Rationale, Indications, and Consent. Journal of the California Dental Association 44(1): 16-28.
5. Thompson V (2008) Treatment of deep carious lesions by complete excavation or partial removal: A critical review. Journal of the American Dental Association (1939) 139(6): 705-712.
6. Ricketts DN (2006) Complete or ultraconservative removal of decayed tissue in unfilled teeth. Cochrane Database Syst Rev 2006(3): Cd003808.
7. Knight GM (2009) Inability to form a biofilm of Streptococcus mutans on silver fluoride- and potassium iodide-treated demineralized dentin. Quintessence Int 40(2): 155-161.
8. Zhao IS (2017) Mechanisms of silver diamine fluoride on arresting caries: a literature review. Int Dent J 68(2): 67-76.
9. Bendit J (2017) Silver Diamine Fluoride: The newest tool in your caries management toolkit. PennWell Publications CA# 03-4527-15217.
10. Rodrigues (2015) Mechanical Strength and Wear of Dental Glass-Ionomer and Resin Composites Affected by Porosity and Chemical Composition. Journal of Bio- and Tribo-Corrosion 1(3): 24.
11. Quock RL (2012) Effect of silver diamine fluoride on microtensile bond strength to dentin. Oper Dent 37(6): 610-616.
12. Yamaga M, Koide T, Hieda T (1993) Adhesiveness of glass ionomer cement containing tannin-fluoride preparation (HY agent) to dentin--an evaluation of adding various ratios of HY agent and combination with application diammine silver fluoride. Dent Mater J 12(1): 36-44.
13. Soeno K (2001) Effect of desensitizers on bond strength of adhesive luting agents to dentin. J Oral Rehabil 28(12): 1122-1128.
14. Knight GM, McIntyre JM, Mulyani (2006) The effect of silver fluoride and potassium iodide on the bond strength of auto cure glass ionomer cement to dentine. Aust Dent J 51(1): 42-45.
15. Gladys S (1999) Evaluation of esthetic parameters of resin-modified glass-ionomer materials and a polyacid-modified resin composite in Class V cervical lesions. Quintessence Int 30(9): 607-614.
16. Horst JA (2018) Silver Fluoride as a Treatment for Dental Caries. Advances in dental research 29(1): 135-140.
17. Darabi F (2014) Translucency and masking ability of various composite resins at different thicknesses. Journal of dentistry (Shiraz, Iran) 15(3): 117-122.
18. Zhao IS (2017) Effect of Silver Diamine Fluoride and Potassium Iodide Treatment on Secondary Caries Prevention and Tooth Discolouration in Cervical Glass Ionomer Cement Restoration. International journal of molecular sciences 18(2): 340.
19. Magno MB (2019) Aesthetic perception, acceptability and satisfaction in the treatment of caries lesions with silver diamine fluoride: A scoping review. Int J Paediatr Dent 29(3): 257-266.
20. Dye BA (2015) Dental caries and sealant prevalence in children and adolescents in the United States, 2011-2012. NCHS Data Brief 191: 1-8.
21. Sarvas E, Jeffrey M, Karp (2016) Silver diamine fluoride arrests untreated dental caries but has drawbacks. American Academy of Pediatrics (AAP New).
22. Sharafeddin F (2013) Microleakage of Posterior Composite Restorations with Fiber Inserts Using Two Adhesives after ging. Journal of dentistry (Shiraz, Iran) 14(3): 90-95.
23. Perez-Hernandez J (2018) Effect of silver diamine fluoride on adhesion and microleakage of a pit and fissure sealant to tooth enamel: in vitro trial. Eur Arch Paediatr Dent 19(6): 411-416.
24. Gou YP (2018) Quaternary ammonium silane-based antibacterial and anti-proteolytic cavity cleanser. Dent Mater 34(12): 1814-1827.
25. Gou YP (2018) Optimizing resin-dentin bond stability using a bioactive adhesive with concomitant antibacterial properties and anti-proteolytic activities. Acta Biomater 75: 171-182.
26. Lutgen P, Chan D, Sadr A (2018) Effects of silver diammine fluoride on bond strength of adhesives to sound dentin. Dent Mater J 37(6): 1003-1009.

DOI: 10.19080/ADOH.2021.14.555884

How to cite this article: Kiana R, Nechama C, Colette S, William C, Ammaar H A. Restorative Outlook on Mixed Application Techniques Involving Silver Diamine Fluoride. Adv Dent & Oral Health. 2021; 14(2): 555884. DOI: 10.19080/ADOH.2021.14.555884