

# Bichectomy or Bichatectomy - A Small and Simple Intraoral Surgical Procedure with Great Facial Results

**Eber Luis de Lima Stevao\***

*Orthognathic Surgery Institute of Curitiba, Brazil*

**Submission:** October 05, 2015; **Published:** November 14, 2015

**\*Corresponding author:** Eber Luis de Lima Stevao, Oral and Maxillofacial surgeon, PhD in OMS, Fellowship training at Baylor University Medical Center, Dallas - Texas, EUA, Clinical Director of the Orthognathic Surgery Institute of Curitiba, Curitiba - Parana, Brazil, Email: eberstevao@yahoo.com

## Abstract

Bichectomy is a simple and very safe surgical procedure indicated for patient with a rounded and wide face which can be performed as an outpatient surgery under intravenous or oral sedation. The result is a thinner lower third of the face.

**Keywords:** Bichectomy; Bichatectomy; Adipose tissue; Cheek surgery; Bichat's fat pad

## Introduction

Marie François Xavier Bichat was a French anatomist, physician, and biologist, which lived in 1771 through 1802 who first described an encapsulated mass of fat in the cheek on the outer side of the buccinator muscle [1]. The buccal adipose body of the cheeks has six extensions spread over the masseteric, superficial temporal, deep temporal, pterygomandibular, sphenopalatine and inferior orbital areas [2]. Bichectomy or Bichatectomy, a more correct term, or simply cheek surgery in a lay term is a surgical procedure that removes a structure known as Bichat fat pad, which in some cases makes a person to look like overweight and not in harmony with the facial contour/balance laterolaterally. A patient candidate for this type of surgery normally has an excessive facial roundness, full aspect which give him/her a heavy-looking face. Bichatectomy can be performed if a differentiation of the middle third of the face is desired giving a marked further cheekbones (zygoma) expression. This aesthetic surgical procedure gives the face a more youthful appearance and it is possible to achieve a thinner face appearance, more esthetic within a harmonious balance. Bichatectomy is a very safe procedure which can be performed in the office as outpatient with the patient under intravenous or sedation. It is important the surgeon fully explain the patient different issues concerning this surgery such as what really the procedure can and cannot treat, inherent risks, costs, and other related factors like bleeding and possible cheek infection. The right candidate for cheek fat removal is a patient who has more than eighteen years of age, physically fit, non-smokers, realistic about the goals and results that can be achieved with the surgery, and positive attitude. The benefits of buccal fat removal can be

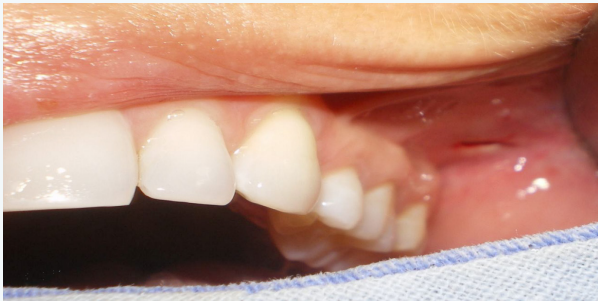but not limited to:

- 1) Thinner cheeks
- 2) Improvement of facial appearance,
- 3) Cheeks more defined resulting in more prominent zygomatic bones,
- 4) Gaining an increase in self-esteem
- 5) Feeling more confidence.

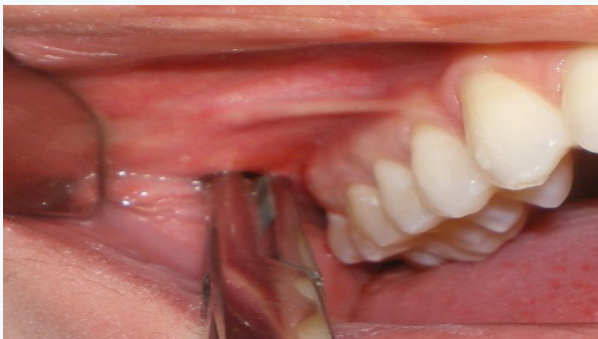## Bichatectomy technique short description

Access to the Bichat's fat pad is done by a small incision (Figure 1), no more than 5 mm in length, at the soft tissue situated in the most inferior aspect of the zygomatic buttress having the careful to visualize the Stensen's duct orifice and a blunt dissection is achieved with a thin scissors or hemostat into the fat pocket which is located under the zygomatic arch extending to the most anterior aspect of the cheek (Figure 2A-2B). It is very important to preserve its very thin fascial envelope. With a long and thin hemostat locking plier deep inserted in the area a portion of the fat is pinched and gently pulled out (Figure 3). Little by little the whole fat pad is pulled out (Figure 4) with the help of another hemostat until the pedicle is visualized. At this point the pedicle can be cut and the fat pad loose free (Figure 5). Additionally a small metallic suction tip can be inserted into the area (pocket) to clean out any part of fat left behind. When the fat pad fascia is not ruptured it is possible to remove the whole structure in just one piece as shown in the photo below (Figure 6). Most of the times a simple and single stitched is performed to close the incision and the surgery is completed (Figure 7). The whole procedure takes around fifteen to twenty five minutes from

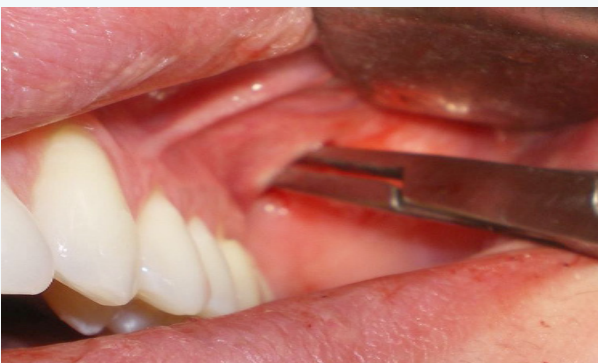local anesthesia to suture. There are no formal indications for sending the specimens for histo pathological examination unless any different aspect of the structure is macroscopically observed as far as color and/or caliber of blood vessels is concerned. Pain medication is regularly prescribed along with intense bilateral cryotherapy in the areas during 24 to 48 hours. Prophylactic antibiotic can be prescribed and a five to seven days antibiotic prescription is a good option when the fat pad is not removed in just one piece. Very rare problems or accidents during the surgical procedure can occur and are resumed as lesion to the Stensen's duct and its aperture and injury to the buccal branch of the Facial nerve resulting in Stensen's duct injuries, which are manifested with sialoceles or salivary fistulas [3], and temporary numbness of the long buccal nerve. The results can effectively be seen after four to six months when the soft tissue edema is definitely resorbed away (Figures 8A-8C, Figures 9A-9C).



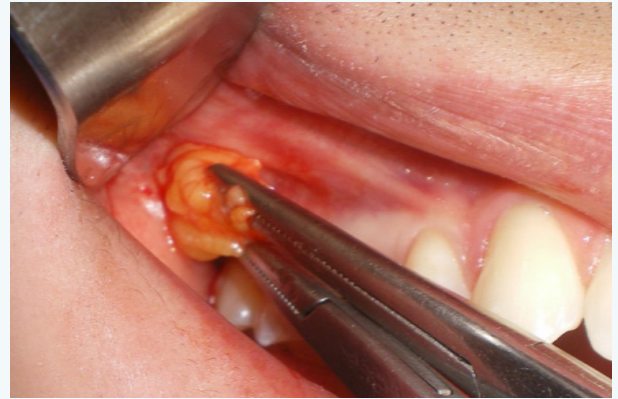**Figure 1:** Small incision performed at the base of the zygomatic buttress.



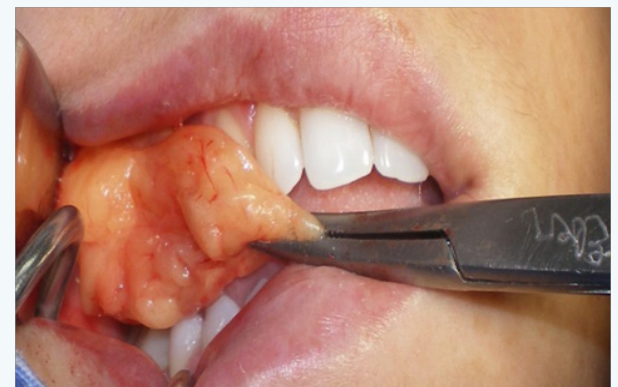**Figure 2A:** Hemostat lightly opened inserted through the incision into left and right side.



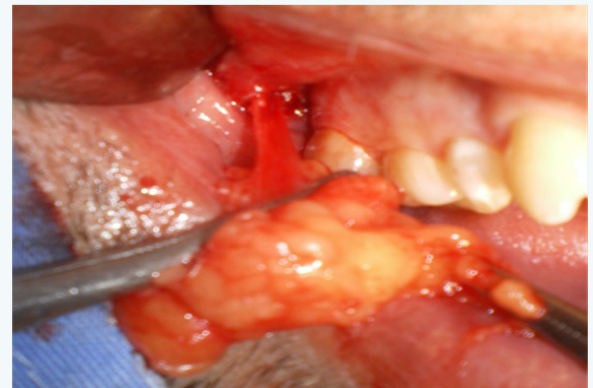**Figure 2B:** Hemostat lightly opened inserted through the incision into left and right side.



**Figure 3:** Small hemostats are intercalated during the fat pad traction.



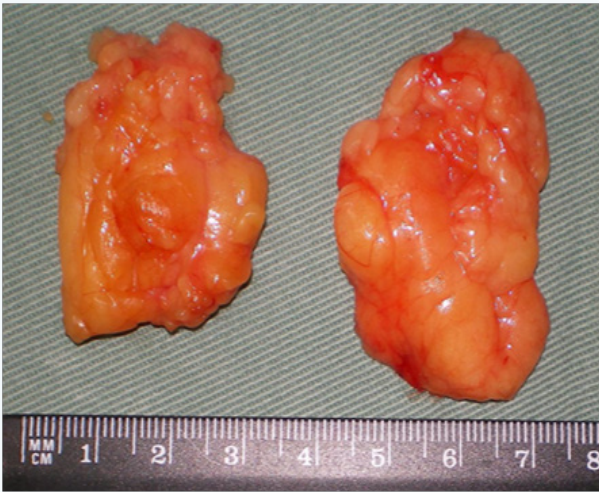**Figure 4:** The whole fat pad is pulled out and exposed to the oral cavity.



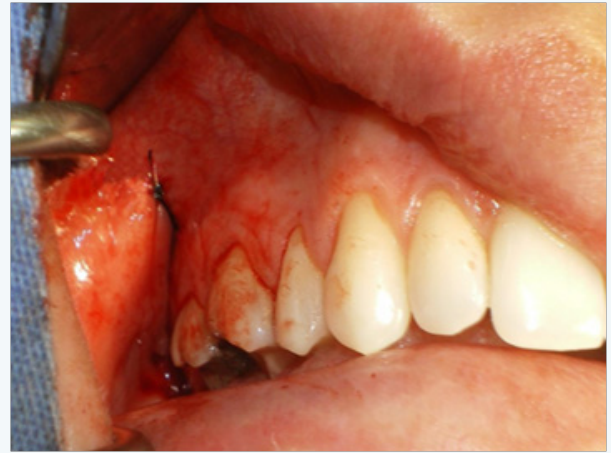**Figure 5:** The fat pad pedicle under intense traction to be scised.

### Considerations

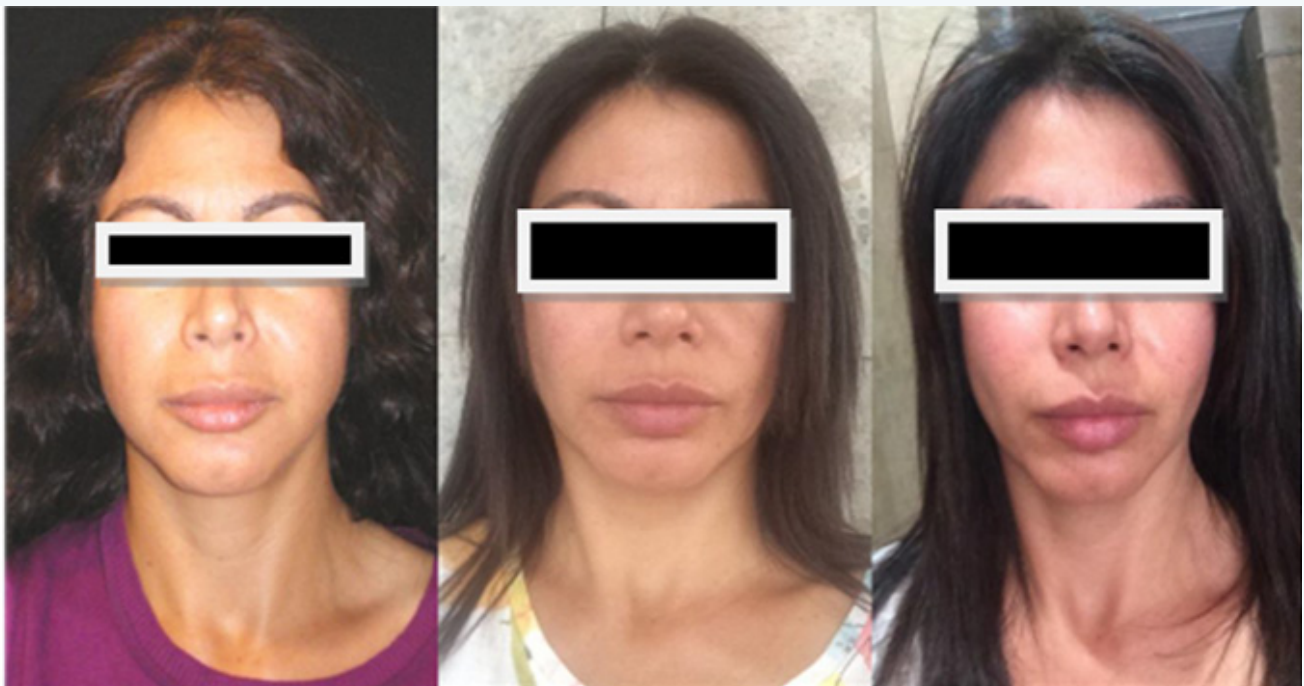Cheek fat pads augment the lower third of the face. It is known that facial widening can be a result from overweight and genetic predisposition. The Bichatectomy offers a great solution to those patients who want to slim the size of their cheeks at the same time contouring the face on an outpatient surgery basis in the office with a low cost.



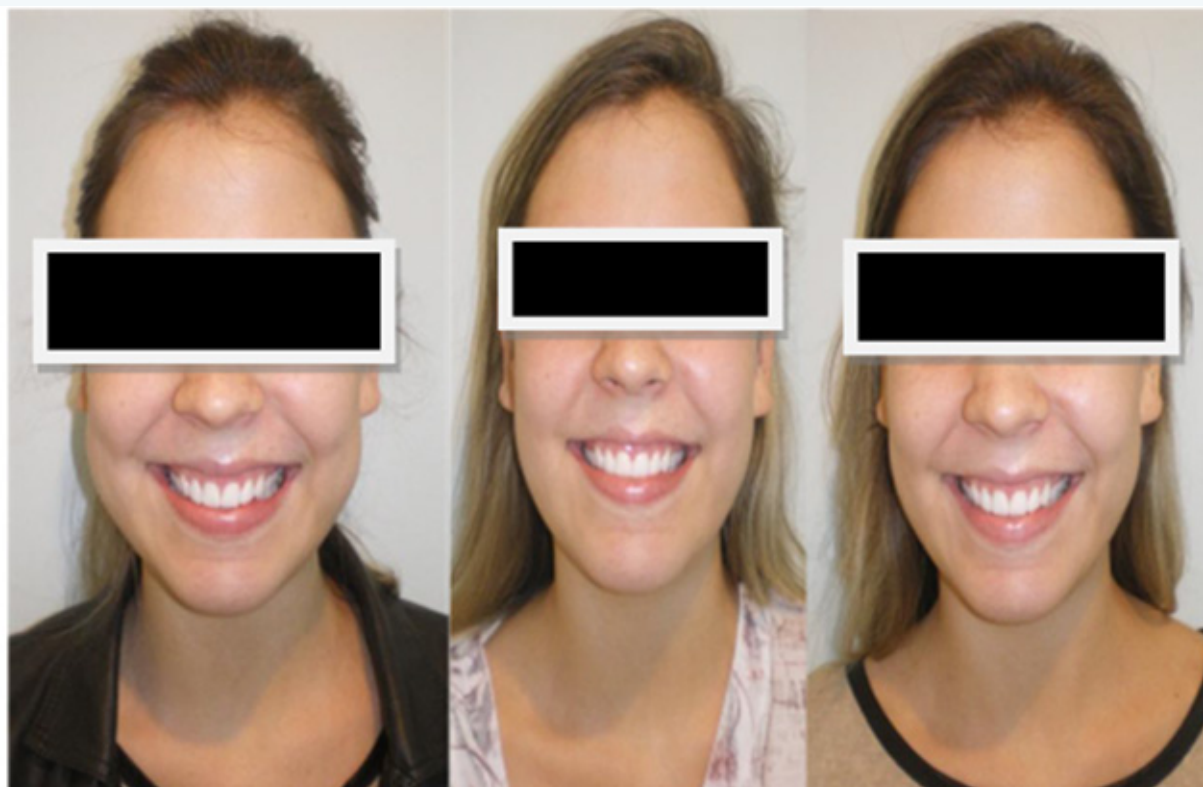
**Figure 6:** The right and left fat pads exposed after being entirely removed as one piece structure.



**Figure 7:** A single suture is normally enough to close the incision.



**Figure 8A-8C:** The first picture shows a female patient before Bichectomy. The second picture shows two months follow-up. The last picture is four months post-operatively.



**Figure 9A-9C:** The first picture shows a female patient before Bichectomy smiling. The second picture shows one month follow-up. The last picture is five months post-operatively.

## References

1. <http://medical-dictionary.thefreedictionary.com/Bichat+fat+pad>.
2. Kahn JL, Sick H, Laude M, Koritké JG (1988) The buccal adipose body (Bichat's fat-pad). Morphological study. *Acta Anat* 132(1): 41-47.
3. Kopeć T, Wierzbicka M, Szyfter W (2013) Stensen's duct injuries: the role of sialendoscopy and adjuvant botulinum toxin injection. *Wideochir Inne Tech Maloinwazyjne* 8(2): 112-116.