

## Treatment of Fracture Clavicle by Ilizarov Technique

**Bari MM\*, Islam Shahidul, Shetu NH and Mahfuzer RM**

*Chief consultant, Bari-Ilizarov Orthopaedic Centre, Visiting and Honored Professor of ilizarov center Kurgan Russia*

**Submission: October 21, 2015; Published: October 27, 2015**

**\*Corresponding author:** Md Mofakhkharul Bari, MM Bari, Bari-Ilizarov Orthopaedic Centre, 72 Satmasjid Road Nizams Shankar Plaza Dhanmondi, Dhaka, Bangladesh, Telephone: +8801819211595; Email: bari.ilizarov31@gmail.com

### Abstract

We treated 26 clavicle fractures with a mean age of 40 years (15-55) years with mini Ilizarov fixation from January 1999 to January 2014 at Bari-Ilizarov Orthopaedic Centre and NITOR, Dhaka. Out of 22 patients 20 were male and 6 female. We are presenting here the use of mini Ilizarov apparatus for fracture clavicle. Among the complications 2 pin track infections were observed from which all responded positively to local care. The mini Ilizarov apparatus and technique represents a useful method for the successful healing of fracture clavicle.

**Keywords:** Clavicle, Mini Ilizarov Apparatus

### Introduction

Despite being a common fracture, representing 5-10% of all orthopaedic fractures [1], evidence of optional treatment of displaced clavicle fracture is still ambiguous [2]. Primary surgical treatment of displaced mid shaft clavicle fractures, with locking plate osteosynthesis as the preferred method, to result in good functionally high union rate and few complications [3-5] the nonunion rate is reported as high as 20% and close to 30% of all patients are reported to have symptomatic mal union(3). Structurally the clavicle is a spongy bone since its internal lumen is filled with cellular bone and there is no intramedullary canal. Our research has shown that an axial wire in the spongy bone provides sufficient rigidity for the fixation of splinters, even in cases of minimum axial compression.

### Materials and Methods

For the last 16 years (1999-2014) 26 cases of fracture clavicle were operated by the Ilizarov technique. The follow up period was 1-15 years. Male predominated with an average age of 40 yrs. as demonstrated in (Table 1).

#### Ilizarov external fixation of the clavicle

The recommendation for the method by Russian Ilizarov Research centre forms the basis of the fixation method requirements that are generally applicable.

- 1) At least two 2 mm console wires at an angle to each other are inserted in each bone fragment.
- 2) The points of wire insertion must be near the epiphysis of the clavicle.

- 3) The point of insertion must be on the upper surface of the clavicle.
- 4) The direction of wire insertion must coincide with the anatomic axis of the bone fragments.
- 5) In diaphyseal fractures, wires are inserted through both cortical layers.
- 6) The minimum distance between the skin surface and the external support must be 1.5-2 cm.

#### Indications for Ilizarov external fixation are

- 1) Fractures of various severity levels.
- 2) Fracture dislocation and
- 3) Dislocation of acromial end of clavicle.

#### The Ilizarov parts are

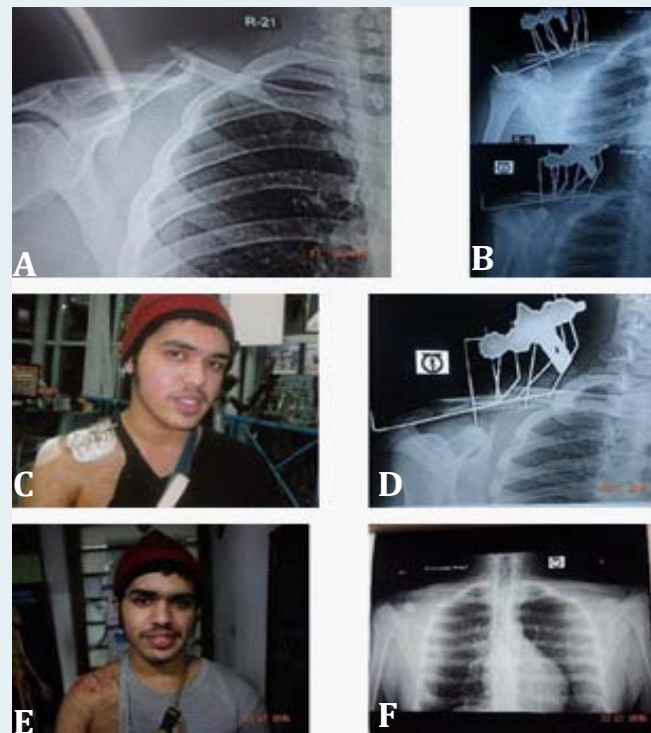
- 1) 2 plates
- 2) Posts
- 3) Wire fixators
- 4) Connecting rods

### Surgical Procedure

The patient is administered regional anaesthesia placed un-

**Table 1:** Shows sex incidence.

| Sex    | Quantity | Percentage |
|--------|----------|------------|
| Male   | 20       | 77%        |
| Female | 06       | 23%        |



**Figure 1:** (A) 12 day's old comminuted fracture right clavicle.  
 (B) Radiograph of right clavicle after surgery (2<sup>nd</sup> post-op).  
 (C) Mini Ilizarov apparatus on the right clavicle of 23 yrs. old male.  
 (D) Radiograph with union of the fragments after 6 weeks.  
 (E) Clinical appearance of the patient after removal of the mini Ilizarov apparatus.  
 (F) Final radiograph of the right clavicle with full consolidation after 2 months follow up.

der sedation. The operation is performed with the patient supine, with a cushion along (C7-D7) and his or her forearm behind the back. The patients head is turned in the direction opposite to the injured clavicle but it should not be thrown back, the side of the face must be level with the anterior aspect of the chest. First, the wire insertion points are determined from radiographs in two projections. Radio-opaque markers are placed 2 cm from the joint surfaces of the acromial to the anatomic axis of the bone fragments. Injection needles are also placed to mark the anterior and posterior boundaries of the bone fragments at the insertion levels of the transosseous elements.

Mounting of the device starts from the medial support. The wires are manually fixed in the extreme holes of the connection plate and using wire fixators, so that their guiding ends only slightly protrude over the edge of the plate. The plate is applied onto the skin and the wire directed towards the sternal extremity of the clavicle and manually inserted to the bone. One should again make sure that the wire is located from the upper aspect of the clavicle and in the centre of the bone diameter. A reference point is marked on the wire showing the depth of its insertion and indicating the depth at which it will exit from the lower cortical plate. The bar is then moved away from the skin by 1.5-2 cm. The second wire is inserted until it touches the bone and after making sure that it is located in the centre of the clavicle diam-

eter, the first wire is fixed rigidly to the support. After the second wire is inserted and fixed, the support is similarly mounted on the peripheral fragment [6,7].

### Postoperative Protocol

In the operating rooms, after the axial compression wires have been tensioned, the skin around the wires is examined. A pressure bandage in the form of a sling is applied to the area of the axial compression wire insertion. During first 3-4 days, dressing is changed daily, then as required as but not less frequently than every 7-10 days. X-ray can be done after 10 days. In fracture clavicle, the structure is generally dismantled within 5-6 weeks.

### Case Illustration

Osteogenesis was achieved in all the 26 patients. Two patients had a pin track infection which was treated by local care with antibiotics. There were no incidents of neurovascular complications.

### Discussion

The mini Ilizarov method for the management of fracture clavicle has many advantages. However, several technical problems can arise if the details of the technique are not allowed precisely. The inexperienced surgeons usually fail to carry out of the

whole technique. For successful tissue genesis one must follow the rules and processes of Ilizarov technique. It is evident that regeneration of the bone can be obtained safely. The research and review of existing literature revealed few publications for fracture clavicle treated non operatively. The factors that could influence development of clavicular nonunion included, presence of fracture comminution, complete fracture displacement, increased age, and fracture shortening. Fracture displacement following a clavicle fracture was reported to predict pain and dysfunction in two studies both with follow up of more than two [8,9] years. In this study fracture displacement was formed to be a predictor for nonunion in all but one publication reporting on this subject [10-14]. Shortening of the clavicle following a mid-shaft clavicle fracture has been found to be associated with inferior clinical outcome [15].

A publication by Nowak et al. [8] recognized fracture comminution as a significant risk factor for pain, strength reduction and cosmetic defects after a clavicle fracture but not as a predictor for nonunion [8]. We found two cohort studies of large sample size reporting comminution to be a predictor for nonunion in mid shaft fracture [10,11]. All existing randomized studies comparing surgical and non surgical treatment of displaced mid shaft fractures favour surgical treatment based on slightly better functional outcome.

## Conclusion

Fracture clavicle with displacement can be easily treated by mini Ilizarov apparatus. Displacement seems to be the most likely factor that is responsible for nonunion. Treating all clavicle fractures with displacement surgically would inevitably lead to over treatment, which is why future studies need to focus on mini Ilizarov surgery and those who would not. Introducing one k-wire though the fragments and fixing the fragments externally by mini Ilizarov apparatus gives excellent result and better outcome.

## Reference

1. Robinson C M (1998) Fractures of the clavicle in the adult. Epidemiology and classification. *J Bone Joint Surg Br* 80(3): 479-484.
2. Khan LA, Bramdmpcl Tj, Scott C, Robinson CM (2009) Fractures of the clavicle. *J Bone Joint Surg Am* 91(2): 447-460.
3. Ban I, Branner U, Holck K, Krashennnikoff M, Troelsen A (2012) Clavicle fractures may be conservatively treated with acceptable results-a systemic review. *Don Med J* 59(7): A4457.
4. Liu GD, Tong SL, Ou S, Zhou LS, Fei J, et al. (2013) Operative versus non-operative treatment for clavicle: a metaanalysis. *Int Orthop* 37(8): 1495-1500.
5. Fridberg, M, Ban, I, Issa, Z, Krashennnikoff M, Troelsen A (2013) Locking plate osteosynthesis of clavicle fractures: complication and reoperation rates in one hundred and five consecutive cases. *Int Orthop* 37(4): 689-692.
6. G.A. (1992) Ilizarov Transosseous Osteosynthesis Theoretical and clavicle aspects of the regeneration and growth of tissue springer-Verlog, 450-452.
7. Bari MM (2013) A color atlas of limb lengthening surgical reconstruction and deformity correction by Ilizarov technique. pp-75.
8. Nowak J, Holgersson M, Larsson S (2004) Can be predict long term sequelae after fractures of the clavicle based on initial findings. A prospective study with nine to ten years of follow-up. *J Shoulder Elbow Surg* 13(5): 479-486.
9. Eskola A, Vainionpaa S, Myllynen P, Patiala H, Rokkanen P (1986) Outcome of clavicular fracture in 89 patients. *Arch Orthop Trauma Surg* 105(6): 337-338.
10. Murray IR, Foster CJ, Eros A, Robinson CM (2013) Risk factors for nonunion after non operative treatment of displaced midshaft fracture of the clavicle. *J Bone Joint Surg Am* 95(13): 1153-1158.
11. Robinson CM, Court- Brown CM, McQueen MM, Wakefield AE (2004) Estimating the risk of nonunion following non-operative treatment of a clavicular fracture. *J Bone Joint Surg Am* 86-A(7): 1359-1365.
12. Kirmani SJ, Pillai SK, Madegowda BR, Shahane SA (2009) Vertical fragment in adult midshaft clavicle fractures: an indicato for surgical intervention. *Orthopaedics* 32(10): 9-14.
13. Wick M, Muller EJ, Kollig E, Muhr G (2001) Midshaft fractures of the clavicle with a shortening of more than 2 cm predispose to nonunion. *Arch Orthop Trauma Surg* 121(4): 207-211.
14. Hill JM, McGuire MH, Crosby LA (1997) Closed treatment of displaced middle third fractures of the clavicle gives poor results. *J Bone Joint Surg Br* 79(4): 537-539.
15. McKee, Pedersen EM, Jones C, Stephen DJ, Kreder HJ, et al. (2006) Deficits following non operative treatment of displaced midshaft clavicular fractures. *J Bone Joint Surg Am* 88(1): 35-40.