

Case Report

Volume 6 Issue 3 - February 2019
DOI: 10.19080/JOJUN.2019.06.555690

JOJ uro & nephron

Copyright © All rights are reserved by Ogawa Y

Posttransplant Urine Leakage with Extensive Ureteral Stricture Corrected by Pyelopyelostomy: A challenging case



Ogawa Y^{1*}, Kono Y², Yagi Y², Ishizaka K² and Suzuki H²

¹Department of Urology, Tokyo-West Tokushukai Hospital, Akishima, Tokyo, Japan

²Department of Urology, Musashino Tokushukai Hospital, Nishitokyo, Japan

Submission: January 28, 2019; **Published:** February 11, 2019

***Corresponding author:** Yoshihide Ogawa, Department of Urology, Tokyo-West Tokushukai Hospital, Akishima, Tokyo, Japan

Abstract

Various rescue procedures have been devised to reconstruct a long-segment ureteral stricture with high-volume urinary leakage after kidney transplantation. Secondary pyeloureterostomy is typically employed using the recipient's native ureter, and pyelopyelostomy is infrequently applied for secondary reconstruction. We used the latter method in a secondary transplant recipient whose native ureter was small in diameter and who also had a "frozen pelvis" with marked adhesions and fibrosis as he had survived various complications and multiple surgical procedures, including abscess drainages and colon surgeries. One and a half years have passed since the secondary pyelopyelostomy with a well-functioning graft; therefore, this open surgical repair appears to be the treatment of choice for complicated urinary leakage and failed endourological repair.

Keywords: Transplantation; Urine leakage; Ureter complication; Pyelopyelostomy

Introduction

Ureteric anastomosis in kidney transplantation is rarely complicated by urinary leakage or stricture [1]. The incidence of posttransplant urinary leakage is 3.2-4% [2,3]. Early leakage (up to day 4) and late leakage (up to day 10) are associated with technical causes and ischemic necrosis, respectively [4]. Surgical exploration is indicated in patients who have significant urine leakage with extensive extravasation, who have a large proximal fistula or in those who have no response to maximal decompression [5-7]. To restore the continuity of the ureter, pyeloureterostomy or pyelopyelostomy using the native ureter is the treatment of choice. A systematic review indicates that pyelo-native ureterostomy is the most successful open surgical technique for distal ureteric strictures following renal transplantation [8]. A 58-year-old man survived multiple, challenging surgeries after two kidney transplants and ipsilateral pyelopyelostomy; therefore, the case is reported here with special reference to some technical points and a literature review.

Case Presentation

A 58-year-old man with a history of proteinuria from puberty and a diagnosis of chronic glomerulonephritis had been on peritoneal dialysis for 4 years and experienced peritonitis three times, followed by hemodialysis for 3 and a

half years. He underwent an unrelated renal transplantation in China and, thereafter, visited our hospital for follow-up. He experienced acute rejection, an inguinal hernia incarceration, an intraabdominal abscess, intestinal fistula secondary to intraperitoneal abscess drainage, the creation of a temporary colostomy, antibiotic-induced hepatitis, and cytomegalovirus infection (up to 80 Ag⁺ cells per slide), among other conditions. His transplant kidney failed due to rejection, infection/sepsis, and drug-induced nephrotoxicity; therefore, transplant nephrectomy was necessary. The patient resumed hemodialysis, and again, he experienced colon perforation and underwent colon resection and colorectal anastomosis followed by colostomy closure. He returned to a sound life on regular hemodialysis for one year.

The patient traveled to China again and underwent secondary kidney transplantation in the left iliac fossa. He visited our hospital two weeks later and mentioned that there was significant urine leakage early after surgery. The urine leak was not apparent one month after transplantation, and the ureter stent was removed according to a suggestion made by the former attending doctor in China. Urine leakage from the surgical wound became prominent after ureter stent removal; a transurethral and percutaneous ureteral stent insertion (endoscopic rendezvous procedure) was unsuccessful due to a large fistula and long distal ureter stricture near the ureteroneocystostomy (most likely

caused by necrosis). The condition persisted with a remaining indwelling bladder catheter and cutaneous fistula. A peri-graft infected urinoma expanded gradually and was therefore opened and drained. Pyelonephritis with mild hydronephrosis required a percutaneous nephrostomy (Figure 1). The abscess/urinoma cavity closed naturally with the nephrostomy over a 2-month observation period (Figure 2). The patient wanted to attempt another surgery in order to void naturally, having a full understanding of the high surgical risk and his allergies to multiple antibiotics (cephalosporins, vancomycin, and new quinolones). He elected ureter reconstruction using the ipsilateral native ureter. A left Gibson incision was made to enter the retroperitoneal space, and the transplanted renal pelvis was difficult to identify by ultrasound or X-ray imaging because of a previous abscess cavity and postoperative scarring. A stent was gently inserted through the nephrostomy tract, and the renal pelvis was palpated and identified manually.

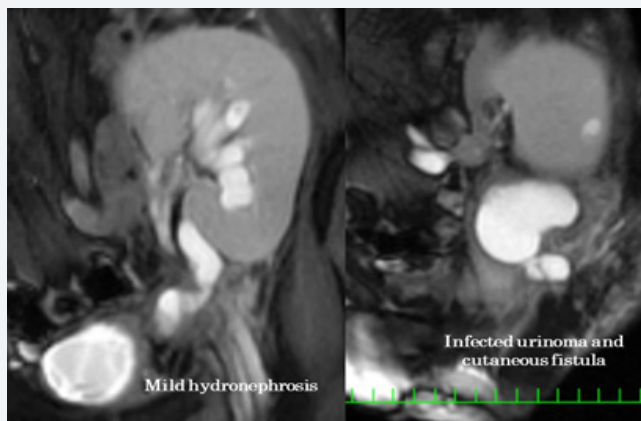


Figure 1: Mild hydroureter and an infected urinoma with a cutaneous fistula prior to nephrostomy and abscess drainage.

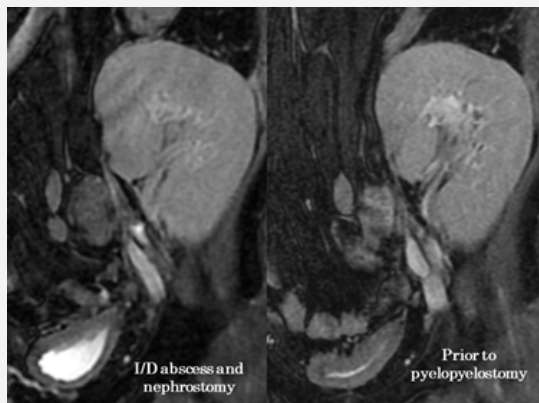


Figure 2: Two months of nephrostomy drainage resulted in reduced hydroureteronephrosis.

The incision was extended slightly upward into the flank; the native ureter was identified to be small in diameter and was dissected up to the pelvis with the gonadal vessels attached. The renal pelvis was divided from the contracted native kidney, after which the pelvis was closed and left as it was without a

nephrectomy. The transplanted renal pelvis was opened and anastomosed to the native renal pelvis with a double J-stent left in place. During the procedure, the rectum was injured inadvertently due to a “frozen pelvis” caused by heavy peri-graft fibrosis, a thick abscess in the cavity wall, and repeated peritonitis. A temporary ileostomy was created and subsequently closed. Then, the nephrostomy tube, ureter stent, and bladder catheter were removed one at a time over a week (Figure 3). One and a half years have passed since the ureter reconstructive procedure, and the patient leads an uneventful life with good renal function (Figure 4).

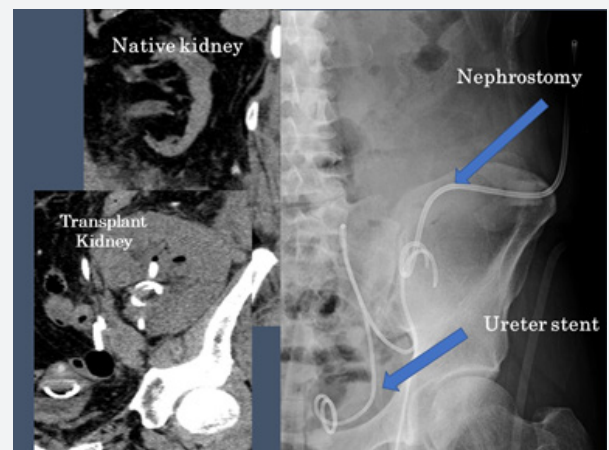


Figure 3: Mild hydronephrosis of the native kidney. A nephrostomy tube, ureter stent, and bladder catheter were placed and subsequently removed.

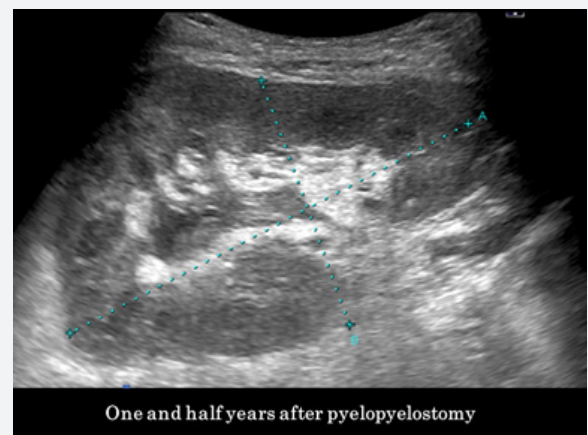


Figure 4: A recent ultrasound shows negligibly mild hydronephrosis without hydroureter or parenchymal atrophy.

Discussion

Urological complications after kidney transplantation are mainly caused by an insufficient blood supply to the harvested ureter, especially in cases of deceased donor kidneys. Excessive dissection of the periureteral connective tissue and excessive manipulation of the so-called “golden triangle” (the site confined by the ureter, kidney, and renal artery) should therefore be avoided during graft recovery. Damage to this triangle leads

to necrosis of the distal ureter in 70% of cases [9,10]. Gonadal vein preservation along the entire specimen during the laparoscopic donor nephrectomy procedure is not necessary to protect the periureteral blood supply to prevent ureteral strictures [11]. Preservation of the gonadal veins does not significantly decrease the frequency of ureteral complications in kidney transplant recipients. Meticulous handling of the ureter during a donor nephrectomy is recommended to prevent further remote complications regardless of the approach to the gonadal veins during nephrectomy [12]. Ipsilateral orchialgia is common (8.52%) in patients who receive a transplant following a left-sided laparoscopic donor nephrectomy [13] if the ureter and gonadal vein are ligated above the level of the iliac vessel bifurcation [14,15]. Preservation of the upper part of the gonadal vein can serve as an excellent landmark for the golden triangle.

Ureteroureterostomy was described by Lawler and associates (1950) with orthotopic transplantation to the renal fossa [16]. Pyeloureterostomy has been described by Kuss (1951) in orthotopic transplantation to the renal fossa [17]. The urinary tract reconstruction technique of a pyeloureterostomy for a heterotopic renal transplant to the iliac fossa was described in detail in 1966 by Leadbetter, who described a simple and rapid technique that left the native ureteral vasculature undisturbed, making stent placement or nephrostomy unnecessary [18]. The advantages include simple and rapid techniques, a richer blood supply, easy transurethral catheterization, and the potential for an orthotopic graft position. Ureteroureteral or pyeloureteral anastomosis does not offer absolute normal excretory/urinary function; according to Kuss, this anarchical urodynamic process leads to a transitory ureterohydronephrosis that lasts for several months and gradually subsides until peristaltic transmission finally improves and normal function is reestablished [19]. Anastomosis of the recipient's ureter or kidney pelvis to the pelvis of the graft may diminish the risk of urinary fistulae (Kuss) [19]. The initial outcomes of this approach in a large series of more than 100 patients were reportedly excellent, with a 7.9% rate of anastomotic leakage [20]. In humans, total destruction of the primary urinary pacemaker would be unlikely unless the kidneys were removed. Division of the ureter, with or without segment resection, and reanastomosis temporarily interfere with peristaltic wave propagation [21]. Butcher and Sleator showed that a period of 28 days is required to resume the passage of electrical activity across an anastomotic site, and a cineradiographic study of a male patient after ureteral anastomosis was in accord with this observation [22].

One inherent advantage of performing a uretero-/pyeloureterostomy is avoiding the need to dissect extensively around the bladder for proper exposure, minimizing the chances of a postoperative hematuria. Minimally invasive approaches to upper urinary tract reconstruction have been described, including robot-assisted approaches, which should be a part of the sur-

gical armamentarium for transplant ureteral strictures requiring surgical revision [23-25]. Another advantage of uretero-/pyeloureterostomy is preservation of the native ureterovesical junction, lessening the risk of vesicoureteral reflux and subsequent reflux-related urinary tract infections. The uretero-/pyeloureterostomy approach also minimizes the need to decompress the bladder postoperatively with a Foley catheter. Another clear benefit of the uretero-/pyeloureterostomy is the ability to perform endourological procedures more easily through the orthotopic ureteral orifice. Uretero-/pyeloureterostomy should be considered a primary option in certain complex situations and secondarily as a salvage procedure when ureteral problems develop after ureteroneocystostomy in patients who undergo renal transplantation [26]. A criticism of uretero-/pyeloureterostomy is the potential for increased risks of anastomotic leakage and potential late obstruction; however, these drawbacks can be overcome, to some extent, by pyelopyelostomy.

Pyelopyelostomy was first described in 1968 by Gil-Vernet and Caralps as a primary method for renal heterotopic transplantation, using the entire functional efferent urinary passage of the recipient in order to avoid ureter complications; therefore, the recipient's excretory tract can preserve intact physiological peristalsis [27]. The authors noticed that the ureteroureteral anastomosis suture was not always watertight and that urine extravasation was a concern [27]. Anatomical preservation of the recipient's entire excretory tract implies the preservation of normal excretory-urinary physiology. Anatomical integrity is tantamount to functional integrity. The authors also used pyelopyelostomy for orthotopic kidney transplantation, usually in the left flank. In this procedure, the native kidney is removed, and the transplanted kidney is revascularized with the native renal artery or the splenic artery and the native renal vein. One advantage of urinary tract reconstruction with the native renal pelvis or ureter over ureteroneocystostomy is the ease with which subsequent retrograde pyelography, stent placement, or ureteroscopy can be accomplished through the normally positioned ureteric orifice [28]. Other advantages of this pyelopyelostomy method include not using a ureter stent or bladder catheter because normal ureteral peristalsis is retained, a nephrostomy is unnecessary, and no reflux is present, whereas native nephrectomy would be necessary according to the authors.

Given the reported success of secondary uretero-/pyeloureterostomy despite these rare challenging clinical situations, the approach might be considered a primary option for establishing urinary continuity following renal transplantation. Intentional ligation of the native ureter during pyeloureterostomy reportedly does not result in increased morbidity [29,30]. Ligation of the proximal native ureter is a variation in the uretero-/pyeloureterostomy technique that has distinct benefits. Long-term follow-up of patients after uretero-/pyeloureterostomy with ligation of the native ureter (without nephrectomy) as a prima-

ry or a secondary approach to urinary diversion has reportedly demonstrated good results [31]. Ligation of the native ureter may result in increased renal pelvic pressure during the first 5 hours after ligation, after which ureteral pressure decreases may not cause loin pain. During this time, patients receive frequent analgesia and are anuric because of end-stage kidney disease. Therefore, ligation of the native ureter without nephrectomy has a low rate of associated morbidity [32,33]. This approach may be a safe option, but there have been some rare cases of urinary tract infection that required native nephrectomy; therefore, a larger series is needed to evaluate risk factors for poor outcomes and complications [34].

Conclusion

Pyelopyelostomy is a promising rescue maneuver that is worth considering in cases of total or partial ureteral necrosis and long-segment ureteral stenosis after renal transplantation [35-38]. The wide anastomosis of the native and donor renal pelvis decreases the risk of subsequent suture line stenosis and fistula formation. The resulting obstructed kidney is not a problem, provided that the pelvi-ureteric blood supply (golden triangle) is preserved, and normal ureteral peristalsis provides satisfactory drainage of urine from the allograft [39].

Conflicts of Interest

The authors declare no conflicts of interest.

References

- Lee HM, Mendez PG (1984) Complications of renal transplantation. In: Complications in Surgery and Trauma edit by Lazar J. Greenfield, JB Lippincott Co. Philadelphia pp: 773-789.
- Englesbe MJ, Dubay DA, Gillespie BW, Moyer AS, Pelletier SJ (2007) Risk factors for urinary complications after renal transplantation. *Am J Transplant* 7(6): 1536-1541.
- Riediger C, Müller MW, Bachmann J, Novotny A, Thorban S et al. (2014) Native ureteropyelostomy: an effective therapy for urinary tract complications following kidney transplantation. *ANZ J Surg* 84(9): 643-648.
- Gunawansa N, Sharma A, Halawa A (2018) Post-transplant urinary leak; the perennial 'Achilles heel' in renal transplant surgery. *Trends in Transplant* 11(1): 1-4.
- Mahdavi Zafarghandi R, Sheikhi Zh (2013) Extensive ureteral stricture in renal transplant recipients: prevalence and impact on graft and patient survival. *Int J Organ Transplant Med* 4(4): 165-171.
- Branchereau J, Karam G (2016) Management of urologic complications of renal transplantation. *Eur Urol Suppl* 15: 408-414.
- Hamouda SM, Sharma A, Halawa A (2018) Urine Leak After Kidney Transplant: A Review of the Literature. *Exp Clin Transplant* 16(1): 90-95.
- Kwong J, Schiefer D, Aboalsamh G, Archambault J, Luke PP, et al. (2016) Optimal management of distal ureteric strictures following renal transplantation: a systematic review. *Transpl Int* 29(5): 579-588.
- Keller H1, Nöldge G, Wilms H, Kirste G (1994) Incidence, diagnosis, and treatment of ureteric stenosis in 1298 renal transplant patients. *Transpl Int* 7(4): 253-257.
- Dinckan A, Aliosmanoglu I, Kocak H, Gunseren F, Mesci A, et al (2013) : Surgical correction of vesico-ureteric reflux for recurrent febrile urinary tract infections after kidney transplantation. *BJUI* 112: E366-E371.
- Kocak B, Baker TB, Koffron AJ, Leventhal JR (2010) Ureteral complications in the era of laparoscopic living donor nephrectomy: do we need to preserve the gonadal vein with the specimen? *J Endourol* 24(2): 247-251.
- Aliasgari M, Shakhssalim N, Dadkhah F, Ghadian A, Moghaddam SM (2008) Donor nephrectomy with and without preservation of gonadal vein while dissecting the ureter. *Urol J* 5(3): 168-172.
- Srivastava A, Kapoor R, Srivastava A, Ansari MS, Singh M, et al. (2013) Orchialgia after laparoscopic renal surgery: a common problem with questionable etiology. Are there any predictors? *World J Urol* 31(5): 1153-1157.
- Sureka SK, Srivastava A, Agarwal S, Srivastava A, An S, et al. (2015) Prevention of Orchialgia After Left-Sided Laparoscopic Donor Nephrectomy-A Prospective Study. *J Endourol* 29(6): 696-699.
- Shirodkar SP, Gorin MA, Sageshima J, Bird VG, Martinez JM, et al. (2011) Technical modification for laparoscopic donor nephrectomy to minimize testicular pain: a complication with significant morbidity. *Am J Transplant* 11(5): 1031-1034.
- Lawler RH, West JW, McNulty PH, Clancy EJ, Murphy RP (1950) Homotransplantation of the kidney in the human. *J Am Med Assoc* 144(10): 844-845.
- Kuss R, Teinturier J, Milliez P (1951) Some attempts at kidney transplantation in man. *Mem Acad Chir (Paris)* 77(22-24): 755-764.
- Leadbetter GW Jr, Monaco AP, Russell PS (1966) A technique for reconstruction of the urinary tract in renal transplantation. *Surg Gynecol Obstet* 123(4): 839-841.
- Kuss R (1966) Renal grafts. *Ann R Coll Surg Engl* 39(3): 174-175.
- Whelchel DJ, Cosimi AB, Young HH (1975) Pyeloureterostomy reconstruction in human renal transplantation. *Ann Surg* 181: 261.
- Weiss RM (1979) Clinical implications of ureteral physiology. *J Urol* 121(4): 401-413.
- Butcher HR, Sleator, W Jr (1956) The effect of ureteral anastomosis upon the conduction of peristaltic waves: an electroureterographic study *J Urol* 75: 650.
- Mufarrij PW, Shah OD, Berger AD (2007) Robotic reconstruction of the upper urinary tract. *J Urol* 178: 2002-2005.
- Bowen DK, Casey JT, Cheng EY (2014) Robotic assisted laparoscopic transplant-to-native ureteroureterostomy in a pediatric patient. *J Pediatr Urol* 10: 1284.e1-1284.e2.
- Gordon ZN, Angell J, Abaza R (2014) Completely intracorporeal robotic renal autotransplantation. *J Urol* 192: 1516-1522.
- Penna FJ, Lorenzo AJ, Farhat WA, Butt H, Koyle MA (2017) Ureteroureterostomy: An Alternative to Ureteroneocystostomy in Select Cases of Pediatric Renal Transplantation. *J Urol* 197(3 Pt 2): 920-924.
- Gil-Vernet JM, Caralps A (1968) Human renal homotransplantation. New surgical technique. *Urol Int* 23(3): 201-223.
- Gil-Vernet JM, Gil-Vernet A, Caralps A, Carretero P, Talbot WR et al. (1989) Orthotopic renal transplant and results in 139 consecutive cases. *J Urol*, 142(2 pt1): 248-252.
- Baquero A, Ginsberg PC, Kaschak D, Raja R, Schneeberg A, et al. (1985) Experience with pyeloureterostomy associated with simple ligation of native ureter without ipsilateral nephrectomy in renal transplantation. *J Urol* 133(3): 386-387.
- Schiff M Jr, Lytton B (1981) Secondary ureteropyelostomy in renal transplant recipients. *J Urol* 126(6): 723-725.

31. Lord RH, Pepera T and Williams G (1991) Ureteroureterostomy and pyeloureterostomy without native nephrectomy in renal transplantation. *Br J Urol* 67(4): 349-351.
32. Gallentine ML, Wright FH Jr (2002) Ligation of the native ureter in renal transplantation. *J Urol* 167(1): 29-30.
33. Khoubehi B, Williams G Re (2003) Ligation of the native ureter in renal transplantation. *J Urol* 169(1): 292.
34. Balagello C, Yamacake K, Falci R, Kanashiro H, Kata R, et al. (2015) Ligation of the native ureter for treatment of urinary fistula in kidney transplantation: Is it safe? *Am J Transplant* 15(suppl 3).
35. Witters G, Baert L (1990) Secondary pyelo-pyelic anastomosis in renal transplant patients. *Urology* 36(2): 183-185.
36. Wagner M, Dieckmann KP, Klän R, Fielder U, Offermann G (1994) Rescue of renal transplants with distal ureteral complications by pyelo-pyelostomy. *J Urol* 151(3): 578-581.
37. Mahdavi R, Gholamrezaie HR (2004) The use of contralateral native pelvis and ureter for total transplant ureteric reconstruction. *BJU Int* 94(3): 439-440.
38. Fernando MH, Jayarajah U, Rubakan D, Fonseka R, Goonewardena S (2018) Complete necrosis of graft ureter following renal transplant in a patient with primary antiphospholipid syndrome: A case report. *Clin Case Rep* 6(7): 1330-1333.
39. Novick AC (1994) Re: Rescue of Renal Transplants with distal ureteral complications by pyelo-pyelostomy. *J Urol* 151(3): 571-581.



This work is licensed under Creative Commons Attribution 4.0 License
DOI: [10.19080/JOJUN.2019.06.555690](https://doi.org/10.19080/JOJUN.2019.06.555690)

Your next submission with Juniper Publishers will reach you the below assets

- Quality Editorial service
- Swift Peer Review
- Reprints availability
- E-prints Service
- Manuscript Podcast for convenient understanding
- Global attainment for your research
- Manuscript accessibility in different formats
(Pdf, E-pub, Full Text, Audio)
- Unceasing customer service

Track the below URL for one-step submission
<https://juniperpublishers.com/online-submission.php>