

**Perspective**

Volume 1 Issue 1 - July 2018

DOI: 10.19080/JOJDC.2018.01.555555

JOJ Dermatol &amp; Cosmet

Copyright © All rights are reserved by Nikolay Serdev

# Total Face Beautification using Serdev Sutures®

**Nikolay Serdev\***

Department of Aesthetic Surgery, New Bulgarian University, Bulgaria

**Submission:** June 20, 2018; **Published:** July 02, 2018**\*Corresponding author:** Nikolay Serdev, Department of Aesthetic Surgery, New Bulgarian University, Bulgaria, Tel: +359 2 952 4652; Email: [serdev@gmail.com](mailto:serdev@gmail.com)**Abstract**

Beautification is the main goal in cosmetic surgery. Both words “cosmetic” in Latin and “aesthetic” in Greek language mean “beautification”. Both terms “cosmetic” and “aesthetic surgery” are wrongly understood as rejuvenation, anti aging, restoration, reconstruction etc., if no beautification is obtained.

It has been found that certain points in a face composition automatically attract the observer’s attention. Many objects and scenes with certain proportions please us automatically.

The scarless transcutaneous “Serdev suture®” Lifts are using a curved elastic needle and a semi-elastic thread, to suture(sew) the mobile SMAS to periosteum. In face these are temporal, medial, lower SMAS and platysma lift, brow lift, cheekbone lift and augmentation, chin enhancement along with modifications and combinations to create beautification in young people and rejuvenation plus beautification in elderly

## Aesthetic Proportions - Main Rules

Aesthetics as a science has been first established in ancient Greece and we found that it is based on aesthetic proportions, angles and volumes. Those aesthetic rules are intransient and are a persistent base for understanding of beauty in all ethnic groups and cultures and are studied in “History of Art”. Most important rules in face are:

### Golden section rule

In face aesthetics, main proportion is the Golden Section Rule -section of the face in 3 equal parts. Ancient Greeks have found that distance between columns has to be equal, to give an aesthetic perspective from different points of view. Leonardo da Vinci investigated the principle that underlies our notions of beauty and harmony and called it the Golden Section. Long before Leonardo, Babylonian, Egyptian, and ancient Greek masters also applied the Golden Section proportion in architecture and art.

Another golden rule is the Golden Ratio of 1.6 (1.6180339887...) that is an important rule in human body and extremity proportions. It is so much well accepted that credit cards have been created corresponding to the golden ratio.

### Aesthetic angles

As face ptosis affects the lateral face, angles should be positioned higher laterally to create the beauty of youth, corresponding to “mask of comedy” in ancient theatre, unlike the “mask of tragedy”. So, the lifting effect on face should be lateral.

## Aesthetic volumes

The “beauty triangle” in face visualizes apparent chin and cheekbones. Higher cheekbones represent youth.

### Profile

Straight profile line is a noble sign.

### Eyes

As people look each other in the eyes when communicating, our first goal is to open and give light to the eyes and never modify them into an “operated-on” appearance.


Considering patient faces we can recognize unaesthetic signs. Following aesthetic rules: proportions, angles and volumes, regardless of age, we can add beauty to any face.

Main goal of Serdev Sutures® is beautification - to create the appropriate aesthetic proportions, volumes and angles in face and body.

The s.c.scarless transcutaneous “Serdev suture®” is uncomplicated in the postoperative period. The idea is, using a curved elastic needle and a semi-elastic thread, to suture(sew) the mobile SMAS to periosteum. In face these are temporal, medial, lower SMAS and platysma lift, brow lift, cheekbone lift and augmentation, chin enhancement, including modifications and combinations to create beautification [1-5].

## Some Clinical Cases

(Figures 1-10)



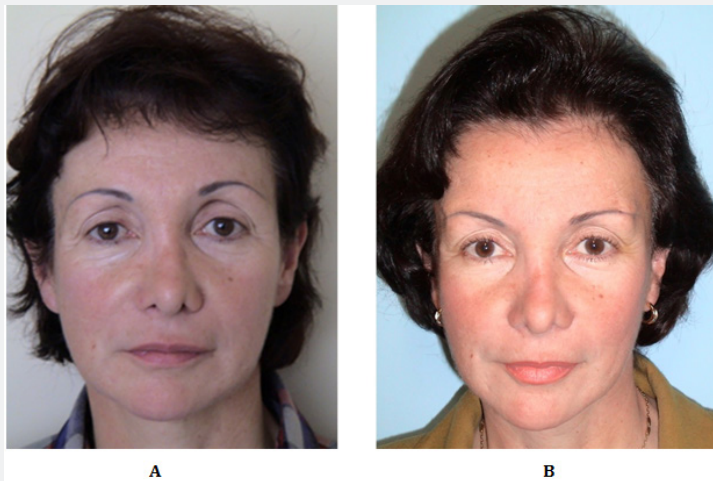
**Figure 1:** The “Golden Section Rule” can advise which parts of the face do not respond to aesthetic proportions. In this case the nasal tip is hanging, shortening the lower third of this face, otherwise young, beautiful and impressing.



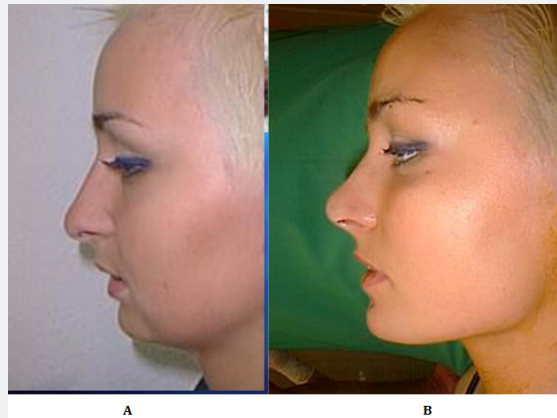**Figure 2A:** Before: Low eyebrows give darkness to the eyes; unaesthetic proportions - the Golden Section Rule of the face is not present; nobleness is not present - retrograde chin, profile line is not straight. Proportion ratio in lower face third is 3:1 instead of 2:1.



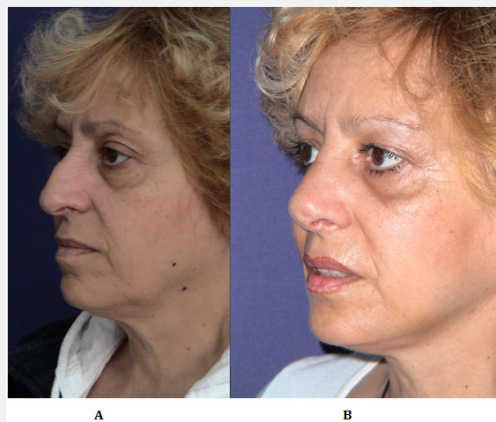
**Figure 2B:** After: Brow lift to open the eyes. Their color is finally visible; Rhinoplasty to create the 3 equal thirds (golden section rule), chin enhancement to create more visible beauty triangle (in man cheekbones should not look “sweet”), straight profile and proper lower face third ration of 2:1. The result is total face beautification. “Playboy” ear pendant serves to demonstrate patient’s self-confidence after surgery.



**Figure 3:** A. Before: Brow ptosis, hollow eyes, gradual facial ptosis, sad appearance. B. After Temporal and Brow Serdev suture lifts: eyes and face are full of light. The color of the eyes is visible. Golden Section Rule is apparent. Lower face is changed from heavy and square into fresh and oval.

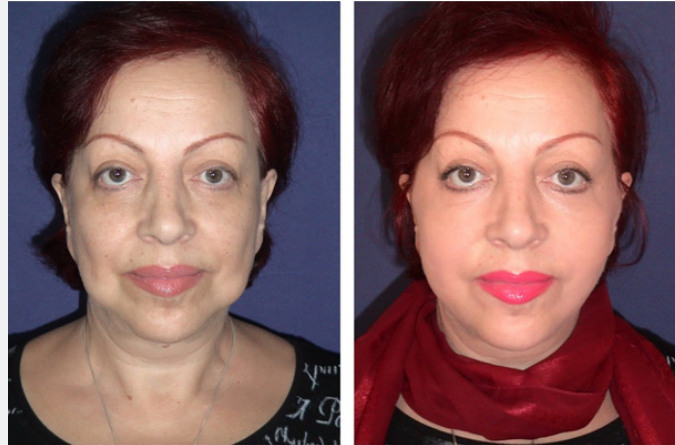

**Figure 4:** A. Before, Nice young lady, but longer nose, and small chin disrupt golden section rule, lower face proportion and the line of straight profile. B. Immediate beautification results in the operating theater after: Temporal lift by suture to lift the facial angles laterally; mini-invasive rhinoplasty (author's T-excision and columella sliding to rotate and project the tip) to obtain the 3 equal parts of the face (golden section rule), and chin enhancement to obtain the straight profile, beauty triangle and proper proportion ratio 2:1 in the lower third of the face. Suturing the chin forward has defined the jaw line. Skin still not cleaned from the Braunol. No operated on appearance immediately after 3 operations (incl. 2 suture lifts).

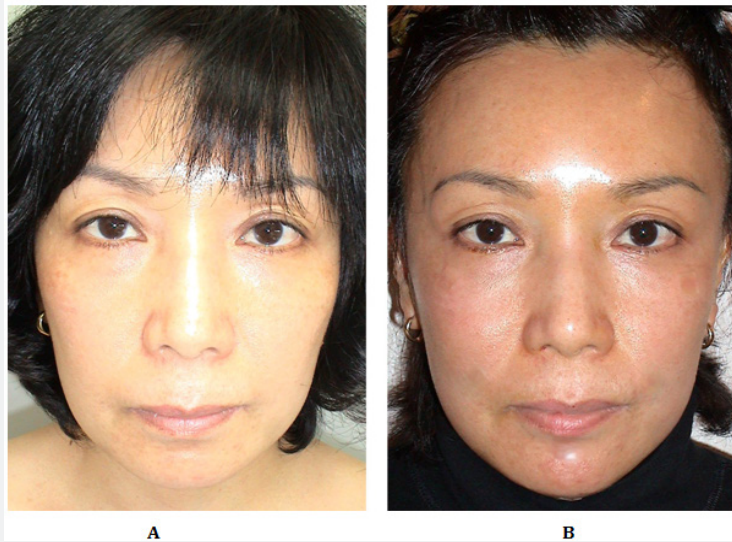


**Figure 5:** A. Before: aging face, disproportions and lack of aesthetics in volumes and angles. B. After scarless closed approach suture Brow, Temporal, Mid face, Lower face and neck lift, Chin enhancement and Rhinoplasty. Fresh appearance after 3 years, fresh, open eye look, sparkling radiation, proper proportions are present, straight profile, angles lifted laterally, volumes, beauty triangle, defined jaw line and cervico-mandibular angle are present. Better skin texture.





**Figure 6:** A. Before: Aging face in a 50 year patient only one year after total classic face lift. B. Beautification (and rejuvenation) after ultrasonic liposculpture of the lower face and mid face lift by suture.



**Figure 7:** A. Disproportional Asian face before: the nose looks longer, emptiness below the eyes, elongated upper lip after silicone injections. B. After Serdev suture medial cheek bone augmentation and chin enhancement and elongation to adapt proper proportions (golden section rule) and beauty triangle. Caucasian type beautification. Lower third of the face in proper proportions, the nose became proportional as 1/3 of the face.

## Conclusion

In a way, cosmetic surgery as a multidisciplinary science is a fine art inherently combining knowledge of design, fashion, sculpture, painting, architecture, and even poetry. Scarless closed approach Serdev SutureR Lifts in combination with other author's techniques (especially in Rhinoplasty) serve to create beauty on the basis of a proper understanding of anatomy, aesthetics as a science, ideal proportions, angles and volumes.

## References

1. Serdev NP (1994) Suture Suspensions for Lifting or Volume Augmentation in Face and Body (English version). *Int J Aesth Cosm* 1(1): 2561-2568.
2. Serdev NP (1994) Temporal SMAS lift without skin excision In: *Lip Augmentation During Mask and SMAS Lift Procedure*, AAARS Annual Meeting, New Orleans, USA.
3. Serdev NP (1999) SMAS Lifting of the Face by Minimal Incisions - the Serdev Technique. *Life Surgery Workshop* sponsored by International Academy of Cosmetic surgery and the Balkan Academy of Cosmetic Surgery, held at the Krilig Clinic in Caracas, Venezuela.
4. Serdev NP (2000) Principles of face beautification, *The 3-rd World Congress of ISAS*, Tokyo.
5. Serdev NP (2003) *Serdev Sutures® Face And Body Lifts And/or Volumizing*, Marllor Editions, Giovanni S in Marignano, Italy.



This work is licensed under Creative Commons Attribution 4.0 License  
DOI: [10.19080/JOJDC.2018.01.555555](https://doi.org/10.19080/JOJDC.2018.01.555555)

**Your next submission with Juniper Publishers  
will reach you the below assets**

- Quality Editorial service
- Swift Peer Review
- Reprints availability
- E-prints Service
- Manuscript Podcast for convenient understanding
- Global attainment for your research
- Manuscript accessibility in different formats  
( Pdf, E-pub, Full Text, Audio)
- Unceasing customer service

**Track the below URL for one-step submission**  
<https://juniperpublishers.com/online-submission.php>