

Autobullectomy: Disease Itself Relieved The Dyspnoea of Patient. Can It Happen?

Jain Shubhra^{1*}, Bunkar Motilal², Takhar Rajendra Prasad² and Arya Savita³

¹S.M.S.Medical College, India

²Dept of Respiratory Medicine, Govt Medical College, India

³Resident Doctor, Govt Medical College, India

Submission: December 16, 2015; **Published:** April 6, 2016

***Corresponding author:** Dr. Rajendra Prasad Takhar, MBBS, MD(Respiratory Medicine), Assistant Professor, Department of Respiratory Medicine, Qtr No 1/4, Medical college campus, Kota (Rajasthan) India, Tel: 919784006021; Email: drrajtakhar@gmail.com

Abstract

Pulmonary bullae occur as insulated abnormalities in approximate normal lung tissue or in the presence of emphysema. The steady expansion of lung bulla is common; however, its mechanism is still unclear, but can impulse life threatening conditions that requires emergent surgical intervention. Spontaneous complete or partial resolution also known as "autobullectomy" of giant pulmonary bullae is very scarce. The pathophysiology of natural purging of giant bulla is not known with inevitability. Here, we are discussing a case of an older female presented with exertional dyspnoea and later diagnosed as large bullous emphysema with secondary infection on the left side. She was managed with antibiotics and inhaled bronchodilators, showed near complete spontaneous resolution of a giant pulmonary bulla with dramatic improvement in severity of dyspnoea, partial pressure of oxygen and arterial blood gas.

Keywords: Emphysematous bulla; Spontaneous resolution; Autobullectomy; Arterial blood gas

Case Report

Introduction

Bullous lung disease is a common presentation in patients with chronic obstructive pulmonary diseases (COPD) and the upshot of the inhalation of combusted tobacco products. Its occurrence in female is very unusual. The development of small multiple bullae are common, but the existence of giant bullae is usually erratic. The giant pulmonary bulla occupies one third of the involved hemi-thorax and characterized by the existence of centrilobular emphysema in the non-bullous lung. Giant bulla slowly increases in size over time and causes compressive atelectasis of lung parenchyma resulting respiratory compromises [1]. Sometime air reabsorbs spontaneously leading to shrinkage and regression of bullae known as autobullectomy [2]. Eleven cases of complete resolution and six cases with partial regression

of giant bullae are recorded in the English literature [3]. Here, we are discussing a case of spontaneous resolution of giant bullae following an infectious episode in an older age female managed symptomatically.

Case history

A 50 years old female with a previous history of twenty pack-years tobacco smoking came to the pulmonary outpatient department with complaints of progressive increase in breathlessness on exertion since one year and modified medical research council (MMRC) grade 2 to grade 3 in last one month along with cough, mucoid expectoration and fever of twenty days duration. She was neither diabetic nor hypertensive. On admission, she was febrile, her pulse rate was 110 beats/minutes, blood pressure 130/90 mm of Hg, respiratory rate 30 breaths / minutes and oxygen saturation was 85% on room air.

Chest auscultation revealed decreased intensity of breath sound in left intraclavicular, suprascapular, upper interscapular and axillary area with rhonchi in other areas on both sides. Her all routine blood investigations were within normal limits including human immunodeficiency virus (HIV) serology except polymorphonuclear ($P > 95\%$) leukocytosis (total leukocytosis count $15000/\text{mm}^3$). Sputum for acid fast bacilli (AFB) was negative and pyogenic culture was sterile. Arterial blood gas (ABG) on room air revealed PaO_2 -45 mm Hg, paCO_2 -40 mm Hg and PH -7.35. Her chest x-ray showed an air fluid level on the left upper zone with a few calcified parenchymal lesion and hyper lucent area in the right upper zone (Figure 1). With the provisional diagnosis of left side lung abscess with chronic obstructive airway disease, she was started oxygen inhalation by nasal prong at 2-4 litre per minute, broad spectrum antibiotic, inhaled bronchodilators and symptomatic treatment.

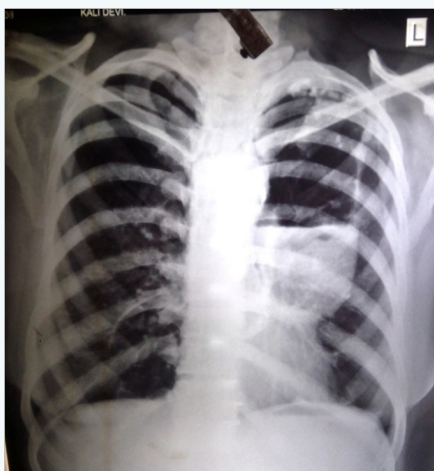

Figure 1: Chest X ray posteroanterior view showing an air fluid level on the left upper zone with a few calcified parenchymal lesion and hyper lucent area in the right upper zone.

After 4-5 days, she didn't show much relief in fever and leukocytosis still persisted. Later, a contrast enhanced chest tomography (CECT) scan revealed emphysematous bullae on the right upper lobe and large air fluid level in left upper lobe suggestive of secondary infection (Figure 2). Fibre optic bronchoscopy was absolutely normal, Bronchoalveolar lavage fluid taken from left upper lobe was sent for AFB stain, gram stain, pyogenic culture sensitivity (Pyogenic C/S), fungal culture and mycobacterium tuberculosis culture by bactec method. AFB stain was negative while the gram stain showed gram negative bacilli and Pyogenic C/S naked klebsiella

pneumoniae with negative other cultures.

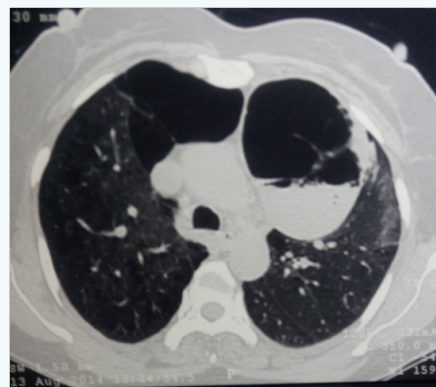


Figure 2: Contrast enhanced computed tomography showing emphysematous bullae on the right upper lobe and large air fluid level in left upper lobe suggestive of secondary infection.

Patient's antibiotics modified according to culture reports along with inhaled bronchodilator and symptomatic treatment. After seven days, her leucocyte count turned to normal. Patient became afebrile and showed clinical improvement in severity of dyspnea and cough. Repeat ABG revealed PaO_2 -85 mm Hg, paCO_2 -38 mm Hg and PH -7.38 on room air. She was discharged on oral antibiotics for next 15 days with bronchodilators and advised to quit smoking. Subsequent chest x-ray after three month showed improvement in view of complete resolution of left lung bulla (Figure 3)

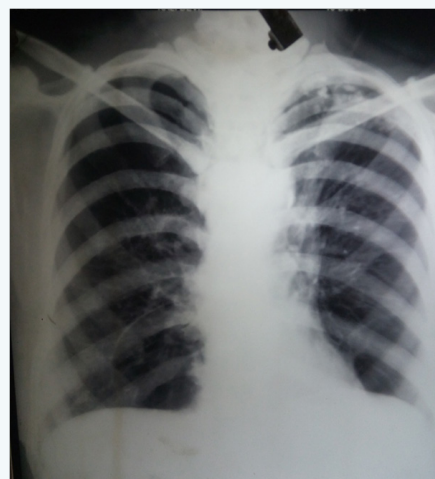


Figure 3: Post treatment chest x-ray after three month showing marked improvement in form of complete resolution of left lung bulla.

Discussion

Pulmonary bullae are pathological air space dilatations > 2 cm in diameter, occurring distally at the terminal bronchioles. Giant pulmonary bullous disease (vanishing

lung syndrome) is characterized by the presence of giant bullae in one or both upper lobes, conquering one-third of the hemi thorax, asymmetrical and squashing nearby normal lung parenchyma. It was first described by Bruke in 1937 [4]. It has male predominance, occurs foremost in smokers with doubtful cause. But in our case it was a female with smoking history of twenty pack year. There are two hypotheses which can explain its occurrence: - protease-anti protease and oxidant-anti oxidant theory. Firstly, it has been assumed that smoking enflame the subcellular inflammatory mediators that letdowns the balance in alveolar proteases and anti-proteases, triggering a chain reaction at the cellular level that sooner or later hints to destruction of alveolar walls. Secondly, oxidative stress results from an imbalance between oxidant and antioxidant proteins causing destruction of lung parenchyma [5].

The gradual expansion of giant bullae is frequently perceived, but the natural history is volatile and pathophysiological mechanism of expansion is still uncertain. Two theories explain its expansion; First the elastic recoil theory by Morgan et al, bullae enlarge due to comparatively grander elastic recoil of adjacent lung parenchyma or in other words, adjoining lung tissue retracts away from the pathologically dilated air space. Second, the ball-valve theory, ball-valve affects proximal airways causing dilation of the airspaces distal to the terminal bronchioles. This check-valve phenomenon increases positive end expiratory pressures within the bullae endorsing a gradual expansion. Increase pressure in the bulla cause compression of lung parenchyma, reduce lung compliance and increase work of breathing; further dead space fraction increases with bullae formation hence gas exchange also hampered [6]. Atelectasis and even mediastinal shift can also occur with giant bulla.

The clinical appearance vary from asymptomatic bullous lung disease to mild cough, dyspnoea and fever to severe lower respiratory infection and influenced by size and infective pathology in bulla, adjacent lung parenchyma and lung compliance that explain the need of mechanical ventilator support [7]. The infected emphysematous bulla (air fluid level) is more symptomatic and warrants an aggressive management strategy. Bhardwaj et al. [8]

explain the formation of air fluid level by two means. Firstly, the reactive collection of air fluid level appears due to peri-bullous pneumonitis and surrounding lung parenchymal inflammation. Secondly, the loss of airway communication between the bulla and larger airways due to inflammatory mucus plugging causing inadequate drainage of sterile fluid subsequent development of air fluid level as seen in our case. The differential includes lung abscess, pulmonary fungal infections such as aspergillosis, pulmonary tuberculosis, cavitary lung cancer - mostly squamous cell lung cancer and emphysema with congestive heart failure.

Management is controversial and should be couturier for each patient based on severity of presentation. Persistent dyspnoea due to giant bulla and development of secondary pneumothorax are most common indications for bullectomy. An infected bulla in itself is not an indication for bullectomy. The pathophysiologic mechanism of spontaneous resolution or regression of giant bullae is not well understood. Usually, spontaneous resolution and regression of the bullae occurs due to an infectious process. It is hypothesized that airway inflammation in connotation with the infected bullae results in closure of the communication between the airway and the bullae. The gases within non-communicating space are now slowly absorbed, resulting loss of volume and eventually collapse of the giant bullae [9]. As this hypothesis explains spontaneous resolution of bulla in our case. Sometimes, tumour, mucous plug or a blood clot can also barricade an already bargained bronchial communication ensuing in a closed space [10]. Smoking cessation also improves the lung function as it decreases airway irritations. The uses of inhaled bronchodilators and anti-inflammatory medication also play a vital role in the resolution or regression of the giant bullae as they decrease in airway inflammation and thereby relieved a check-valve hence improve in severity in dyspnoea as in our case [11].

Conclusion

Spontaneous resolution of giant bullae also known as autobullectomy is an ignorant event and follows an infectious event. The giant bulla closely mimics to lung cancer and lung abscess so all patients should undergo direct visualization of airway by fibre-optic bronchoscopy.

Smoking cessation and intensification of inhaled bronchodilators should be instituted in all patients with giant bullae that may mitigate its progression to ventilator failure. The early suspicion and diagnosis by the treating physician can avert the need for a surgical bullectomy in these patients and decline the morbidity and mortality. Our case is of interest not only because of the rarity with which spontaneous regression has been reported in the literature, but also because it was associated with such dramatic improvements in severity of dyspnoea, partial pressure of oxygen and arterial blood gas.

References

1. Agrawal R, Aggrawal AN (2006) Bullous lung disease or bullous emphysema? *Respir Care* 51(5): 532-534.
2. Chandra D, Rose SR, Carter RB, Musher DM, Hamill R J (2008) Fluid containing emphysematous bullae: A spectrum of illness. *Eur Respir J* 32(2): 303-306.
3. Park HY, Lim SY, Park HK, Park SY, Kim TS et al. (2010) Regression of giant bullous emphysema. *Intern Med* 49(1): 55-57.
4. Karkhanis VS and Joshi JM (2010) Autobullectomy in idiopathic giant bullous lung disease. *Indian J Chest Dis Allied Sci* 52(3): 159-160.
5. Fredenburgh LE, Perrella MA, Mitsialis SA (2007) The role of heme oxygenase-1 in pulmonary disease. *Am J Respir Cell Mol Biol* 36(2): 158-165.
6. Sorheim IC, Johannessen A, Gulsvik A, Bakke PS, Silverman EK, et al. (2010) Gender differences in COPD: are women more susceptible to smoking effects than men? *Thorax* 65(10): 480-485.
7. Vita ML, Van Bouwel EL, Bouhouch A, Hendriks JM, Lauwers PR, et al. (2009) Giant calcified bulla compressing the mediastinum. *Respiration* 77(3): 331-332.
8. Bhardwaj B, Bhardwaj H (2014) Air fluid level in the right lung. *Lung India* 31(2): 179-181.
9. Byrd Jr RP, Roy TM (2014) Spontaneous Partial Resolution of a Giant Pulmonary Bulla. *Austin J Pulm Respir Med* 1(4): 1017.
10. Hiroaki S, Hiroaki I, Moria O, Kiyohisa S (2002) Spontaneous regression of pulmonary bullae. *Australasian Radiol* 46(1): 106-107.
11. Byrd RP Jr, Roy TM (2013) Spontaneous resolution of a giant pulmonary bulla: what is the role of bronchodilator and anti-inflammatory therapy? *Tenn Med* 106(1): 39-42.